

Flexibook



Pocket Atlas of Radiographic Anatomy

Torsten B. Moeller
Emil Reif

3rd edition

clinical sciences

Thieme
Flexibooks

Handy, pocket-sized
learning resources

High-quality radiographs
on the left page complemented
by detailed schematics
on the right



Thieme

Pocket Atlas of Radiographic Anatomy

Torsten B. Moeller, MD

Department of Radiology

Caritas Hospital

Dillingen, Germany

Emil Reif, MD

Department of Radiology

Caritas Hospital

Dillingen, Germany

3rd edition

257 illustrations

Georg Thieme Verlag
Stuttgart · New York

Library of Congress Cataloging-in-Publication Data is available from the publisher.

Translated by John Grossman, Schrepkow, Germany

This book is an authorized translation of the 3rd German edition published and copyrighted 2006 by Georg Thieme Verlag, Stuttgart, Germany. Title of the German edition: Taschenatlas der Röntgenanatomie.

Important note: Medicine is an ever-changing science undergoing continual development. Research and clinical experience are continually expanding our knowledge, in particular our knowledge of proper treatment and drug therapy. Insofar as this book mentions any dosage or application, readers may rest assured that the authors, editors, and publishers have made every effort to ensure that such references are in accordance with **the state of knowledge at the time of production of the book.**

Nevertheless, this does not involve, imply, or express any guarantee or responsibility on the part of the publishers in respect to any dosage instructions and forms of applications stated in the book. **Every user is requested to examine carefully** the manufacturers' leaflets accompanying each drug and to check, if necessary in consultation with a physician or specialist, whether the dosage schedules mentioned therein or the contraindications stated by the manufacturers differ from the statements made in the present book. Such examination is particularly important with drugs that are either rarely used or have been newly released on the market. Every dosage schedule or every form of application used is entirely at the user's own risk and responsibility. The authors and publishers request every user to report to the publishers any discrepancies or inaccuracies noticed. If errors in this work are found after publication, errata will be posted at www.thieme.com on the product description page.

Some of the product names, patents, and registered designs referred to in this book are in fact registered trademarks or proprietary names even though specific reference to this fact is not always made in the text. Therefore, the appearance of a name without designation as proprietary is not to be construed as a representation by the publisher that it is in the public domain.

This book, including all parts thereof, is legally protected by copyright. Any use, exploitation, or commercialization outside the narrow limits set by copyright legislation, without the publisher's consent, is illegal and liable to prosecution. This applies in particular to photostat reproduction, copying, mimeographing, preparation of microfilms, and electronic data processing and storage.

© 2010 Georg Thieme Verlag,
Rüdigerstrasse 14, 70469 Stuttgart,
Germany
<http://www.thieme.de>
Thieme New York, 333 Seventh Avenue,
New York, NY 10001, USA
<http://www.thieme.com>

Cover design: Thieme Publishing Group
Typesetting by primustype Hurler GmbH,
Notzingen
Printed in China by Everbest Printing Co Ltd,
Hong Kong
ISBN 978-3-13-784203-3 1 2 3 4 5 6

*For my American relatives, Bernie
and Arlene, Bryan, Nancy, Rick and
Bill, Shirley, Mike, Michael, Austin
and Amanda, Audrey, Mike, Kristin
and Katelyn, Claudia, Dale, Bryan
and Jamie, Meghan and Jason*

Despite the availability of digital radiography for over a decade, the process of obtaining and evaluating radiographic images has not changed significantly, nor has the importance of having a good knowledge of the anatomic details seen in conventional radiographs. This book is a case in point. We were very pleased with the wide popularity of the previous editions, which has been an additional incentive to add new material.

The structure of the third edition strictly follows that of *Normal Findings in Radiology* and *Pocket Atlas of Radiographic Positioning*. Our intention in this is to present clearly and concisely each respective chapter of conventional diagnostic radiography, avoiding unnecessary repetition. At the same time, we give the reader the opportunity to examine different aspects of the same material with the same degree of clarity, which may prove important on another occasion. We have employed a consistent style and the same radiographs to structure the material and make it more readily accessible for reading, learning, or reference purposes.

Torsten B. Moeller
Emil Reif

Skeletal Imaging	1	Lateral View of the Lumbar Spine	56
Skull	2	Oblique View of the Lumbar Spine	58
Posterior-Anterior View of the Skull	3	Anterior-Posterior View of the Pelvis	60
Lateral View of the Skull	4	Anterior-Posterior View of the Pelvis in a Child	62
Towne View of the Posterior Skull	6	Inlet View of the Pelvis	64
Waters View of the Nasal Sinuses	8	Guthmann View of the Pelvis	66
Occipitofrontal View of the Nasal Sinuses	10	Iliac Wing View of the Pelvis	68
Posterior-Anterior View of the Orbit ...	12	Obturator View of the Pelvis	70
Rhese View of the Orbit	14	Thirty-degree Anterior Oblique View of the Sacroiliac Joint	72
Maxilla	16	Anterior-Posterior View of the Sacrum	74
Ramus Mandible	18	Lateral View of the Sacrum	76
Clementschietsch View of the Mandible	20	Anterior-Posterior View of the Coccyx	78
Pantomogram of the Jaw and Facial Bones	22	Lateral View of the Coccyx	80
Lateral View of the Nose	24	Upper Extremities	82
Zygomatic Arch	26	Osseous Hemithorax	82
Base of the Skull	28	Anterior-Posterior View of the Sternum	84
Altschul View of the Petrous Ridge	30	Lateral View of the Sternum	86
Schüller View of the Petrous Bone	32	Stress View of Both Shoulders	88
Stenvers View of the Petrous Bone	34	Anterior-Posterior View of the Clavicle	90
Mayer View of the Petrous Bone	36	Oblique View of the Clavicle	92
Lateral View of the Sella Turcica	38	Acromioclavicular Joint	94
Anterior-Posterior View of the Sella Turcica	40	Anterior-Posterior View of the Scapula	96
Spine	42	Lateral View of the Scapula	98
Anterior-Posterior Full-length View of the Spine	42	Trans-scapular “Y” View of the Shoulder	100
Anterior-Posterior View of the Cervical Spine	44	Anterior-Posterior View of the Shoulder	102
Lateral View of the Cervical Spine	46	Anterior-Posterior Abduction View of the Shoulder	104
Oblique View of the Cervical Spine	48	Axial View of the Shoulder	106
Anterior-Posterior View of the Thoracic Spine	50	Tangential View of the Shoulder	108
Lateral View of the Thoracic Spine	52		
Anterior-Posterior View of the Lumbar Spine	54		

Transthoracic View of the Shoulder.....	110	Frik Tunnel View of the Knee	166
Anterior-Posterior View of the Upper Arm	112	Forty-five-degree Internal Rotation View of the Knee	168
Lateral View of the Upper Arm	114	Forty-five-degree External Rotation View of the Knee	170
Anterior-Posterior View of the Elbow	116	Thirty-, Sixty-, and Ninety-degree Views of the Patella	172
Lateral View of the Elbow.....	118	Anterior-Posterior View of the Lower Leg.....	174
Axial View of the Elbow	120	Lateral View of the Lower Leg.....	176
Oblique View of the Radius	122	Anterior-Posterior View of the Ankle.....	178
Anterior-Posterior View of the Forearm	124	Lateral View of the Ankle.....	180
Lateral View of the Forearm	126	Oblique View of the Ankle 1.....	182
Anterior-Posterior View of the Hand	128	Oblique View of the Ankle 2.....	184
Oblique View of the Hand	130	Anterior-Posterior View of the Foot..	186
Anterior-Posterior View of the Wrist	132	Lateral View of the Foot	188
Lateral View of the Wrist	134	Lateral View of the Calcaneus	190
Carpal Tunnel	136	Tangential View of the Calcaneus.....	192
Scaphoid Views	138	Hindfoot in a Standing Patient	194
Special View of the Pisiform	140	Anterior-Posterior View of the Metatarsals	196
Oblique View of the Metacarpals	142	Oblique View of the Metatarsals	198
Finger in Two Planes.....	144	Anterior-Posterior View of the Forefoot	200
Lower Extremities	146	Oblique View of the Forefoot	202
Full-Length Anterior-Posterior Weight-bearing View of the Leg	146	Anterior-Posterior and Lateral Views of the Great Toe	204
Anterior-Posterior View of the Hip....	148	Anatomy of Miscellaneous Plain Films	207
Lauenstein View of the Hip	150	Routine Radiographs	208
Tangential View of the Femoral Head (Schneider I)	152	Posterior-Anterior Chest Radiograph	208
Tangential View of the Femoral Head (Schneider II)	154	Posterior-Anterior Chest Radiograph (Heart and Major Vessels).....	210
Axial View of the Hip	156	Lateral Chest	212
Anterior-Posterior View of the Thigh.....	158	Segments of the Lung	214
Lateral View of the Thigh	160	Anterior Oblique View of the Right Chest	216
Anterior-Posterior View of the Knee.....	162		
Lateral View of the Knee	164		

Anterior Oblique View of the Left Chest.....	218	Arthrography	268
Abdomen with the Patient Standing.....	220	Posterior-Anterior Wrist Arthrogram.....	268
Abdomen with the Patient Supine....	222	Lateral Wrist Arthrogram.....	270
Spot Images	224	Anterior-Posterior Shoulder Arthrogram.....	272
Craniocaudal Mammogram.....	224	Oblique Shoulder Arthrogram.....	274
Mediolateral Mammogram.....	226	Knee Arthrogram.....	276
Anterior-Posterior Spot View of the Trachea.....	228	Ankle Arthrogram.....	278
Lateral Spot View of the Trachea.....	230	Arteriography	280
Tomography	232	Anterior-Posterior Internal Carotid Arteriogram, Arterial Phase.....	280
Anterior-Posterior Tomogram of the Pulmonary Hilum.....	232	Lateral Internal Carotid Arteriogram, Arterial Phase.....	282
Lateral Tomogram of the Right Hilum of the Lung.....	234	Anterior-Posterior Internal Carotid Arteriogram, Venous Phase.....	284
Tomogram of the Sacroiliac Joint.....	236	Lateral Internal Carotid Arteriogram, Venous Phase.....	286
Contrast Studies	239	Anterior-Posterior Vertebral Arteriogram, Arterial Phase.....	288
Gastrointestinal System	240	Lateral Vertebral Arteriogram, Arterial Phase.....	290
Anterior-Posterior View of the Hypopharynx.....	240	Anterior-Posterior Vertebral Arteriogram, Venous Phase.....	292
Lateral View of the Hypopharynx.....	242	Lateral Vertebral Arteriogram, Venous Phase.....	294
Esophagus.....	244	Anterior-Posterior Angiogram of the Cervical Vessels.....	296
Esophagus and Stomach.....	246	Anterior-Posterior Aortic Arch Angiogram.....	298
Stomach.....	248	Pulmonary Arteriogram, Arterial Phase.....	300
Stomach and Duodenum.....	250	Anterior-Posterior Pulmonary Arteriogram, Venous Phase.....	302
Stomach and Small Bowel.....	252	Celiac Trunk Angiogram, Arterial Phase.....	304
Small Bowel.....	254	Celiac Trunk Angiogram, Venous Phase.....	306
Spot Film of the Ileocecal Region.....	256		
Colon.....	258		
Rectum.....	260		
Defecography.....	262		
Intravenous Contrast Studies	264		
Intravenous Urogram.....	264		
Intravenous Cholecystochlolangiogram.....	266		

Superior Mesenteric Arteriogram,
Arterial Phase 308

Superior Mesenteric Arteriogram,
Venous Phase 310

Renal Arteriogram, Arterial Phase 312

Renal Arteriogram, Venous Phase 314

Pelvic Aortic Angiogram..... 316

Lower Extremity Angiogram of
the Thigh..... 318

Lower Extremity Angiogram of the
Knee..... 320

Lower Extremity Angiogram of the
Lower Leg..... 322

Lower Extremity Angiogram of
the Ankle and Foot..... 324

Venography 326

Anterior-Posterior Superior Vena
Cava Venogram..... 326

Anterior-Posterior Inferior Vena
Cava Venogram..... 328

Lateral Inferior Vena Cava
Venogram 330

Upper Extremity Venogram of
the Axilla 332

Upper Extremity Venogram of
the Forearm 334

Lower Extremity Venogram..... 336

Special Studies 339

Special Studies..... 340

Anterior-Posterior Thoracic
Myelogram..... 340

Lateral Thoracic Myelogram 342

Anterior-Posterior Lumbar
Myelogram..... 344

Lateral Lumbar Myelogram..... 346

Oblique Lumbar Myelogram..... 348

Anterior-Posterior Bipedal
Lymphangiogram, Channel Phase 350

Oblique Bipedal Lymphangiogram,
Channel Phase..... 352

Anterior-Posterior Bipedal
Lymphangiogram, Nodal Phase 354

Anterior-Posterior Left
Bronchogram 356

Lateral Left Bronchogram..... 358

Lateral Parotid Sialogram 360

Anterior-Posterior Parotid
Sialogram 362

Hysterosalpingogram..... 364

Galactogram 366

ERCP (Endoscopic Retrograde
Cholangiopancreatography)..... 368

Index..... 371

Skeletal Imaging:
Skull

Skeletal Imaging:
Spine

Skeletal Imaging:
Upper Extremities

Skeletal Imaging:
Lower Extremities

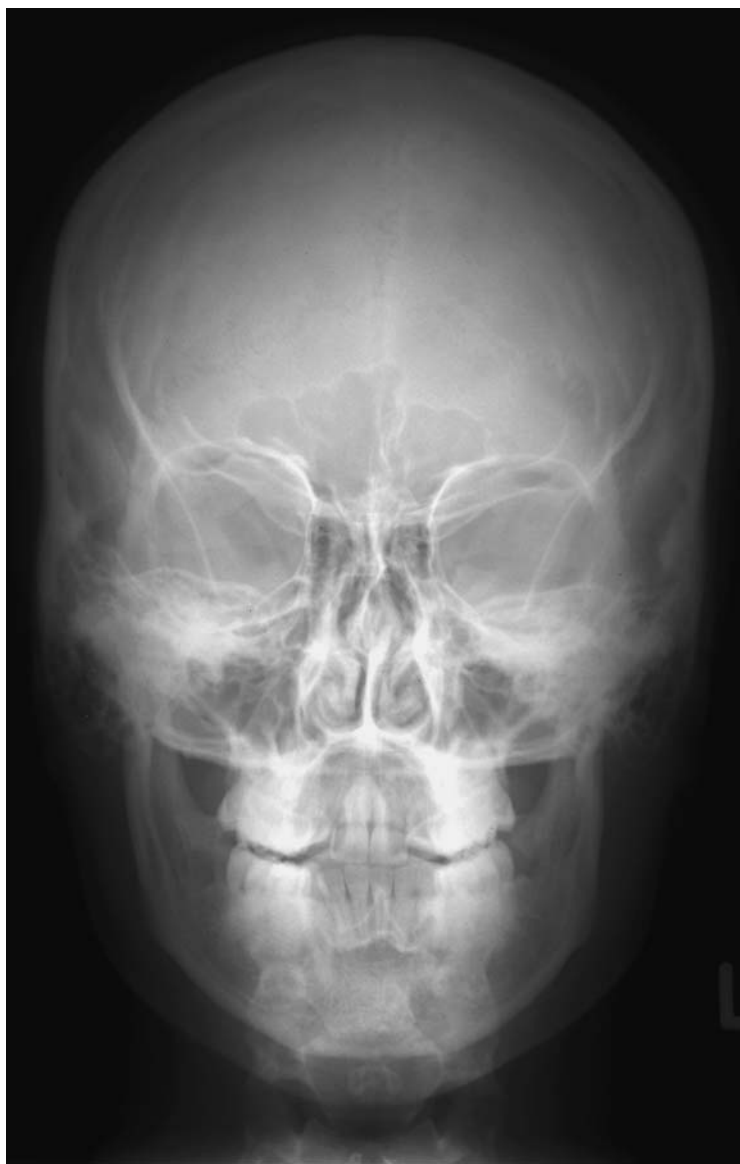Anatomy of Miscellaneous
Plain Films

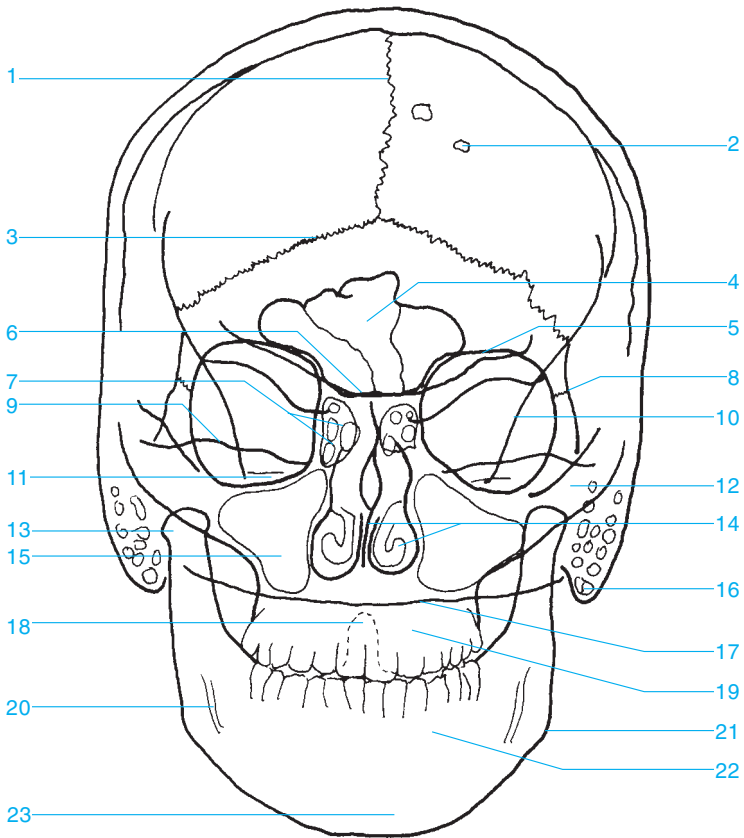
Contrast Studies

Special Studies

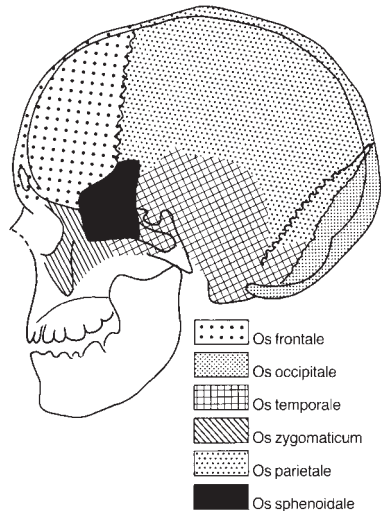
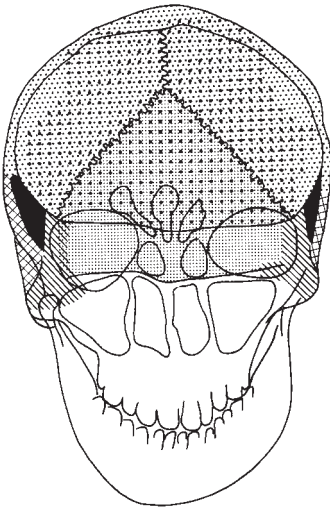
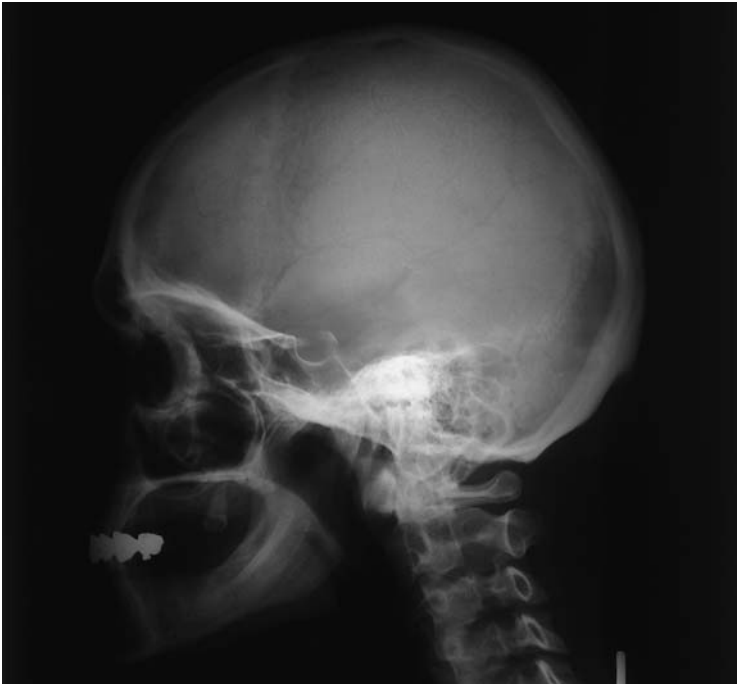Skeletal Imaging







- Skull 2
- Spine 42
- Upper Extremities 82
- Lower Extremities..... 146

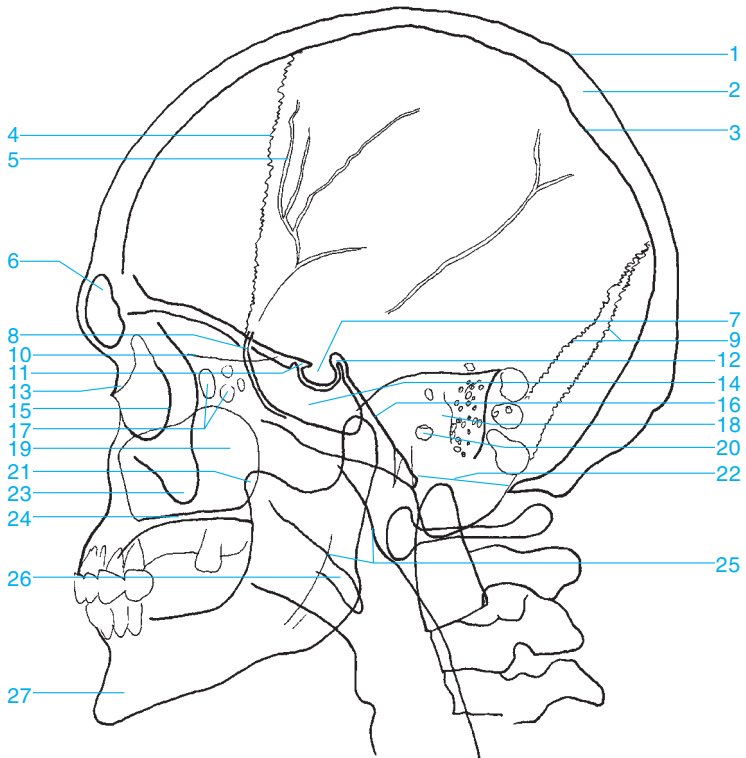




- | | |
|----------------------------|--|
| 1 Sagittal suture | 13 Condylar process of the mandible |
| 2 Pacchionian granulations | 14 Nasal septum and inferior nasal bones |
| 3 Lambdoid suture | 15 Maxillary sinus |
| 4 Frontal sinus | 16 Mastoid process |
| 5 Roof of the orbit | 17 Occiput |
| 6 Sphenoid | 18 Dens of the axis |
| 7 Ethmoid sinus | 19 Maxilla |
| 8 Frontozygomatic suture | 20 Mandibular canal |
| 9 Petrous ridge | 21 Angle of the mandible |
| 10 Innominate line | 22 Mandible |
| 11 Internal auditory canal | 23 Mental protuberance |
| 12 Zygomatic arch | |

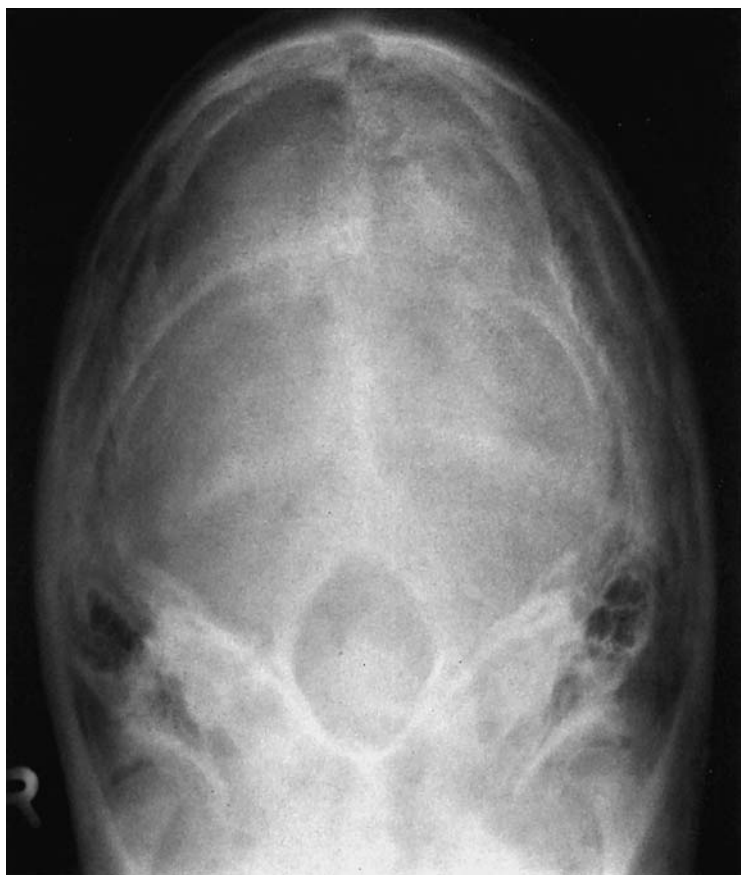

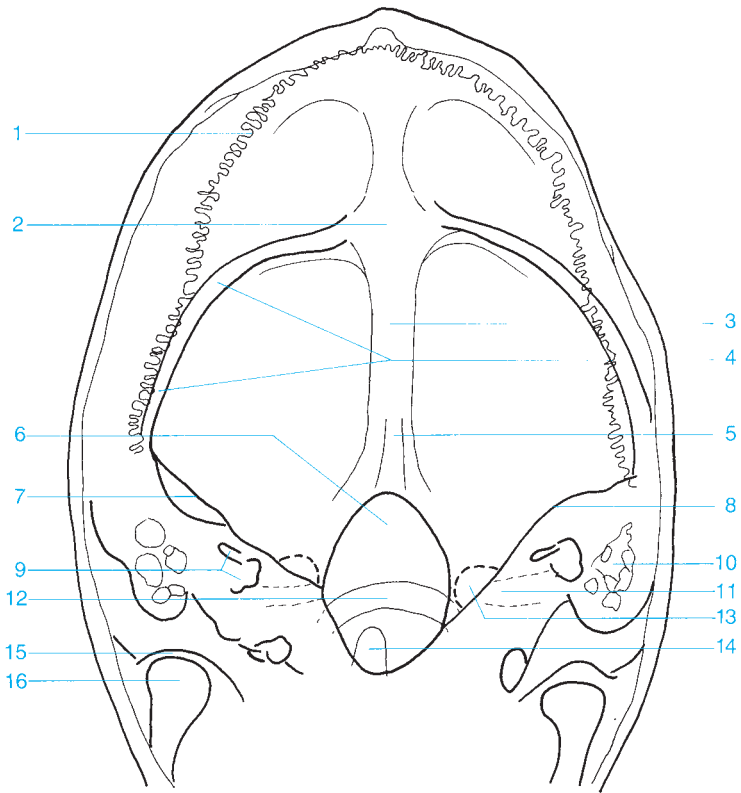
-  Os frontale
-  Os occipitale
-  Os temporale
-  Os zygomaticum
-  Os parietale
-  Os sphenoidale



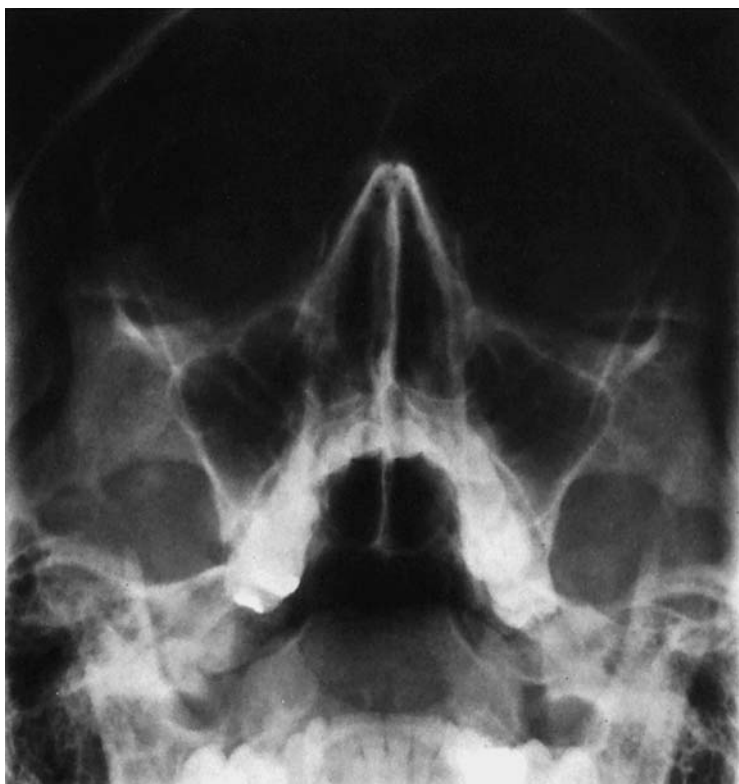- 1 Outer table of the parietal bone
- 2 Diploe
- 3 Inner table of the parietal bone
- 4 Coronal suture
- 5 Groove of the middle meningeal artery
- 6 Frontal sinus
- 7 Pituitary fossa
- 8 Greater wing of the sphenoid
- 9 Lambdoid suture
- 10 Cribriform plate
- 11 Anterior clinoid process
- 12 Posterior clinoid process
- 13 Nasal bone
- 14 Sphenoid sinus


- 15 Zygomatic bone (lateral wall of the orbit)
- 16 Clivus
- 17 Ethmoid sinus
- 18 Petrous portion of the temporal bone
- 19 Maxillary sinus
- 20 Opening of the external auditory canal
- 21 Coronoid process of the mandible
- 22 Foramen magnum
- 23 Zygomatic process
- 24 Hard palate
- 25 Nasopharynx
- 26 Soft palate
- 27 Mandible



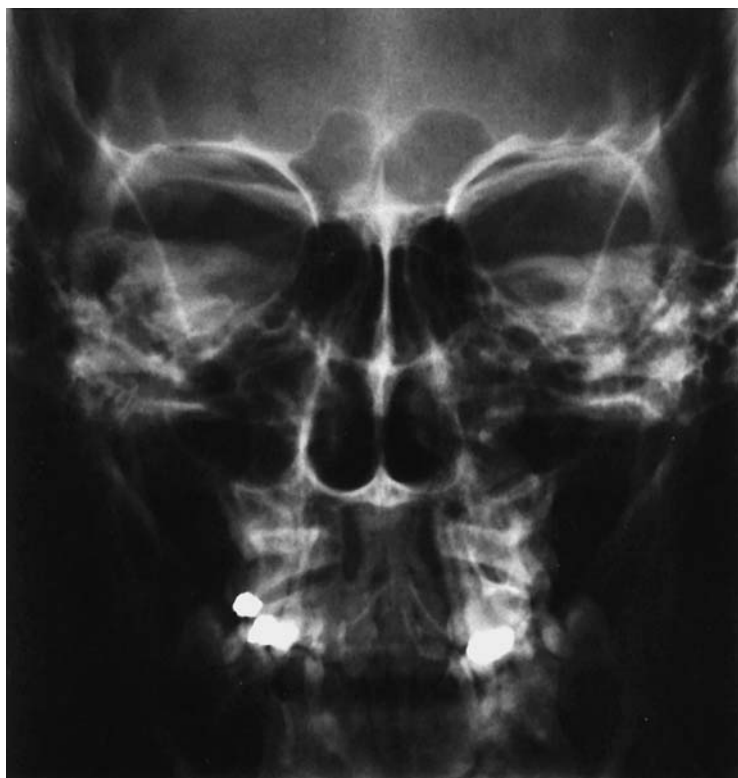

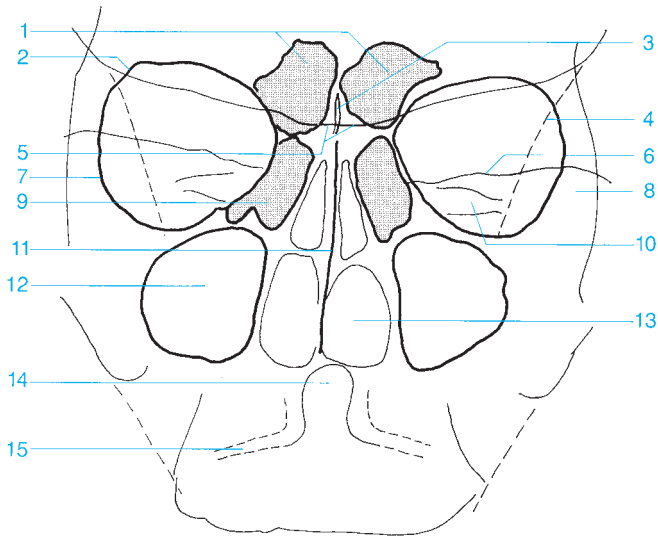
- | | |
|---|--------------------------------|
| 1 Lambdoid suture | 9 Semicircular canals |
| 2 Occipital protuberances (external and internal) | 10 Mastoid air cells |
| 3 Occipital bone | 11 Internal auditory canal |
| 4 Sulcus of the transverse sinus | 12 Posterior arch of the atlas |
| 5 Occipital crest | 13 Jugular foramen |
| 6 Foramen magnum | 14 Dens |
| 7 Petrous bone | 15 Temporomandibular joint |
| 8 Arcuate eminence | 16 Condyle of the mandible |



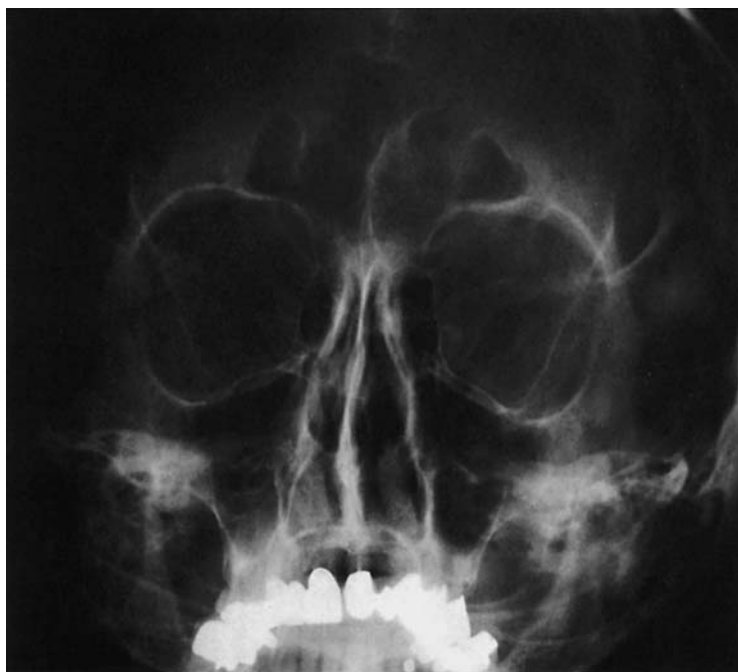

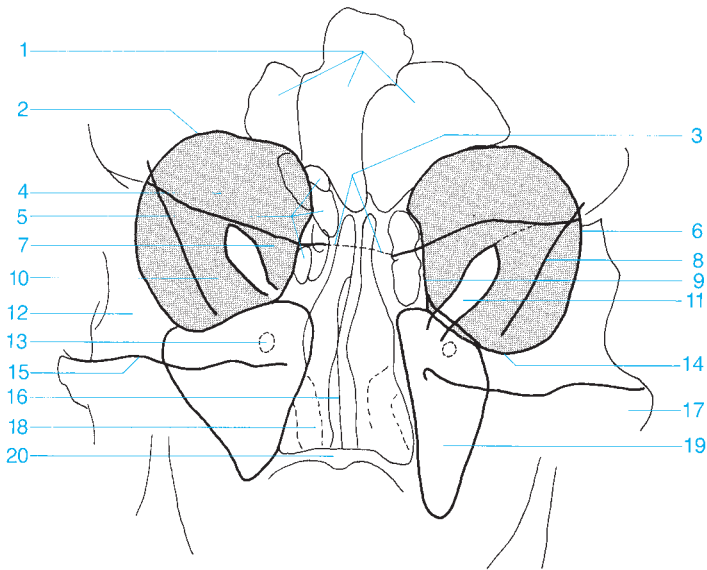
- | | |
|--------------------------------|------------------------------------|
| 1 Frontal sinus | 11 Maxillary sinus |
| 2 Nasal bone | 12 Alveolar recess of the maxilla |
| 3 Anterior ethmoid sinus | 13 Sphenoid sinus |
| 4 Orbit | 14 Foramen ovale |
| 5 Nasal septum | 15 Alveolar process of the maxilla |
| 6 Greater wing of the sphenoid | 16 Condyle of the mandible |
| 7 Infraorbital foramen | 17 Petrous ridge |
| 8 Foramen rotundum | 18 Tongue |
| 9 Posterior ethmoid sinus | 19 Mandible |
| 10 Zygomatic bone | |



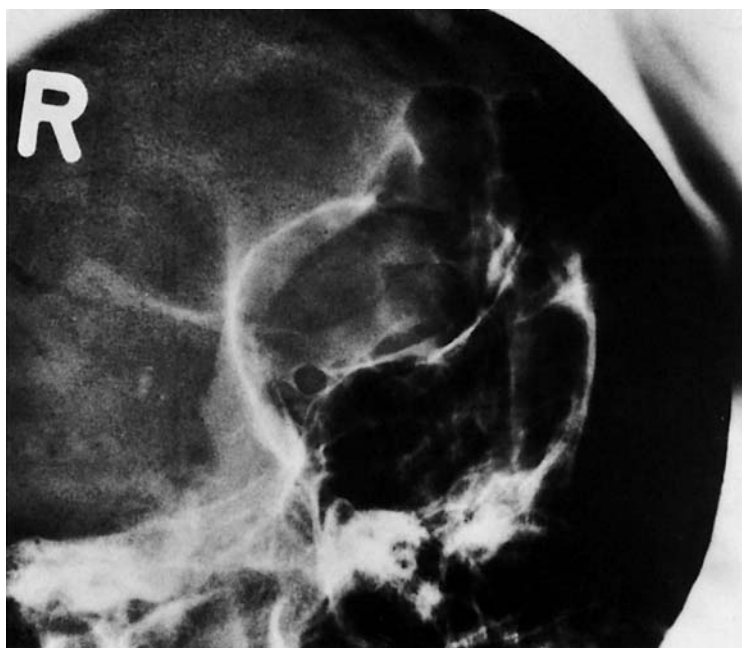

- | | |
|------------------------------------|-----------------------------------|
| 1 Frontal sinus | 9 Anterior ethmoid sinus |
| 2 Roof of the orbit | 10 Internal auditory canal |
| 3 Crista galli | 11 Nasal septum |
| 4 Innominate line | 12 Maxillary sinus |
| 5 Sphenoid | 13 Nasal cavity |
| 6 Petrous ridge | 14 Dens |
| 7 Lateral wall of the orbit | 15 Atlantoaxial joint |
| 8 Zygomatic bone | |



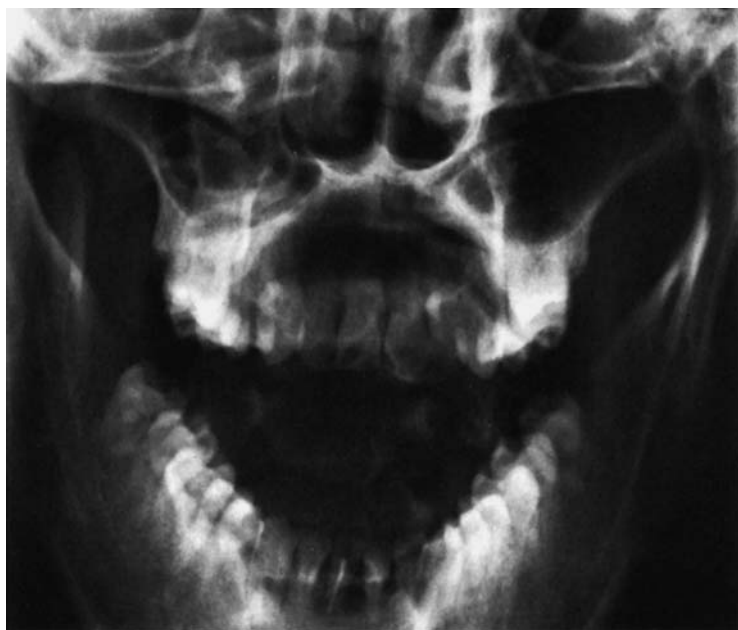

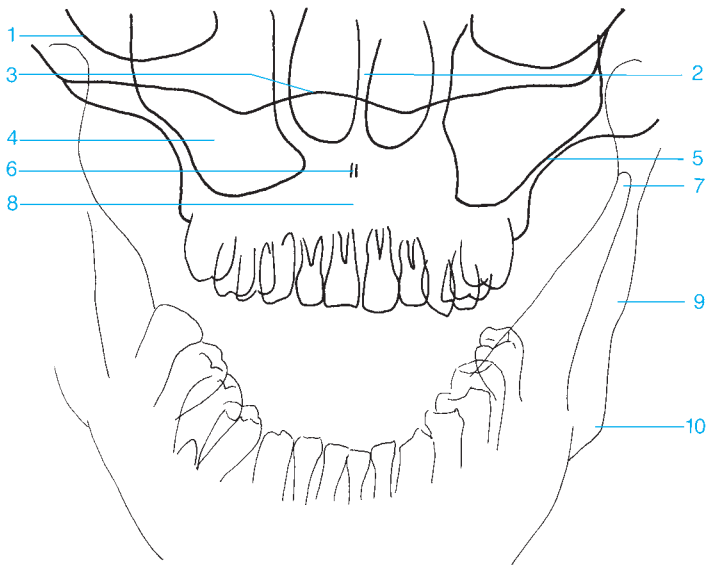
- | | |
|--|---|
| 1 Frontal sinus | 12 Frontal process of the zygomatic bone |
| 2 Roof of the orbit | 13 Foramen rotundum |
| 3 Sphenoid | 14 Floor of the orbit |
| 4 Orbit (gray background) | 15 Petrous ridge |
| 5 Ethmoid sinus | 16 Nasal septum |
| 6 Lateral wall of the orbit | 17 Zygomatic arch |
| 7 Lesser wing of the sphenoid | 18 Inferior turbinate |
| 8 Innominate line | 19 Maxillary sinus |
| 9 Orbital plate | 20 Hard palate |
| 10 Greater wing of the sphenoid | |
| 11 Superior orbital fissure | |





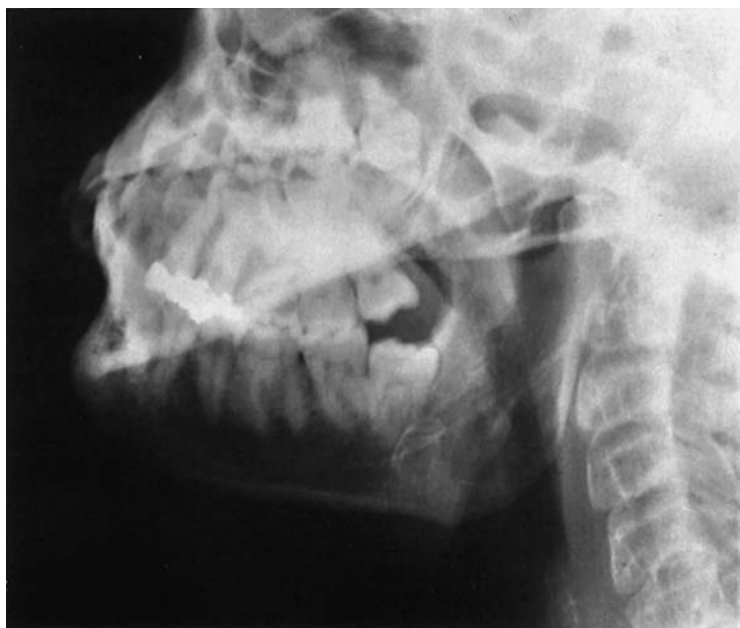- | | |
|--|--|
| 1 Frontal sinus | 8 Lateral wall of the orbit |
| 2 Roof of the orbit | 9 Superior orbital fissure |
| 3 Left lesser wing of the sphenoid | 10 Sphenoid sinus |
| 4 Right lesser wing of the sphenoid | 11 Zygomatic arch |
| 5 Sphenoid | 12 Petrous portion of the temporal bone |
| 6 Ethmoid sinus | 13 Maxillary sinus |
| 7 Optic canal | |

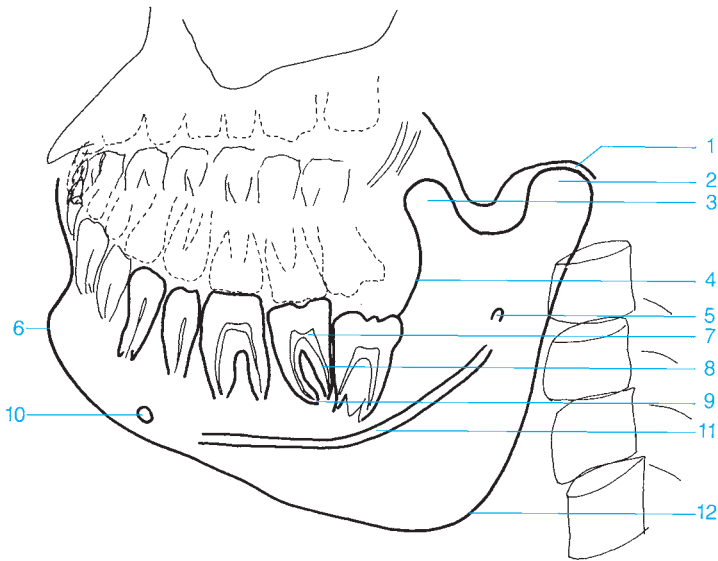




- 1 Floor of the orbit
- 2 Nasal septum
- 3 Base of the skull
- 4 Maxillary sinus
- 5 Lateral wall of the maxilla

- 6 Anterior nasal spine
- 7 Coronoid process
- 8 Maxilla
- 9 Ramus of the mandible
- 10 Angle of the mandible





1 Temporomandibular joint

2 Condyle of the mandible

3 Coronoid process

4 Cortex of ramus of the mandible

5 Mandibular foramen

6 Mental protuberance

7 Pulp cavity

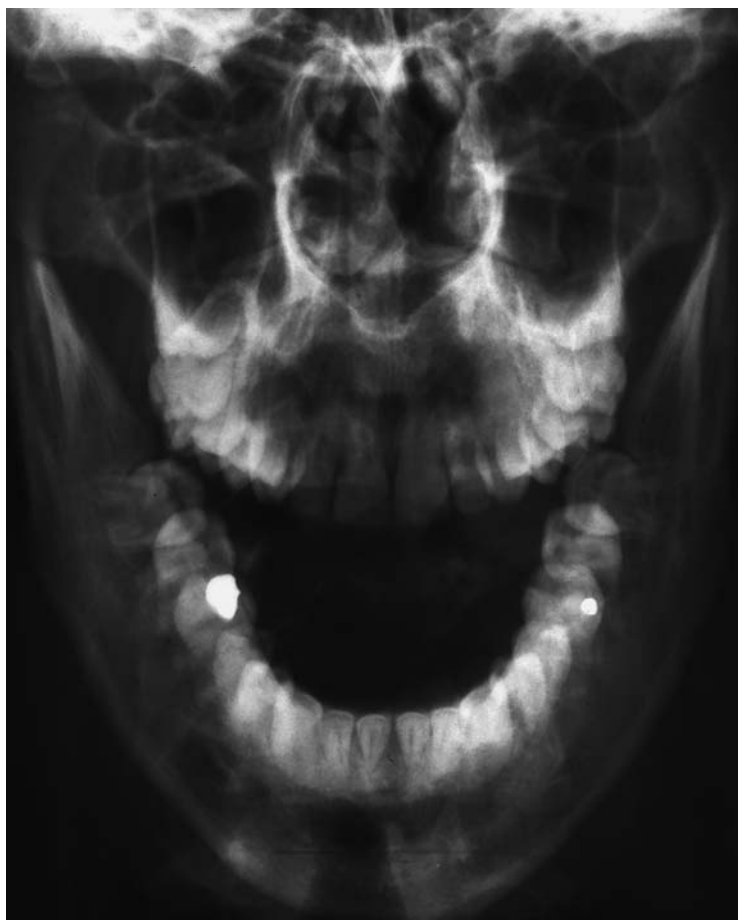8 Root canal

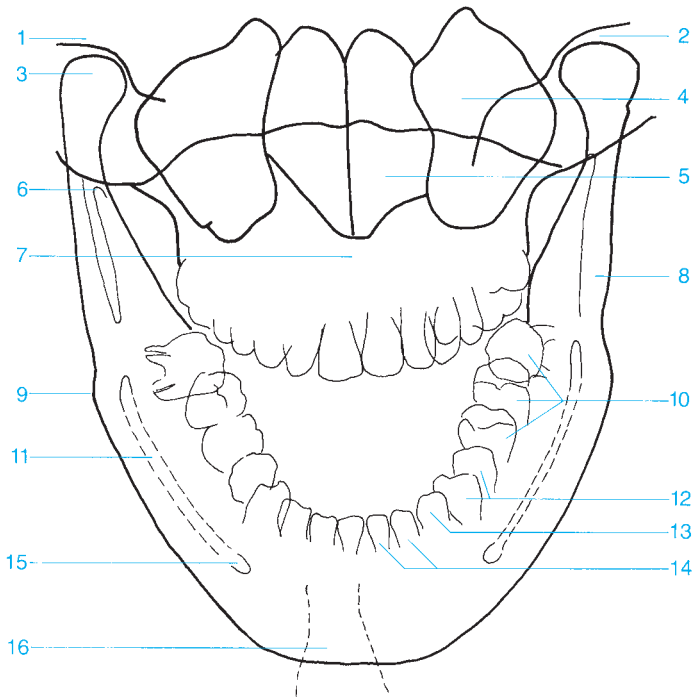
9 Apical foramen of the tooth

10 Mental foramen

11 Mandibular canal

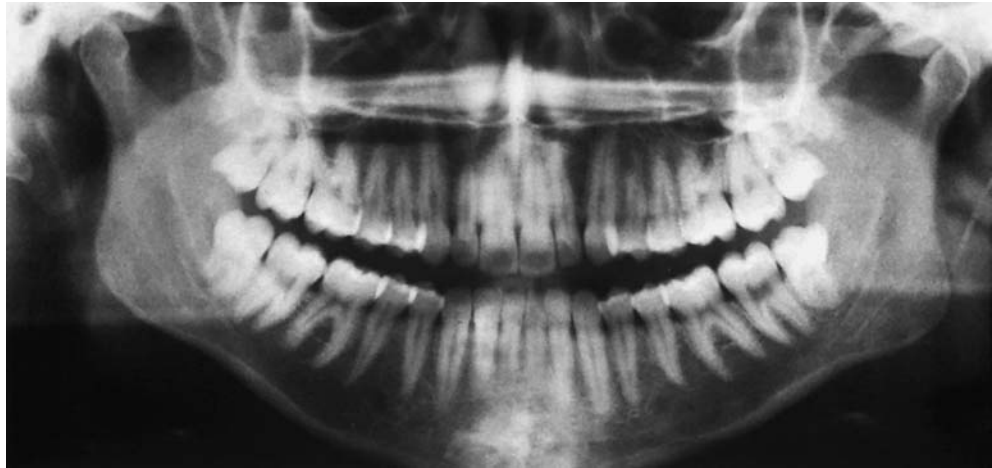
12 Angle of the mandible



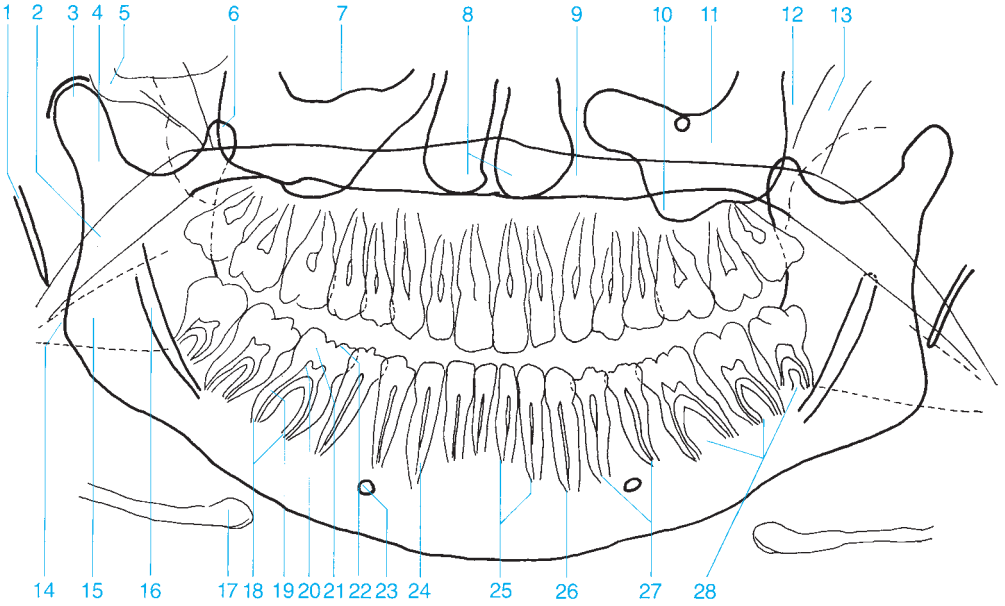


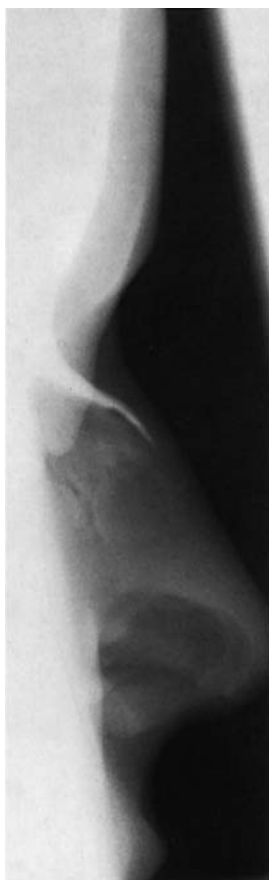- 1 Temporal bone
- 2 Temporomandibular joint
- 3 Condyle of the mandible
- 4 Maxillary sinus
- 5 Nasal cavity
- 6 Coronoid process
- 7 Maxilla
- 8 Ramus of the mandible
- 9 Angle of the mandible

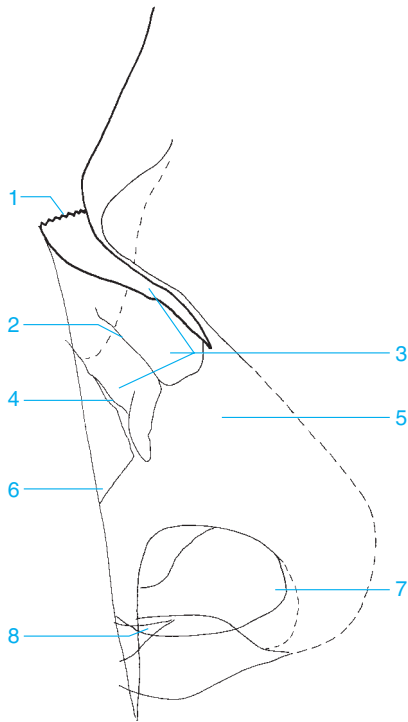
- 10 Molars
- 11 Mandibular canal
- 12 Premolars
- 13 Canines
- 14 Incisors
- 15 Mental foramen
- 16 Mental protuberance (trachea superimposed as radiolucent band)



- | | | | |
|---------------------------|-----------------------------------|--------------------------------|----------------------|
| 1 Styloid process | 9 Hard palate | 16 Mandibular canal | 23 Mental foramen |
| 2 Soft palate | 10 Alveolar recess of the maxilla | 17 Hyoid bone | 24 Root of the tooth |
| 3 Condyle of the mandible | 11 Maxillary sinus | 18 Apical foramen of the tooth | 25 Incisor |
| 4 Condylar process | 12 Pterygopalatine fossa | 19 Root canal | 26 Canine |
| 5 Zygomatic arch | 13 Pterygoid process | 20 Pulp cavity | 27 Premolar |
| 6 Coronoid process | 14 Angle of the mandible | 21 Dentin | 28 Molar |
| 7 Floor of the orbit | 15 Shadow of the tongue | 22 Enamel | |

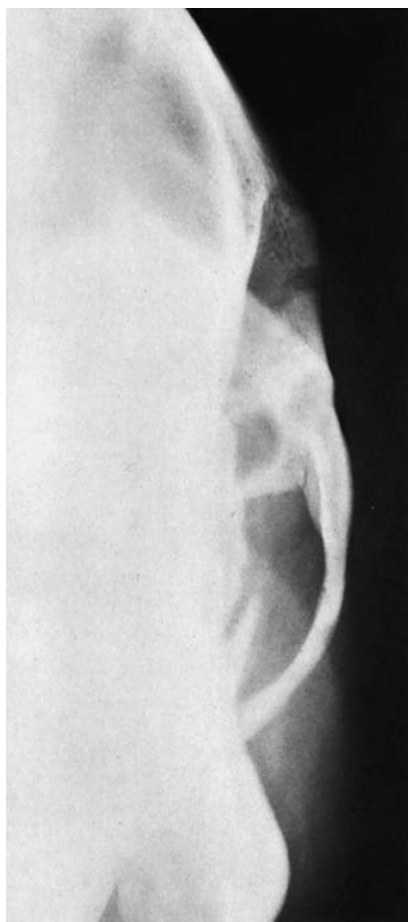

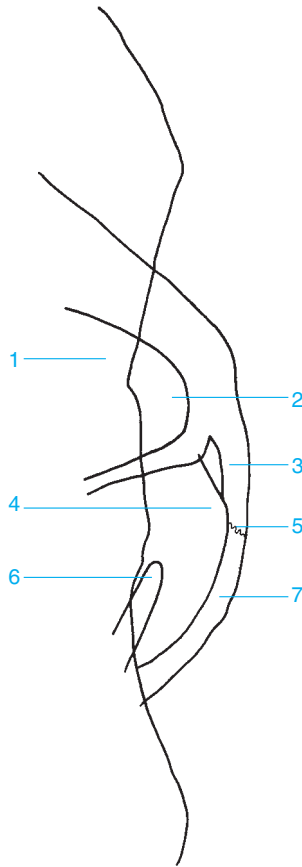




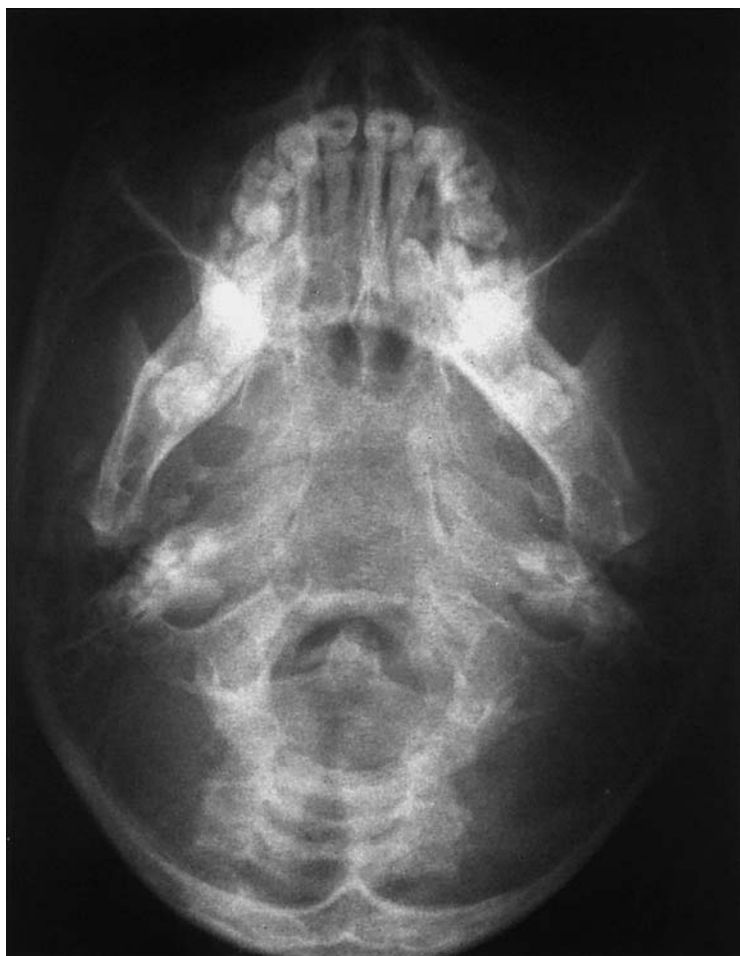- 1 Frontonasal suture
- 2 Ethmoidal groove
- 3 Nasal bone
- 4 Nasomaxillary suture

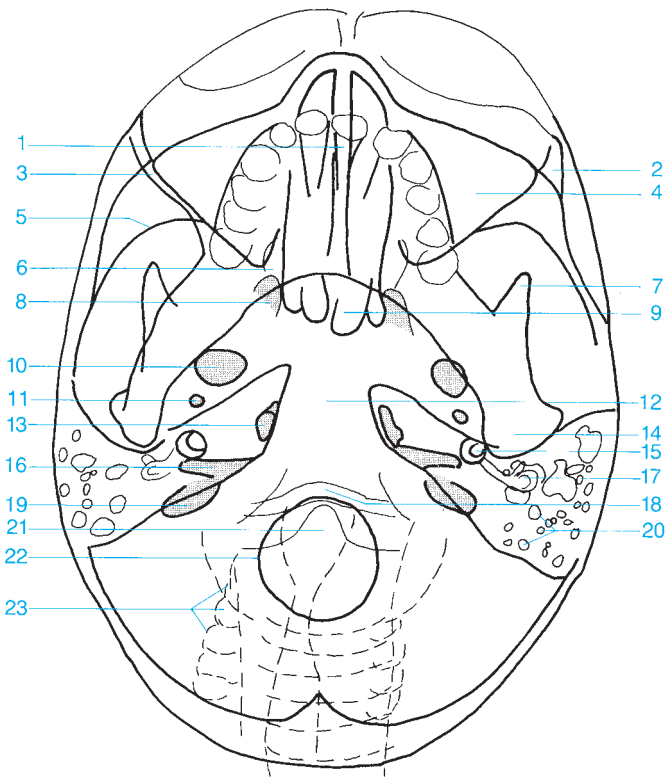
- 5 Nasal cartilage
- 6 Maxilla
- 7 Vestibule of nose
- 8 Anterior nasal spine



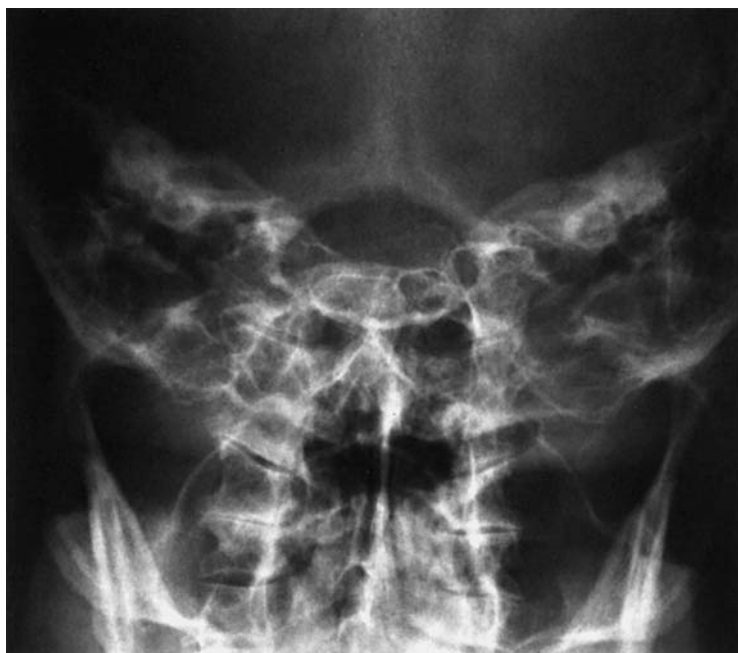

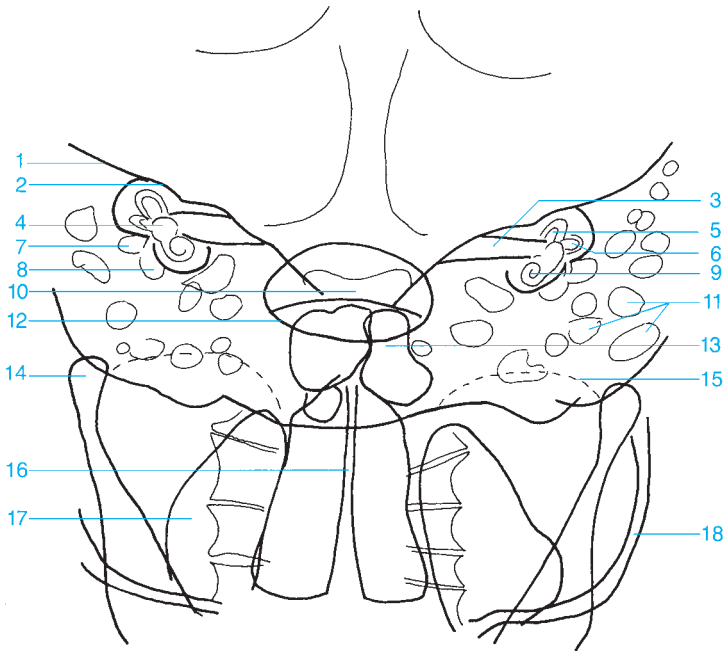
- | | |
|---|--|
| 1 Maxillary sinus | 5 Temporozygomatic suture |
| 2 Zygomatic recess (of the maxillary sinus) | 6 Coronoid process (visualized end on) |
| 3 Zygomatic arch | 7 Zygomatic process of the temporal bone |
| 4 Temporal fossa | |



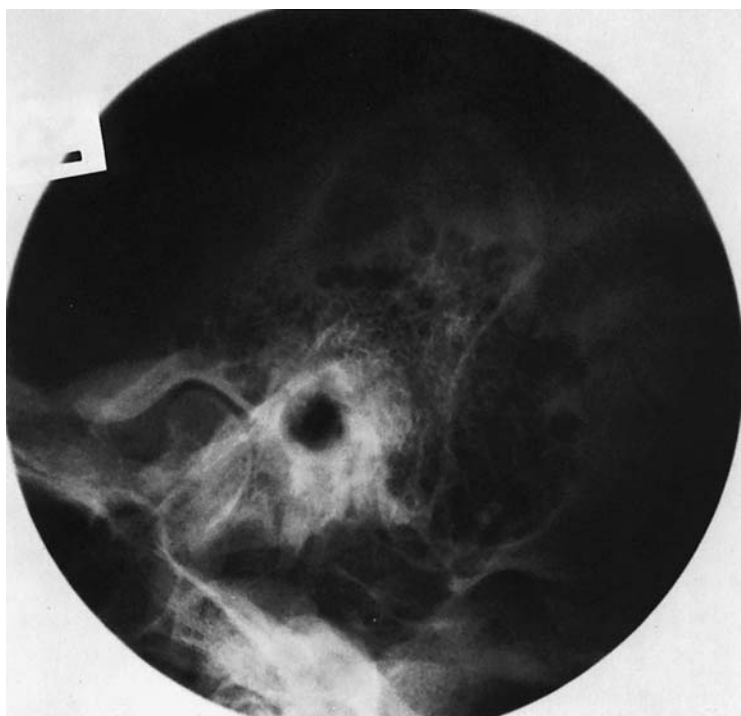


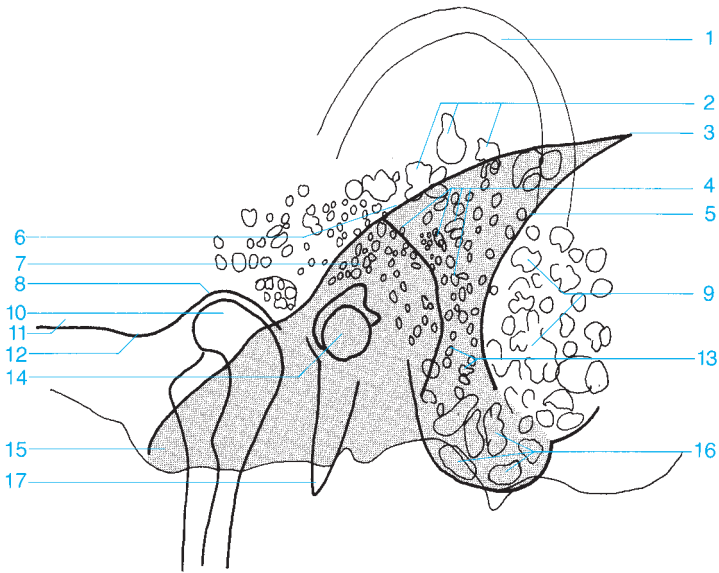
- | | |
|--|-------------------------------|
| 1 Nasal septum | 11 Foramen spinosum |
| 2 Zygomatic bone | 12 Clivus |
| 3 Posterior wall of maxillary sinus | 13 Foramen lacerum |
| 4 Maxillary sinus (with orbit, partially superimposed) | 14 Condyle of the mandible |
| 5 Middle cranial fossa, greater wing (anterior wall of middle cranial fossa) | 15 Cochlea |
| 6 Pterygopalatine fossa | 16 Internal auditory canal |
| 7 Coronoid process | 17 Semicircular canals |
| 8 Pterygoid fossa | 18 Anterior arch of the atlas |
| 9 Sphenoid sinus | 19 Jugular foramen |
| 10 Foramen ovale | 20 Mastoid air cells |
| | 21 Dens of the axis |
| | 22 Foramen magnum |
| | 23 Cervical spine |



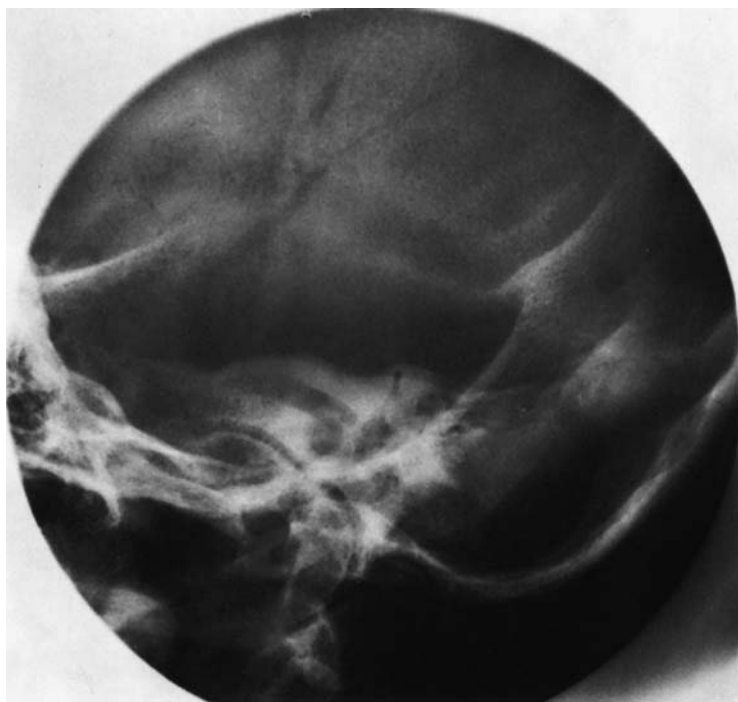


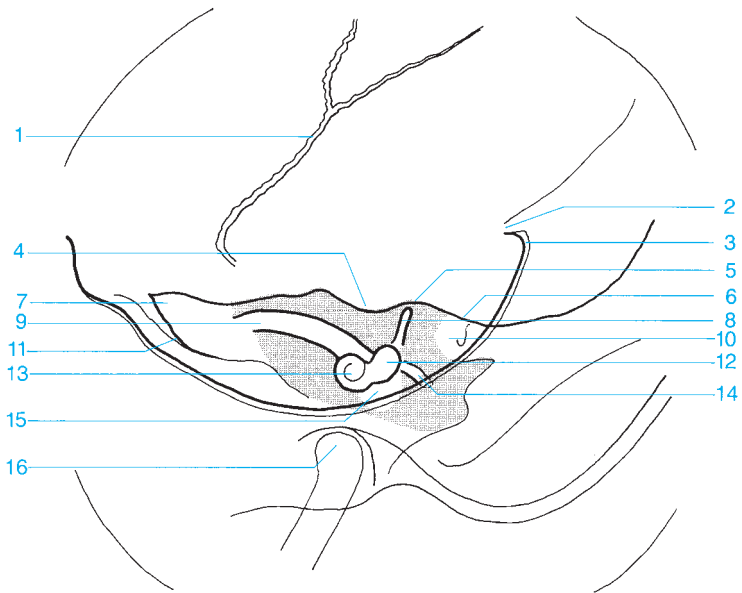
- | | |
|-------------------------------|------------------------------------|
| 1 Petrous ridge | 10 Dorsum sellae |
| 2 Arcuate eminence | 11 Mastoid air cells |
| 3 Internal auditory canal | 12 Foramen magnum |
| 4 Vestibule | 13 Frontal sinus |
| 5 Anterior semicircular canal | 14 Condyle of the mandible |
| 6 Lateral semicircular canal | 15 Roof of the orbit |
| 7 Antrum of the mastoid | 16 Nasal septum and nasal cavities |
| 8 Tympanic cavity | 17 Maxillary sinus |
| 9 Cochlea | 18 Zygomatic arch |



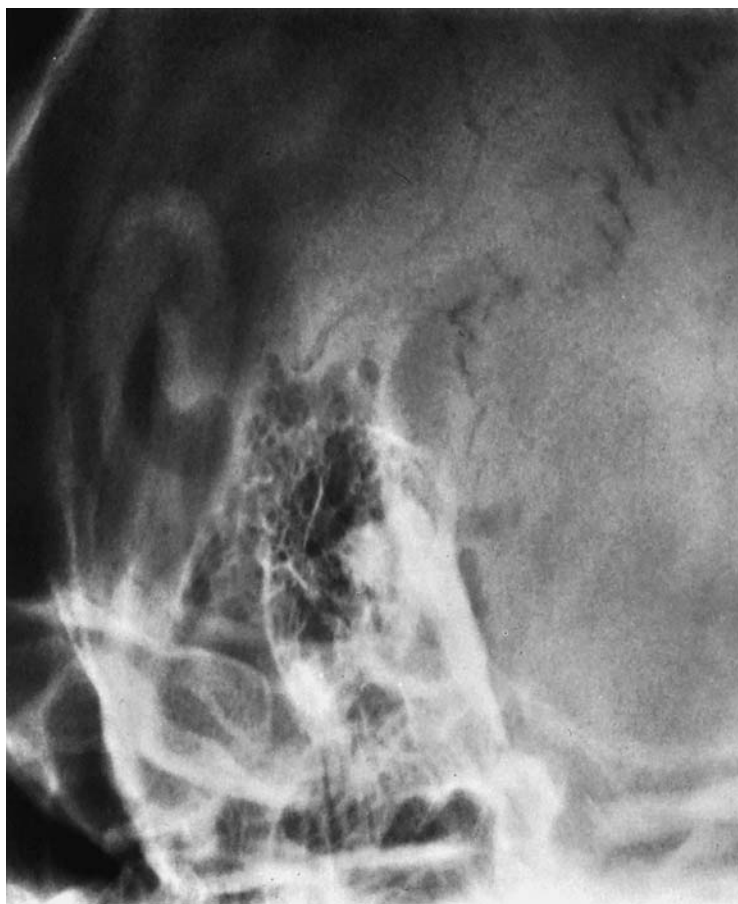

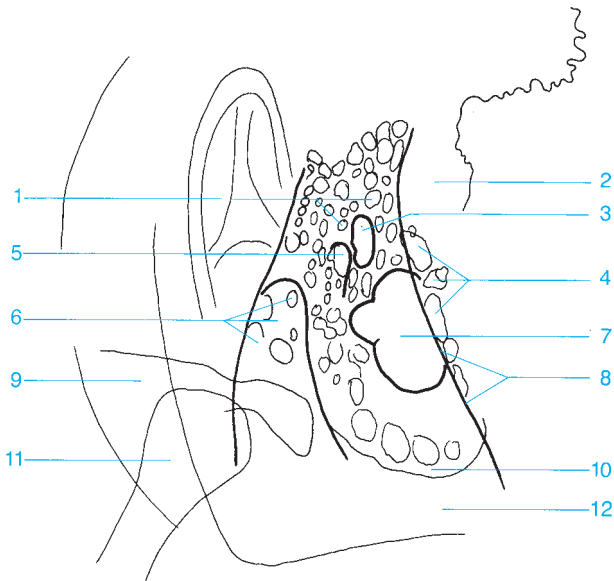
- | | |
|--|---|
| 1 Outer ear | 11 Zygomatic process of the temporal bone |
| 2 Squamous air cells | 12 Articular tubercle |
| 3 Angle of Citelli | 13 Retrofacial air cells |
| 4 Periantral air cells | 14 Internal and external auditory canal |
| 5 Sulcus of the sigmoid sinus | 15 Apex of the petrous bone |
| 6 Anterior margin of the petrous bone | 16 Air cells in the tip of the mastoid process |
| 7 Antrum of the mastoid | 17 Styloid process |
| 8 Temporomandibular joint fossa | |
| 9 Marginal air cells | |
| 10 Condyle of the mandible | |



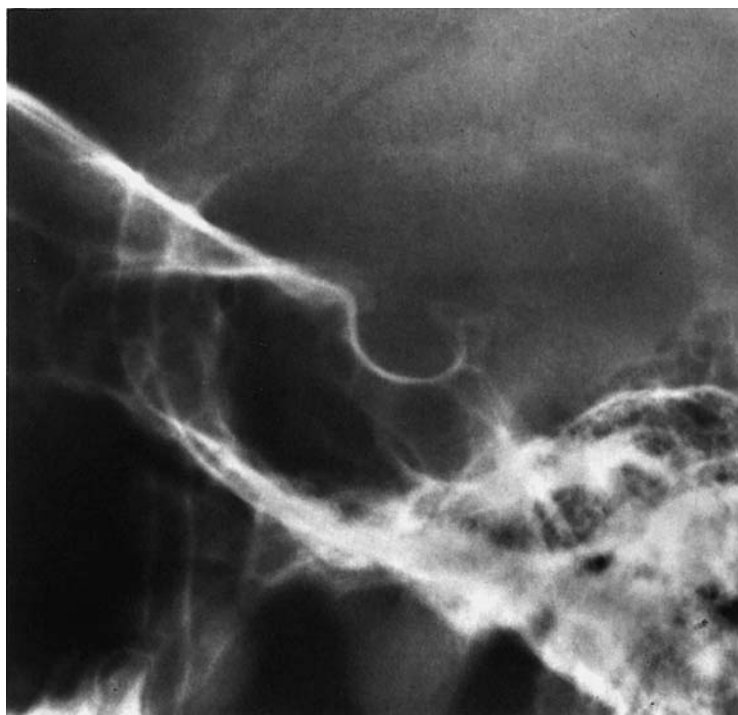



- | | |
|-----------------------------------|-------------------------------|
| 1 Sphenosquamous suture | 9 Internal auditory canal |
| 2 Internal occipital protuberance | 10 Antrum |
| 3 Internal occipital crest | 11 Sphenopetrosal fissure |
| 4 Subarcuate fossa | 12 Vestibule |
| 5 Arcuate eminence | 13 Cochlea |
| 6 Roof of the tympanic cavity | 14 Lateral semicircular canal |
| 7 Apex of the petrous pyramid | 15 Tympanic cavity |
| 8 Anterior semicircular canal | 16 Condyle of the mandible |





- | | |
|--|--|
| 1 Periantral air cells | 7 Osseous labyrinth |
| 2 Sigmoid sinus | 8 Osseous sinus wall (posterior margin of the petrous bone) |
| 3 Antrum | 9 Zygomatic bone |
| 4 Retrosinus air cells | 10 Apex of the mastoid |
| 5 Aperture of mastoid antrum | 11 Condyle of the mandible |
| 6 External auditory canal and tympanic cavity | 12 Apex of the petrous bone |





1 Floor of anterior cranial fossa and roof of orbits

2 Sphenoid

3 Anterior clinoid process

4 Tuberculum sellae

5 Posterior clinoid process

6 Dorsum sellae

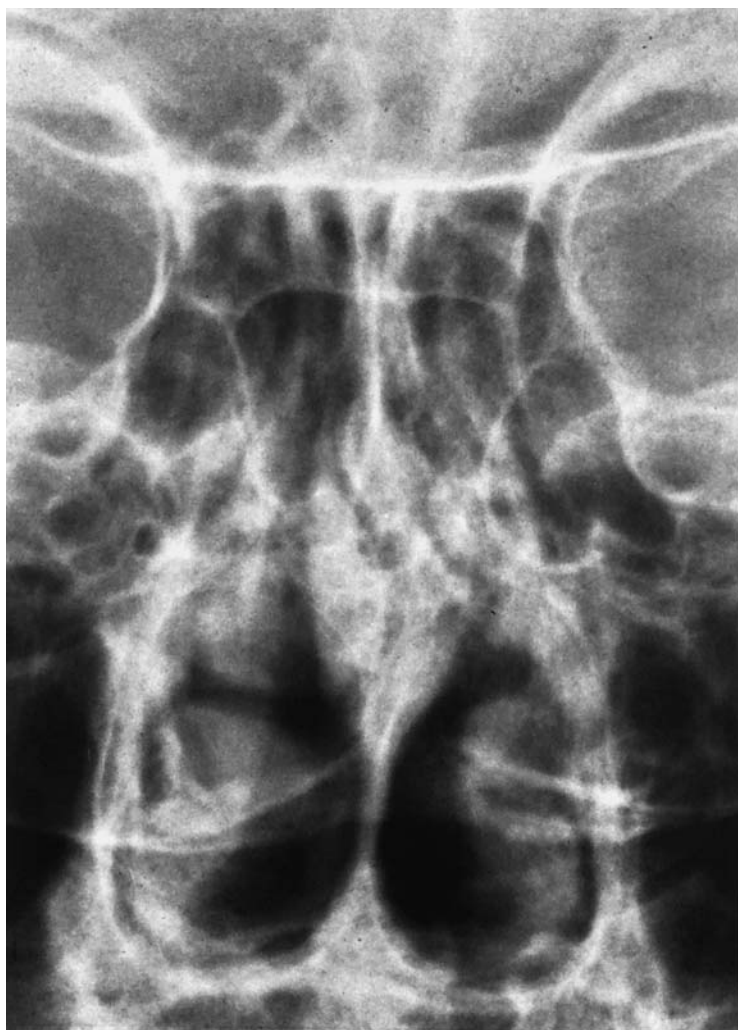7 Pituitary fossa

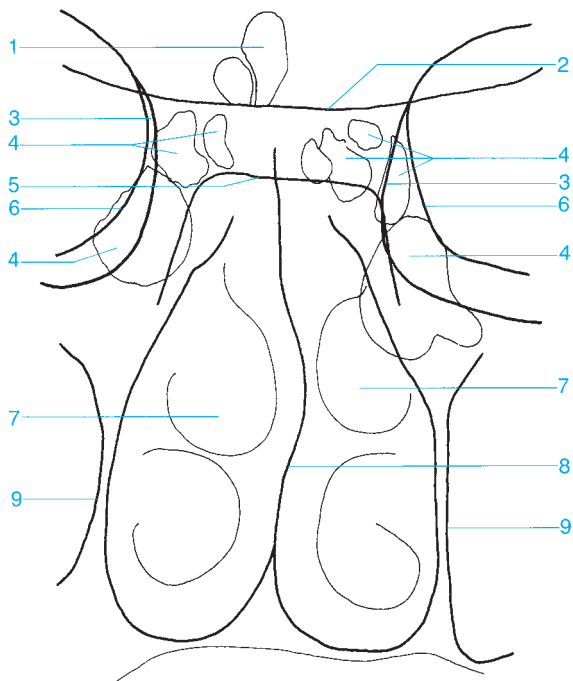
8 Sphenoid sinus

9 Clivus

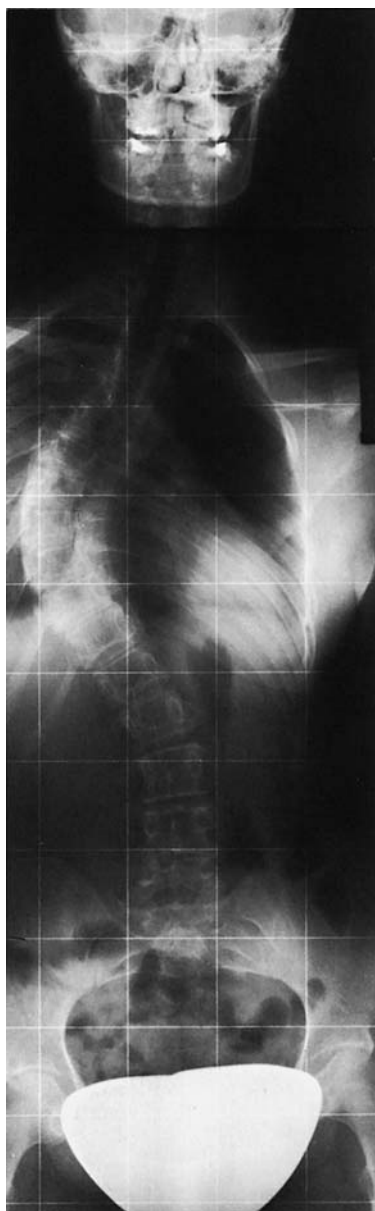
10 Petrous ridge

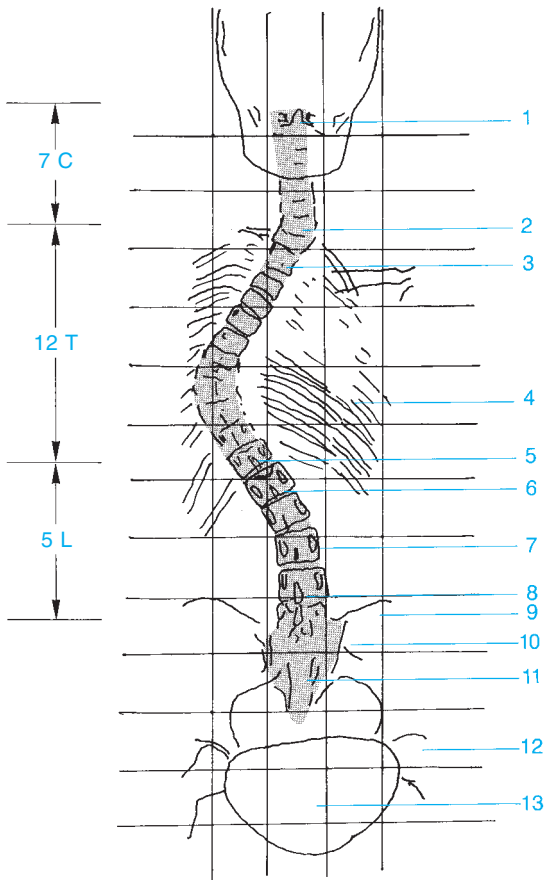
11 Greater wing of the sphenoid





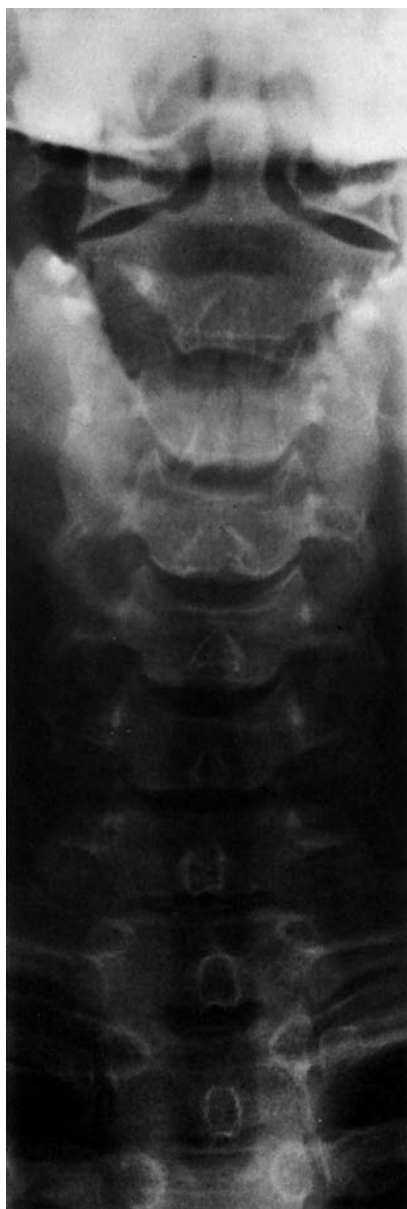- | | |
|--|--------------------------------------|
| 1 Frontal sinuses | 6 Orbital plate |
| 2 Sphenoid | 7 Nasal turbinates |
| 3 Medial wall of orbit | 8 Nasal septum |
| 4 Ethmoid sinus | 9 Medial wall of the maxillary sinus |
| 5 Pituitary fossa (floor of the sella turcica) | |

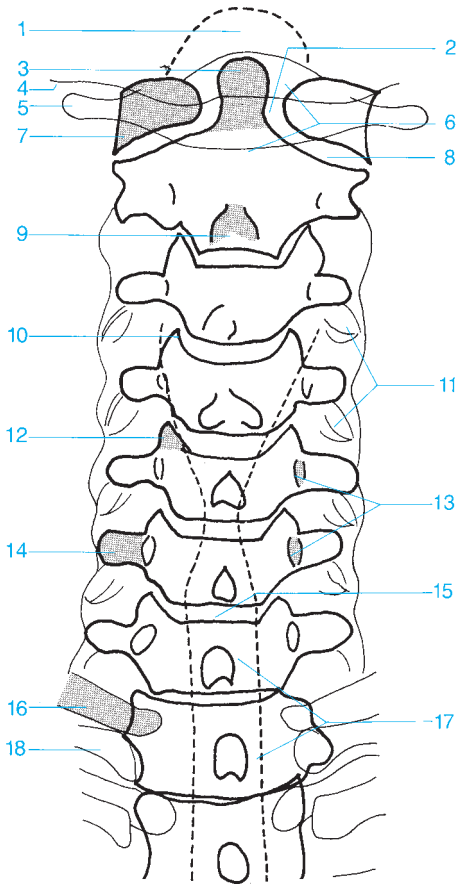




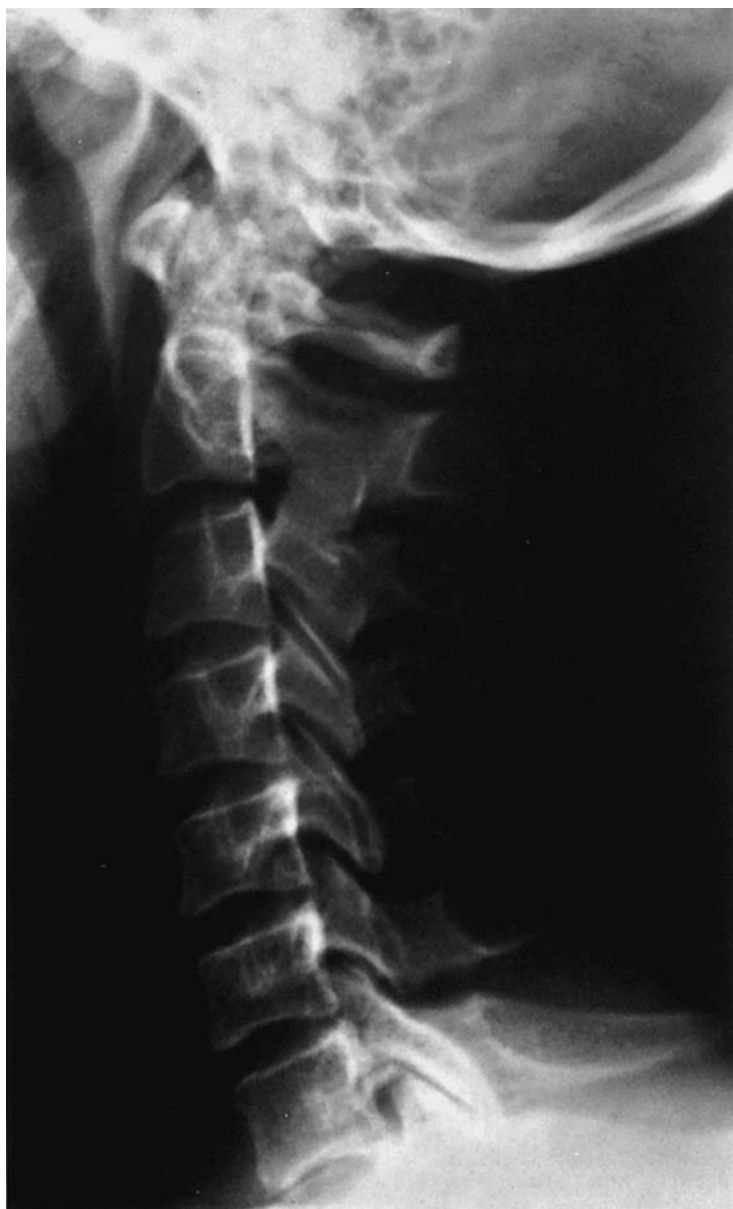- 1 Dens of the axis
- 2 C7
- 3 T2
- 4 Rib cage
- 5 T12
- 6 L1
- 7 Pedicle, L3

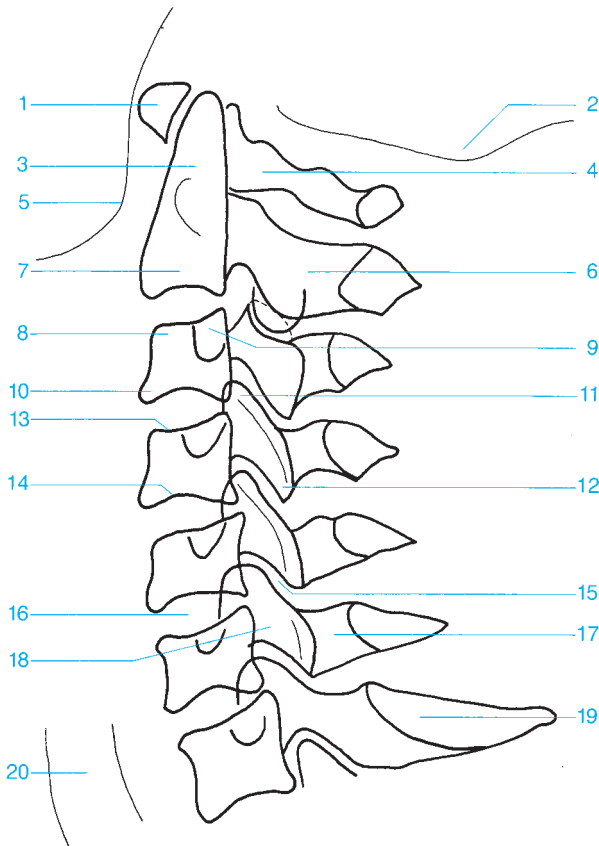
- 8 Spinous process, L6
- 9 Ilium
- 10 Sacroiliac joint
- 11 Sacrum
- 12 Hip
- 13 Gonad shield



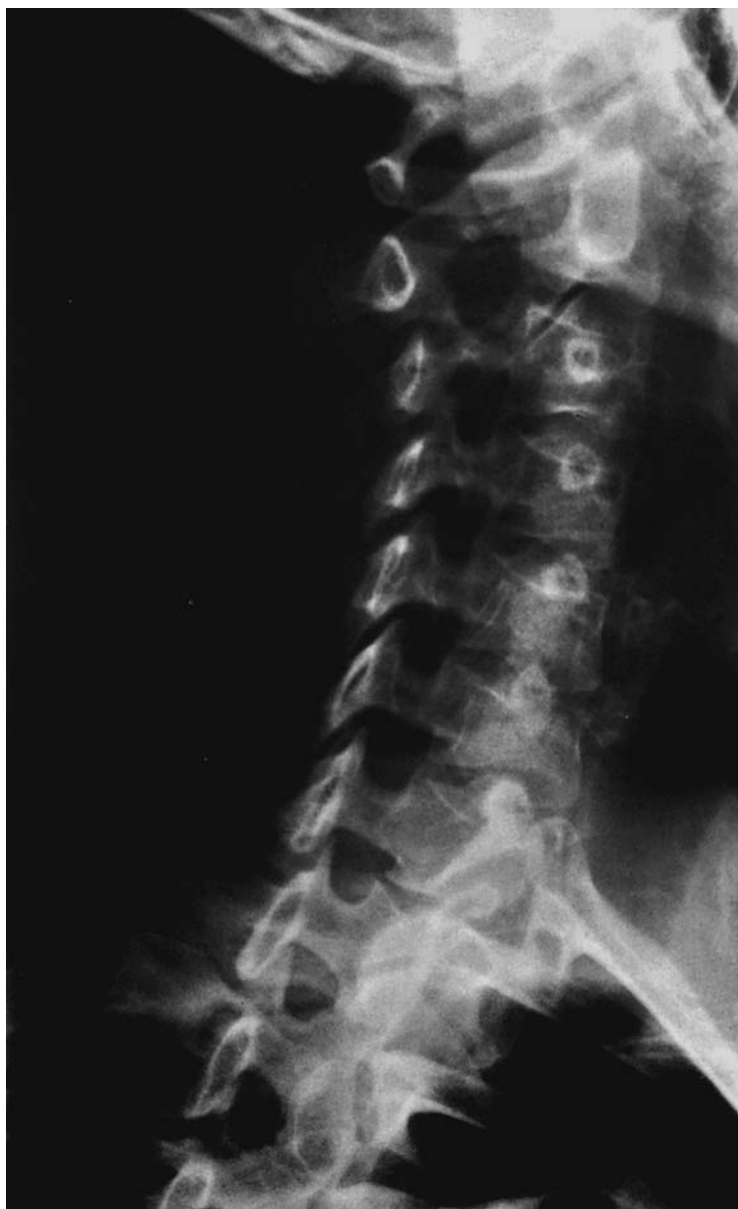

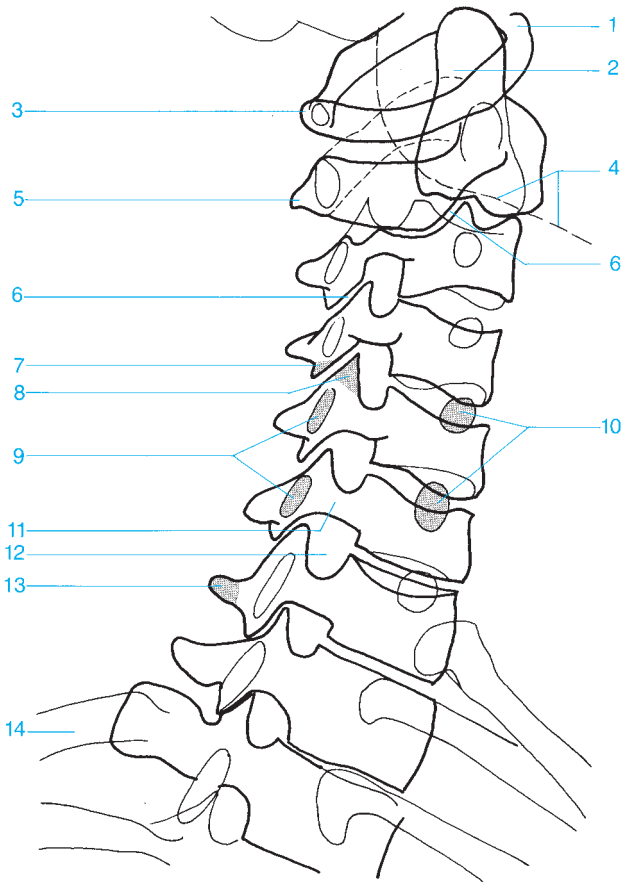
- | | |
|---------------------------|------------------------------------|
| 1 Foramen magnum | 10 Uncovertebral joint |
| 2 Atlantoaxial joint | 11 Overlapping articular processes |
| 3 Dens of the axis | 12 Uncinate process |
| 4 Occipital bone | 13 Pedicle |
| 5 Transverse process | 14 Transverse process |
| 6 Vertebral arch | 15 Intervertebral disk space |
| 7 Lateral mass of C1 | 16 Transverse process of T1 |
| 8 Atlantoaxial joint | 17 Radiolucent band of the trachea |
| 9 Spinous process (bifid) | 18 First rib |





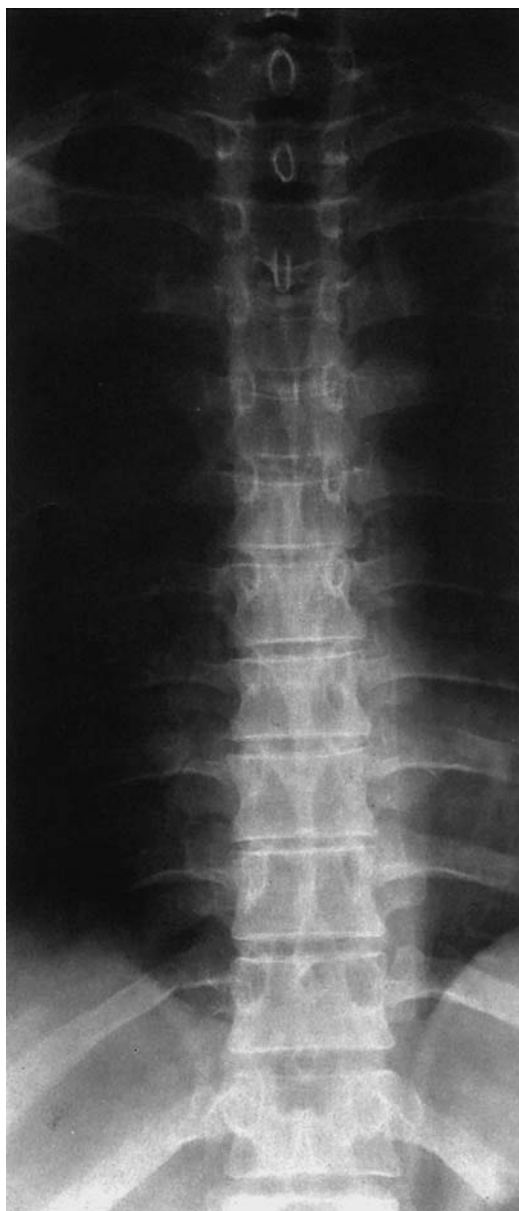- | | |
|--|--|
| 1 Anterior arch of the atlas | 11 Superior articular facet |
| 2 Base of the skull | 12 Inferior articular facet |
| 3 Odontoid process | 13 Superior vertebral end plate |
| 4 Posterior arch of the atlas | 14 Inferior vertebral end plate |
| 5 Mandible | 15 Intervertebral facet joint |
| 6 Spinous process | 16 Intervertebral disk space |
| 7 Body of the axis | 17 Lamina |
| 8 Anterior superior margin of the vertebra | 18 Articular pillar |
| 9 Transverse process | 19 Spinous process |
| 10 Anterior inferior margin of the vertebra | 20 Trachea |

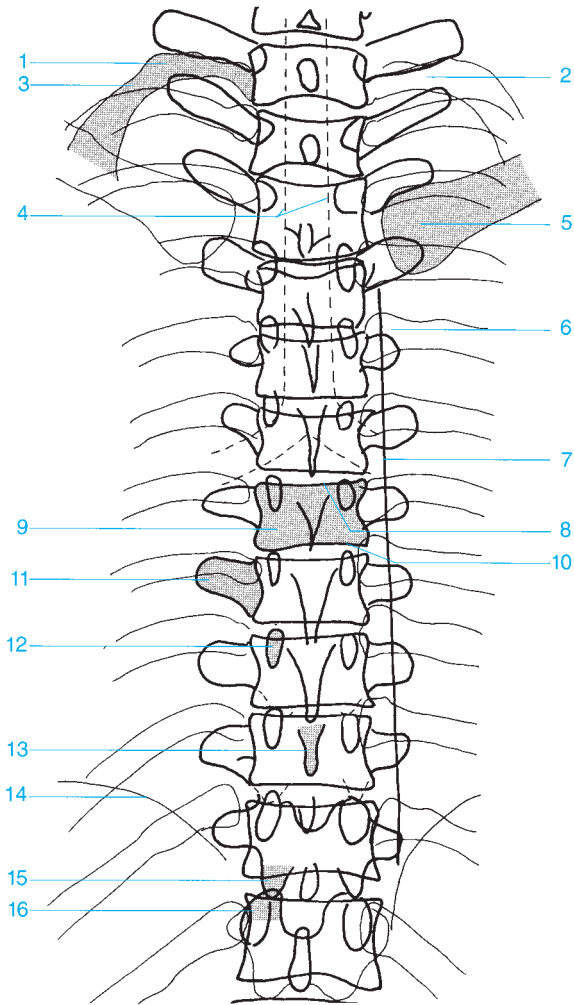




- 1 Anterior arch
- 2 Odontoid process
- 3 Atlas
- 4 Mandible
- 5 Body of C2
- 6 Facet joint
- 7 Inferior articular process

- 8 Superior articular process
- 9 Transverse process
- 10 Contralateral pedicle
- 11 Pedicle
- 12 Intervertebral foramen
- 13 Spinous process
- 14 Ribs





1 Tubercle of first rib

2 Neck of the rib

3 First rib

4 Trachea

5 Clavicle

6 Head of the rib

7 Paravertebral line

8 Superior vertebral end plate

9 Body of vertebra

10 Inferior vertebral end plate

11 Transverse process

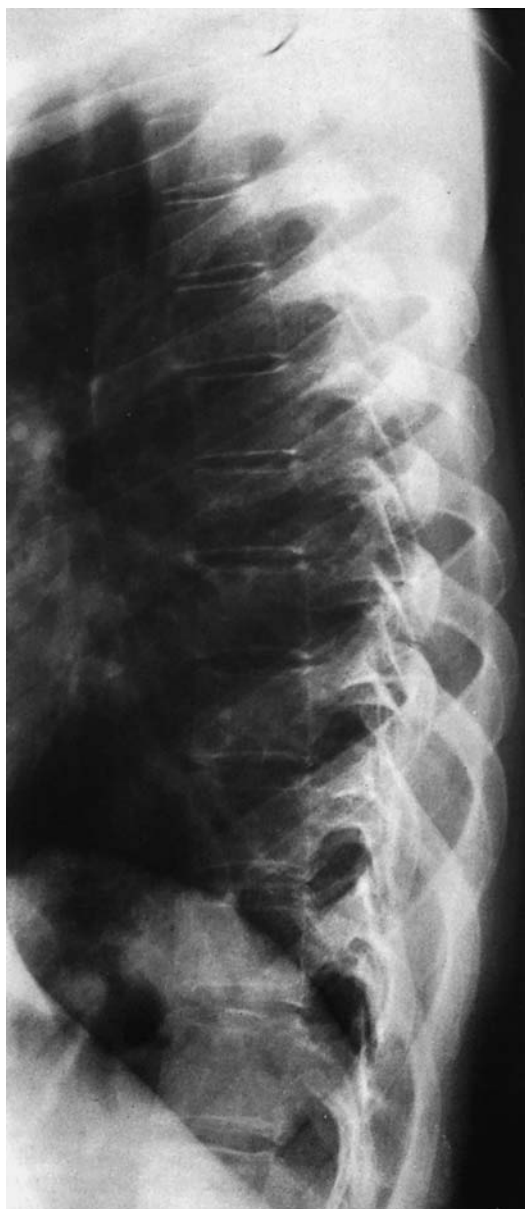12 Pedicle

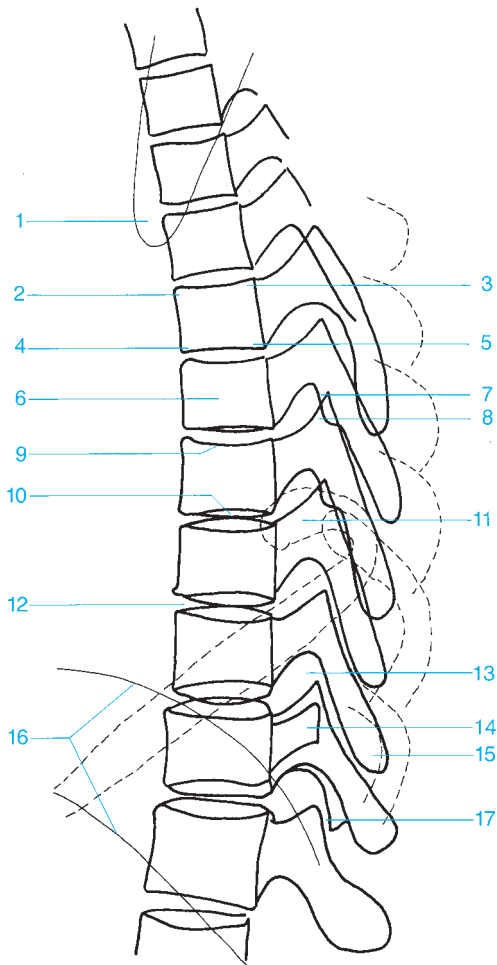
13 Spinous process

14 Diaphragm

15 Inferior articular process

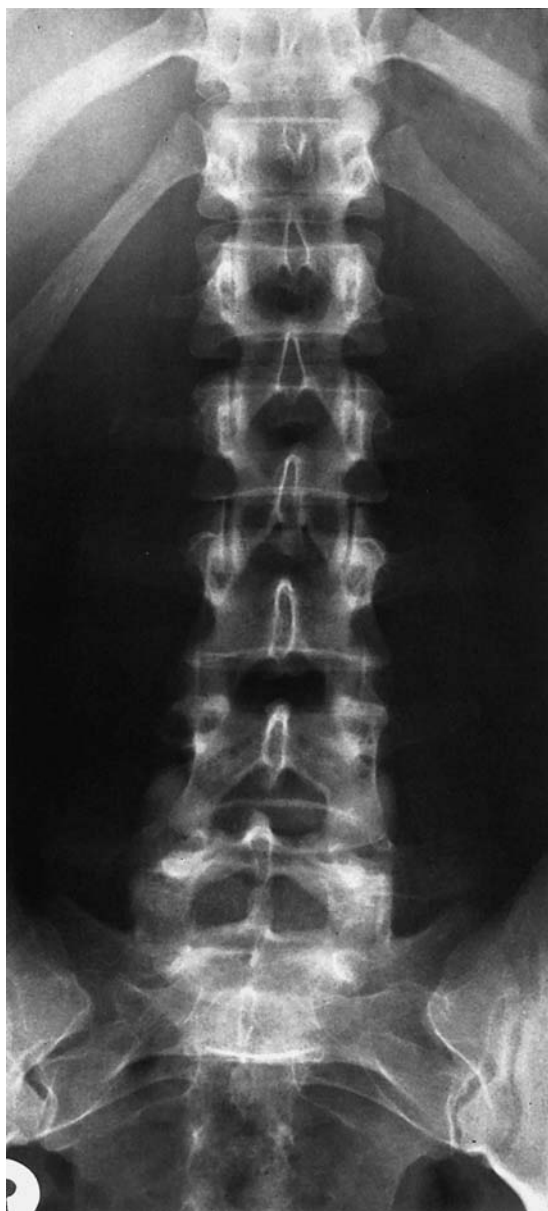16 Superior articular process

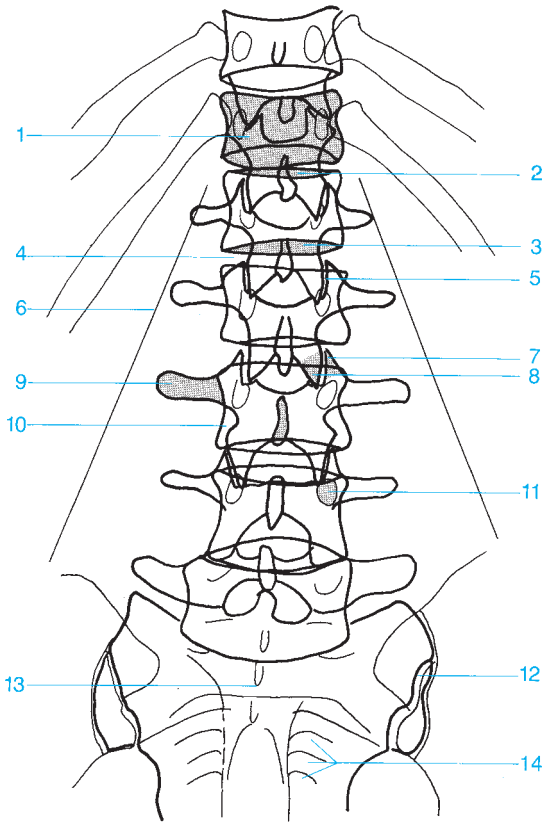




- 1 Scapula
- 2 Anterior superior margin
- 3 Posterior superior margin
- 4 Anterior inferior margin
- 5 Posterior inferior margin
- 6 Body of vertebra
- 7 Superior articular process
- 8 Inferior articular process
- 9 Superior vertebral end plate

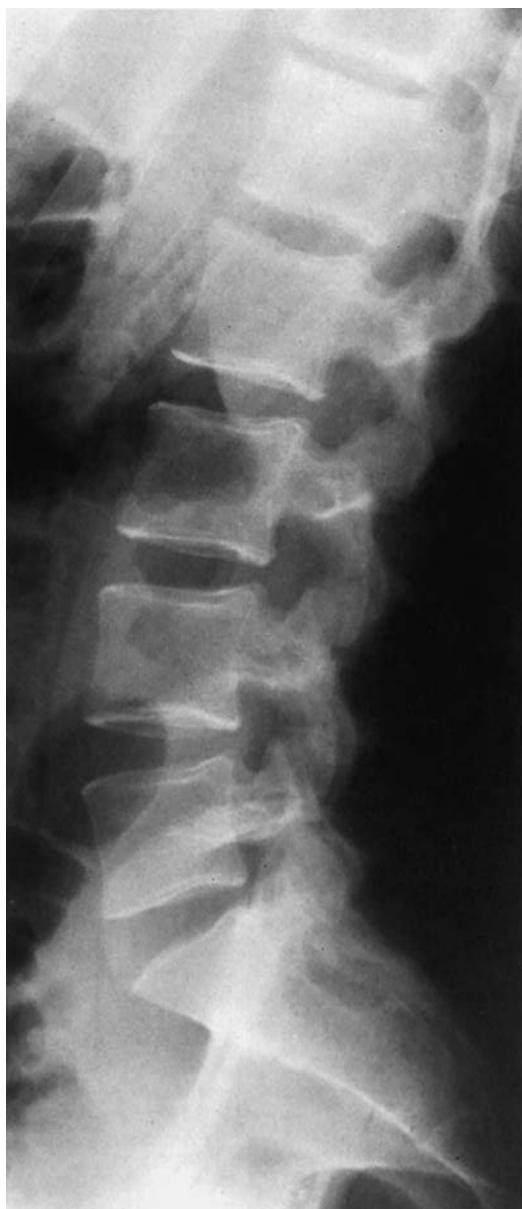- 10 Inferior vertebral end plate
- 11 Head of the rib
- 12 Intervertebral disk space
- 13 Intervertebral foramen
- 14 Transverse process
- 15 Spinous process
- 16 Diaphragm
- 17 Facet joint

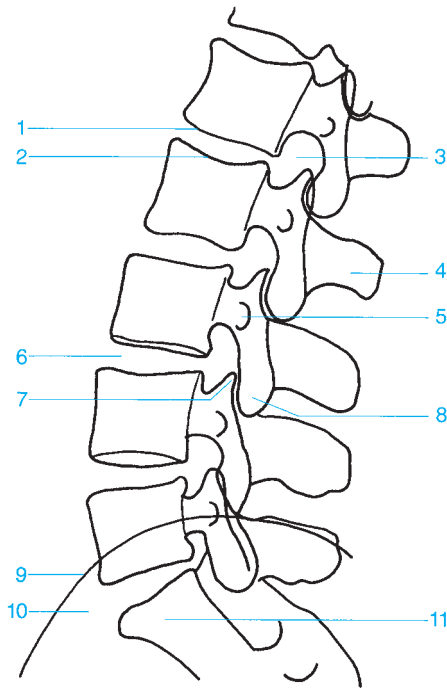




- 1 Body of vertebra
- 2 Superior vertebral end plate
- 3 Inferior vertebral end plate
- 4 Intervertebral disk space
- 5 Facet joint
- 6 Psoas
- 7 Superior articular process

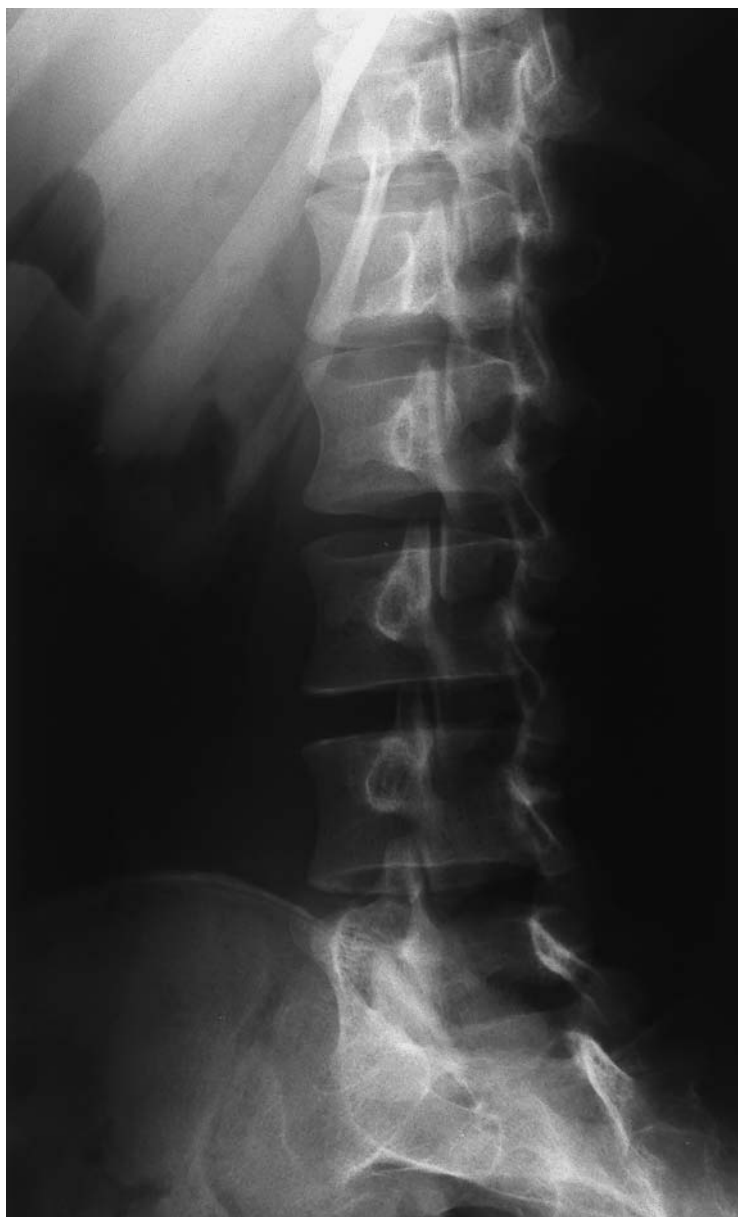- 8 Inferior articular process
- 9 Transverse process
- 10 Spinous process
- 11 Pedicle
- 12 Sacroiliac joint
- 13 Sacrum
- 14 Sacral foramina

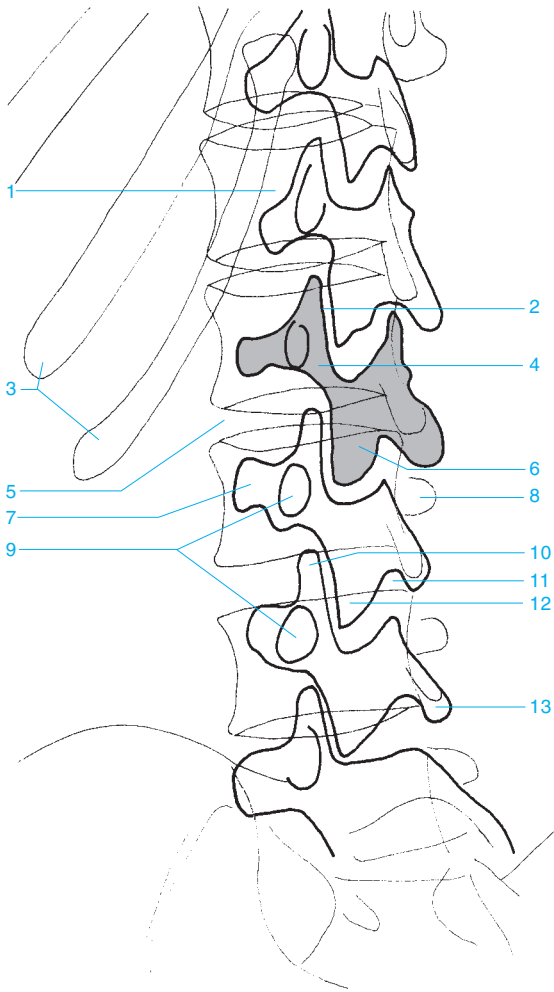




- 1 Superior vertebral end plate
- 2 Inferior vertebral end plate
- 3 Intervertebral foramen
- 4 Spinous process
- 5 Transverse process
- 6 Intervertebral disk space

- 7 Superior articular process
- 8 Inferior articular process
- 9 Iliac crest
- 10 Promontory
- 11 Sacrum





1 Body of vertebra

2 Intervertebral disk space

3 Ribs

4 Interarticular part

5 Intervertebral disk space

6 Lamina

7 Ipsilateral transverse process

8 Contralateral transverse process

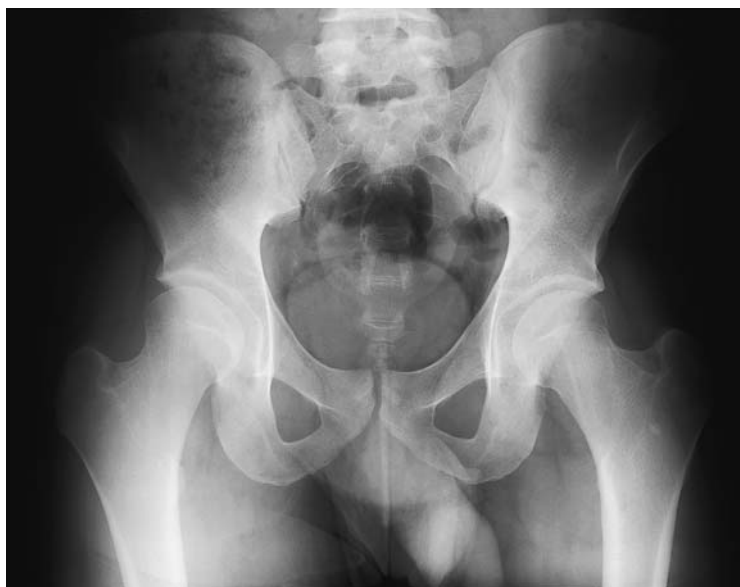9 Pedicle

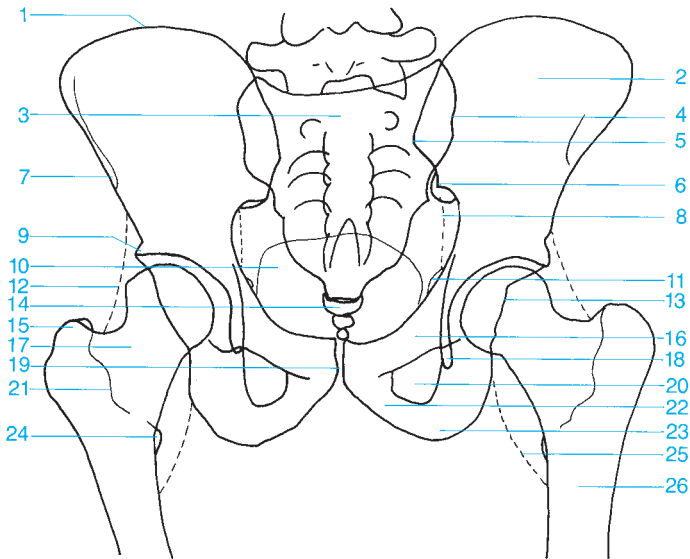
10 Superior articular process

11 Intervertebral foramen

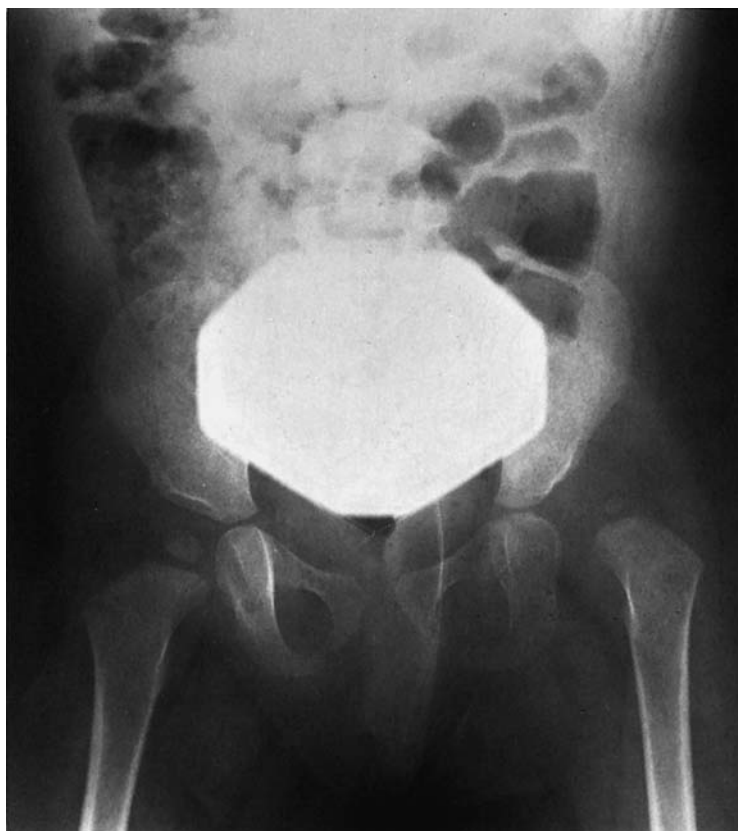12 Inferior articular process

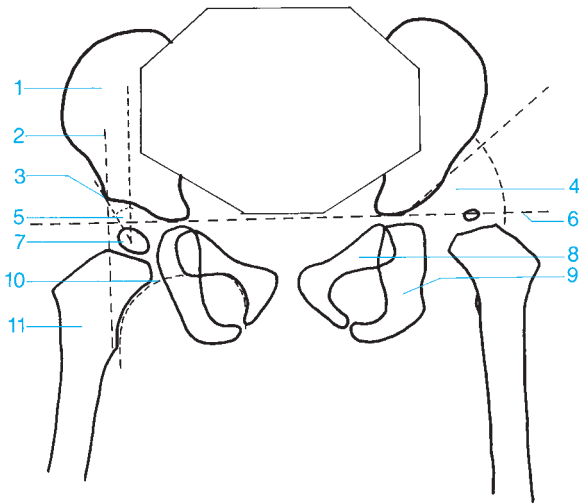
13 Spinous process



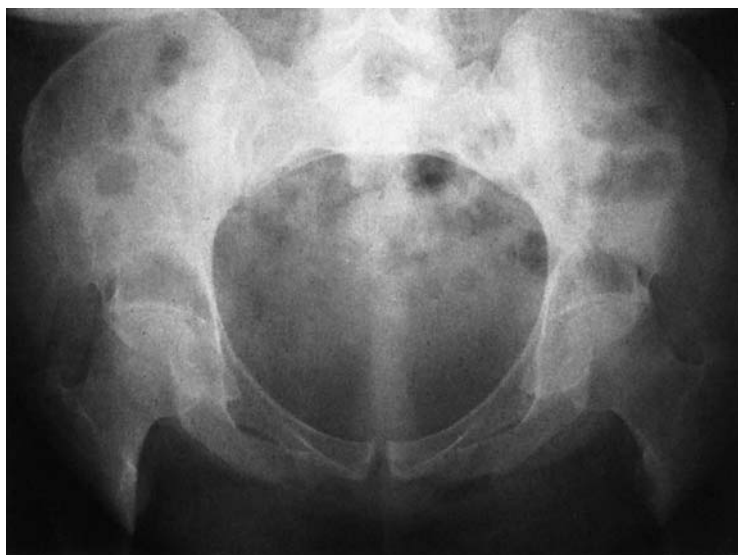

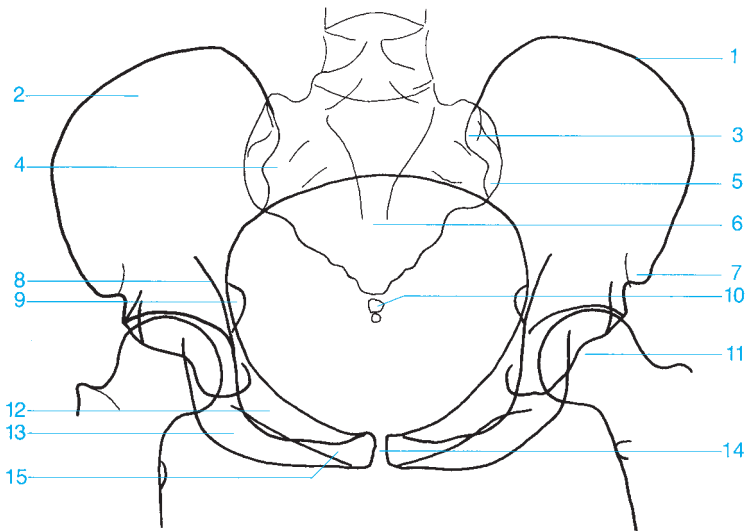
- | | |
|---|---------------------------------------|
| 1 Iliac crest | 13 Posterior acetabular rim |
| 2 Iliac wing | 14 Coccyx |
| 3 Sacrum | 15 Greater trochanter |
| 4 Sacroiliac joint | 16 Superior pubic ramus |
| 5 Posterior superior iliac spine | 17 Femoral neck |
| 6 Posterior inferior iliac spine | 18 Acetabular teardrop |
| 7 Anterior superior iliac spine | 19 Pubic symphysis |
| 8 Obturator internus | 20 Obturator foramen |
| 9 Acetabular convexity (promontory) | 21 Intertrochanteric crest |
| 10 Urinary bladder | 22 Inferior pubic ramus |
| 11 Spine of the ischium | 23 Ischial tuberosity |
| 12 Fat stripe medial to the gluteus minimus | 24 Lesser trochanter |
| | 25 Fat stripe medial to the iliopsoas |
| | 26 Femur |



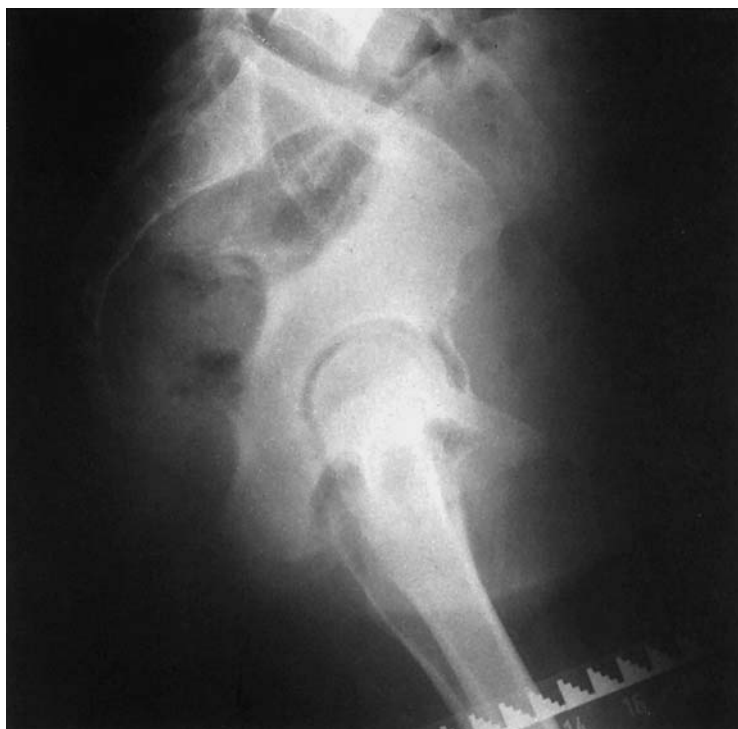

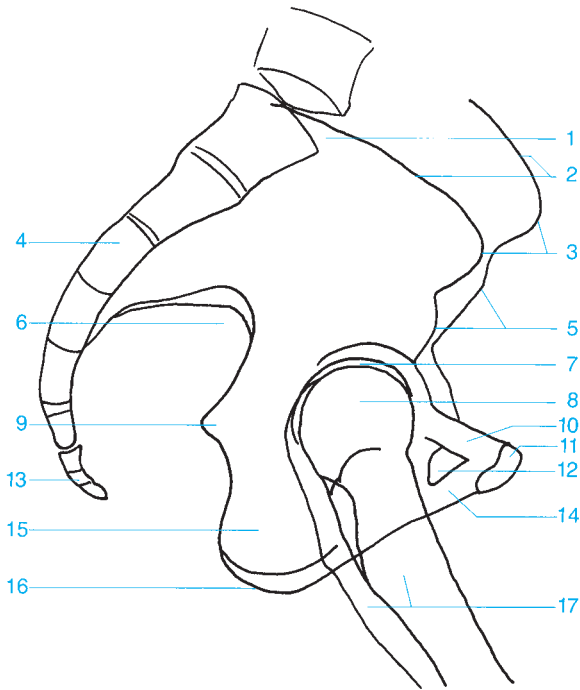
- | | |
|---|---|
| 1 Ilium | 6 Hilgenreiner's line (triradiate cartilage line) |
| 2 Perkin's line (vertical line from the roof of the acetabulum intersecting Hilgenreiner's line) | 7 Femoral epiphysis |
| 3 Acetabular convexity (promontory) | 8 Pubic bone |
| 4 Angle of acetabular inclination | 9 Ischium |
| 5 Wiberg's center-to-corner angle (the angle between a vertical line drawn from the center of the epiphysis and a line drawn from the roof of the acetabulum to the center of the epiphysis) | 10 Shenton's line (curved line formed by the superior curve of the obturator foramen and the femoral neck) |
| | 11 Femur |



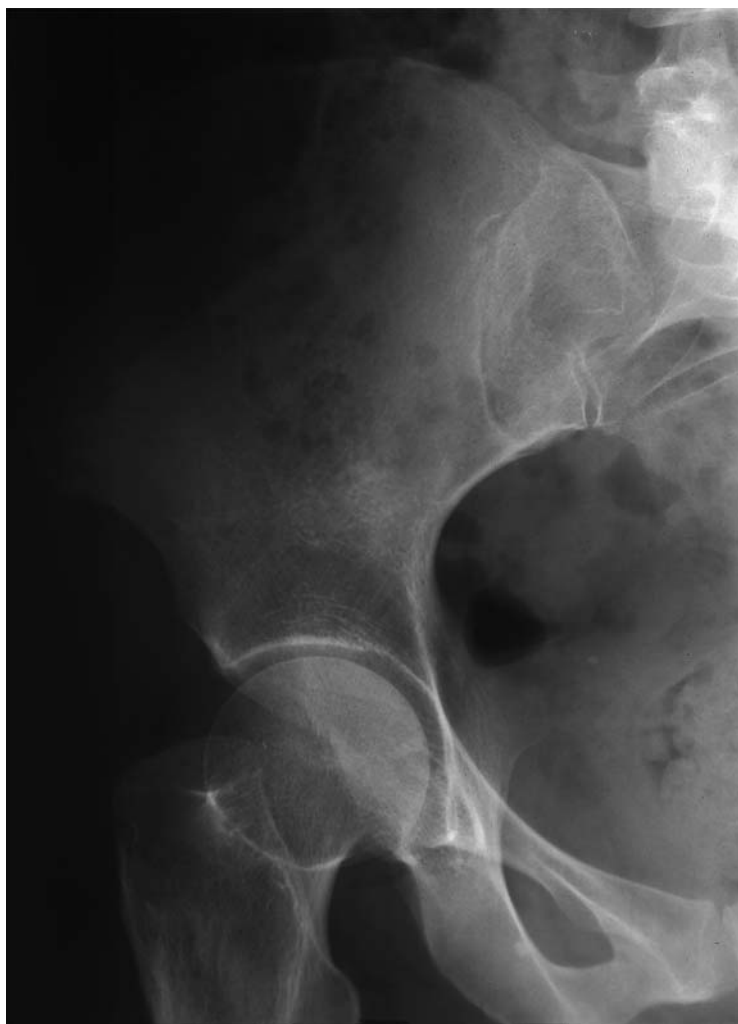

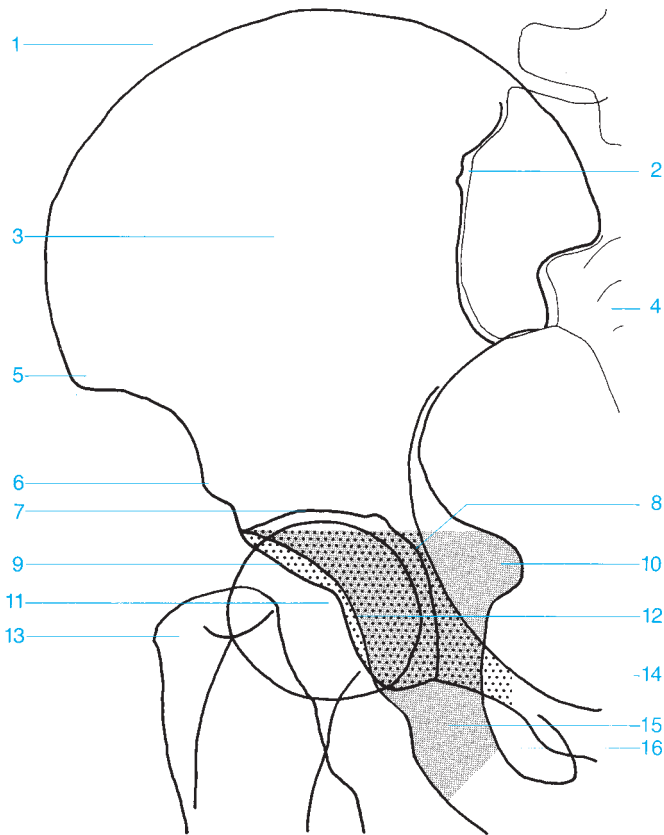
- | | |
|----------------------------------|-------------------------|
| 1 Iliac crest | 9 Spine of the ischium |
| 2 Iliac wing | 10 Coccyx |
| 3 Posterior superior iliac spine | 11 Femoral head |
| 4 Sacral ala | 12 Superior pubic ramus |
| 5 Posterior inferior iliac spine | 13 Ischial tuberosity |
| 6 Sacrum | 14 Pubic symphysis |
| 7 Anterior superior iliac spine | 15 Inferior pubic ramus |
| 8 Iliopubic line | |



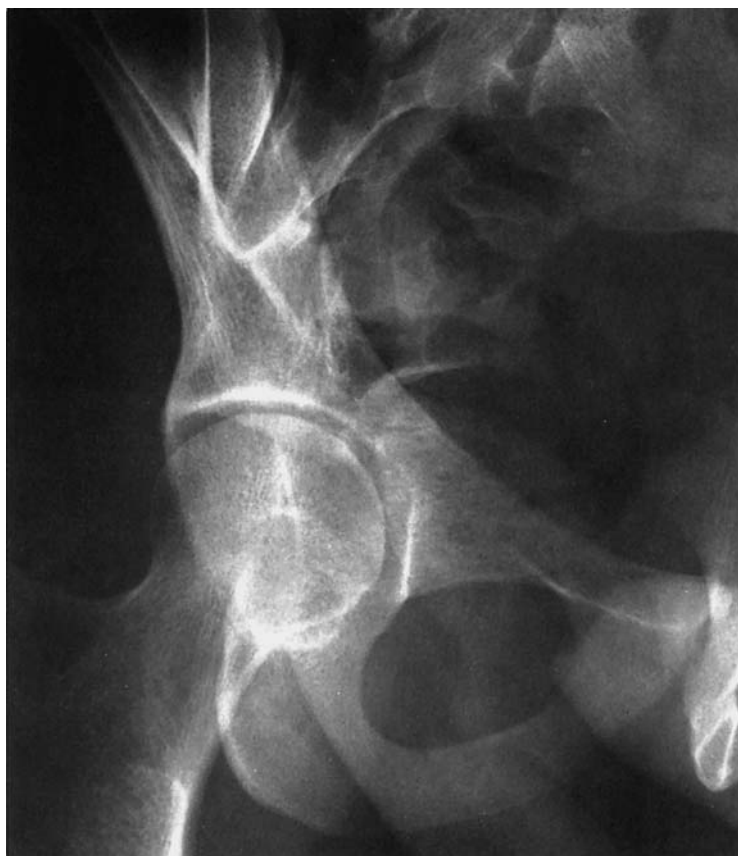

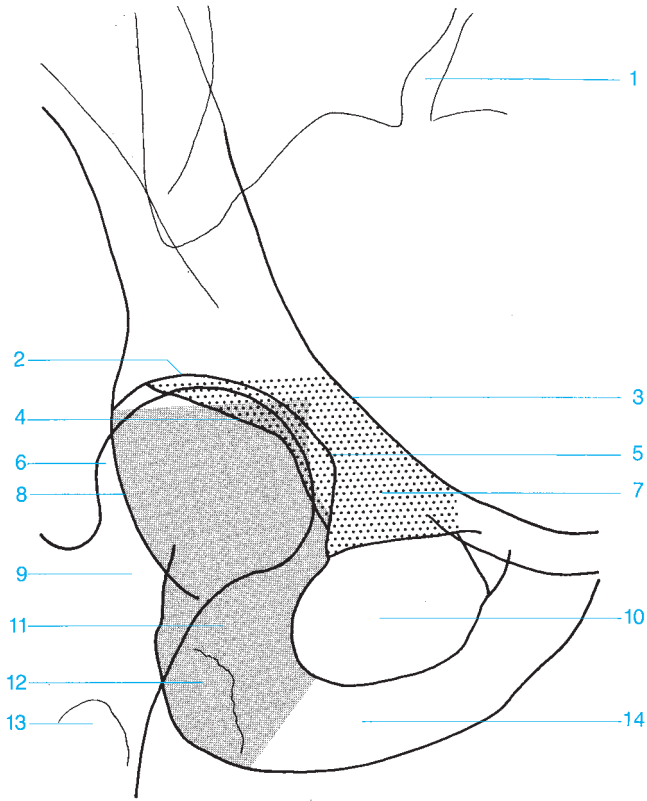
- | | |
|--|--------------------------------|
| 1 Promontory | 10 Superior pubic ramus |
| 2 Iliac crest | 11 Pubic symphysis |
| 3 Anterior superior iliac spine | 12 Obturator foramen |
| 4 Sacrum | 13 Coccyx |
| 5 Anterior inferior iliac spine | 14 Inferior pubic ramus |
| 6 Greater sciatic notch | 15 Body of the ischium |
| 7 Joint space of the hip | 16 Ischial tuberosity |
| 8 Femoral head | 17 Femur |
| 9 Spine of the ischium | |



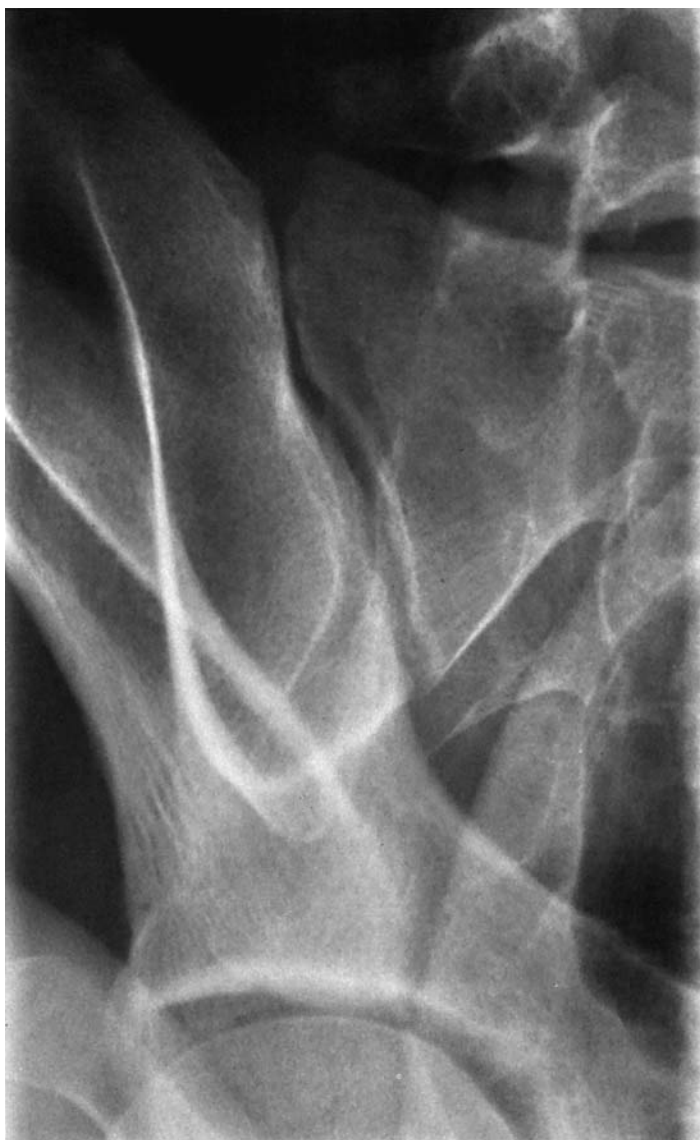

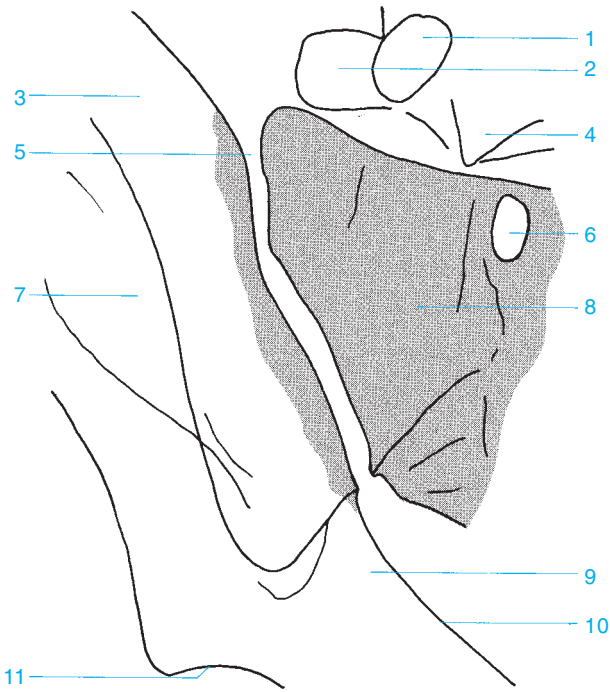
- | | |
|--|--|
| 1 Iliac crest | 10 Spine of the ischium |
| 2 Sacroiliac joint | 11 Femoral head |
| 3 Iliac wing | 12 Posterior acetabular rim |
| 4 Sacrum | 13 Greater trochanter |
| 5 Anterior superior iliac spine | 14 Pubic bone (anterior column) |
| 6 Anterior inferior iliac spine | 15 Ischium (posterior column) |
| 7 Roof of the acetabulum | 16 Obturator foramen |
| 8 Floor of the acetabulum | |
| 9 Anterior acetabular rim | |





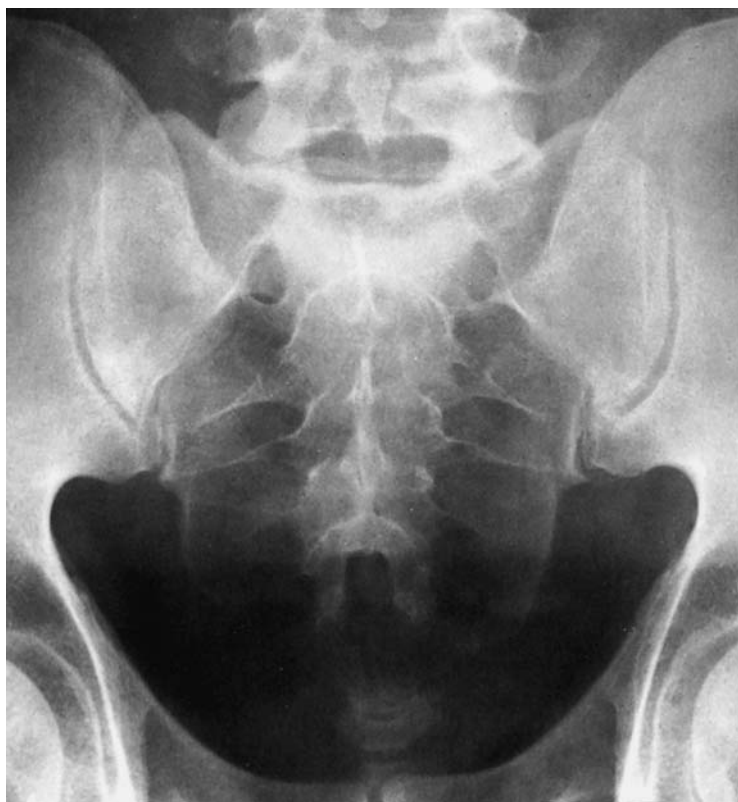- | | |
|--------------------------------|-------------------------------|
| 1 Sacroiliac joint | 8 Posterior acetabular rim |
| 2 Roof of the acetabulum | 9 Femoral neck |
| 3 Ilipectineal line | 10 Obturator foramen |
| 4 Anterior acetabular rim | 11 Ischium (posterior column) |
| 5 Anterior acetabular floor | 12 Ischial tuberosity |
| 6 Femoral head | 13 Lesser trochanter |
| 7 Pubic bone (anterior column) | 14 Inferior pubic ramus |

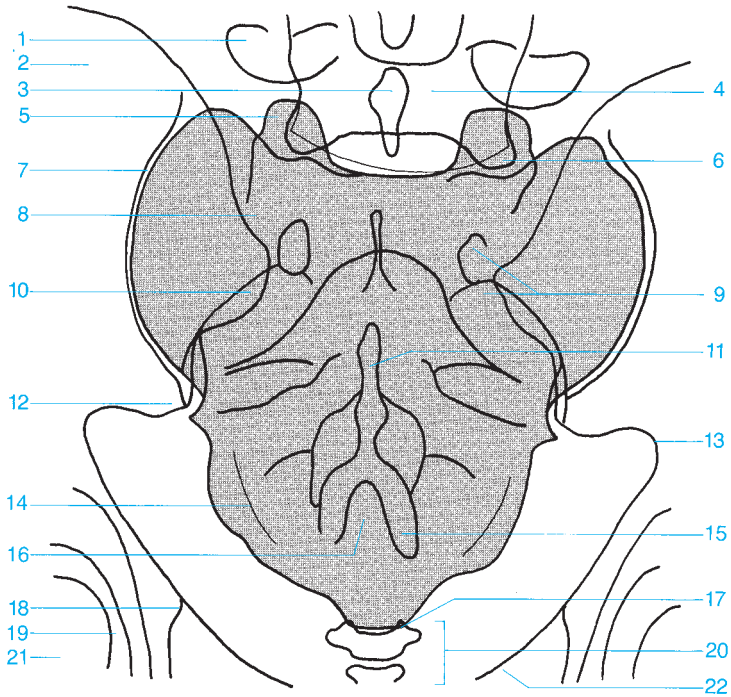




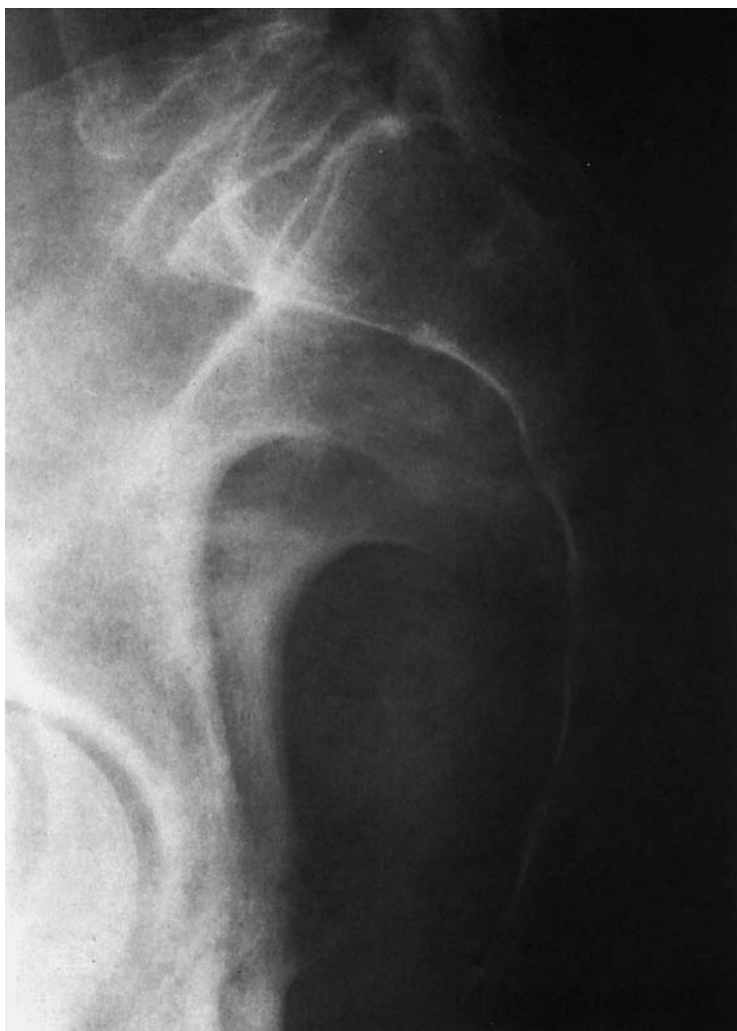- 1 Pedicle of L5
- 2 Transverse process of L5
- 3 Iliac wing
- 4 Body of vertebra L5
- 5 Sacroiliac joint
- 6 Sacral foramen

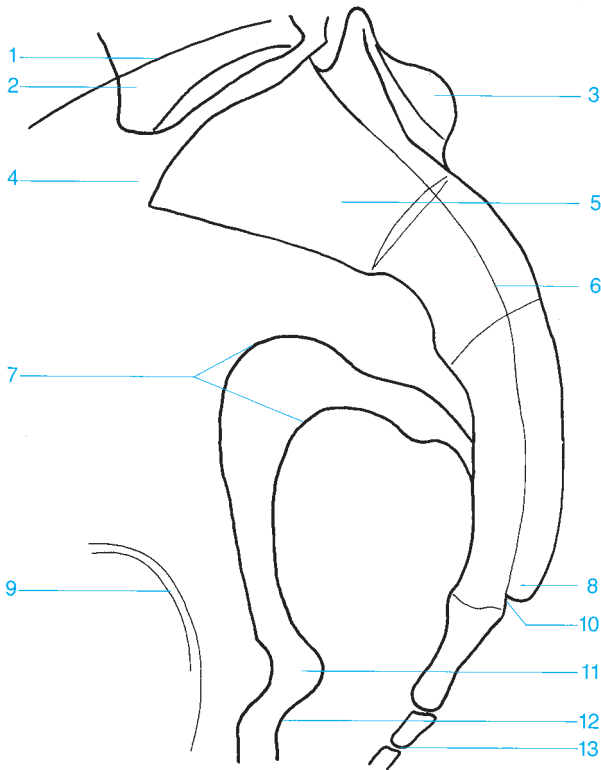
- 7 Iliac wing
- 8 Lateral part of the sacrum
- 9 Ilium
- 10 Arcuate line
- 11 Roof of the acetabulum





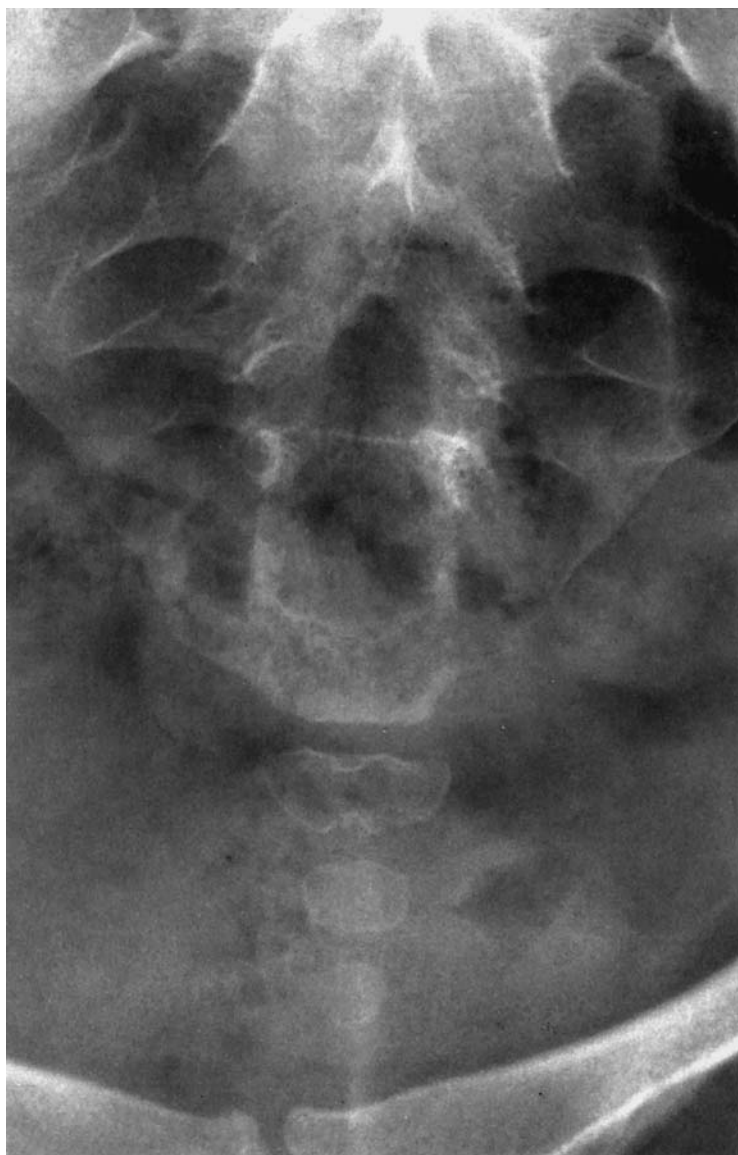
- | | |
|------------------------------------|-----------------------------------|
| 1 Transverse process | 12 Posterior inferior iliac spine |
| 2 Iliac wing | 13 Greater sciatic notch |
| 3 Spinous process | 14 Lateral sacral crest |
| 4 L5 | 15 Cornu of the sacrum |
| 5 Superior articular process | 16 Sacral hiatus |
| 6 Inferior articular process of L5 | 17 Cornu of the coccyx |
| 7 Sacroiliac joint | 18 Spine of the ischium |
| 8 Sacral ala | 19 Hip |
| 9 Sacral foramina | 20 Coccyx |
| 10 Posterior superior iliac spine | 21 Femoral head |
| 11 Median sacral crest | 22 Superior pubic ramus |

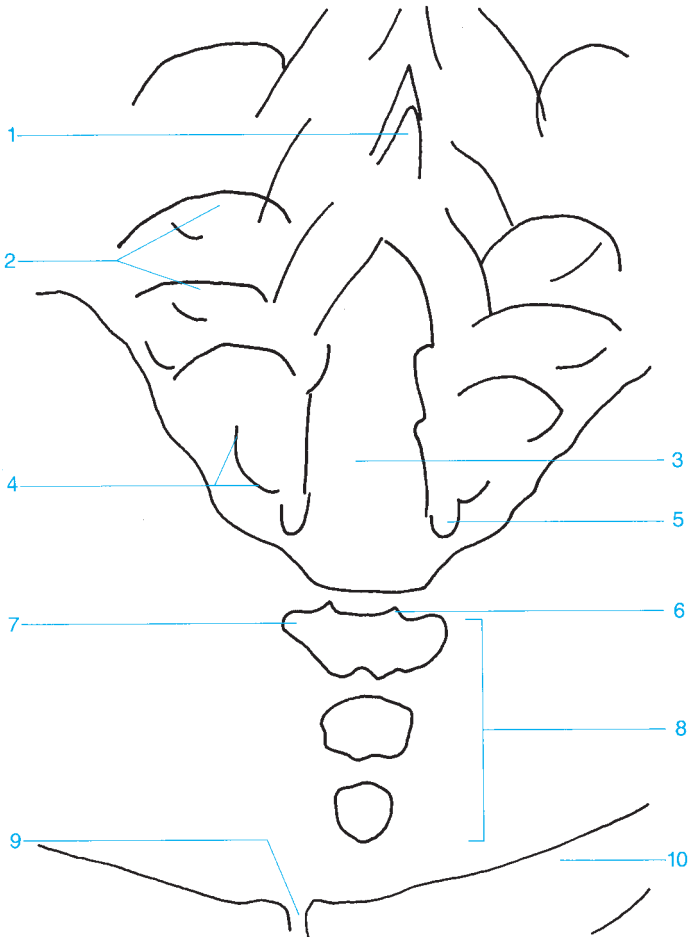




- 1 Iliac crest
- 2 L5
- 3 Median sacral crest
- 4 Promontory
- 5 Sacrum
- 6 Sacral canal
- 7 Greater sciatic notch

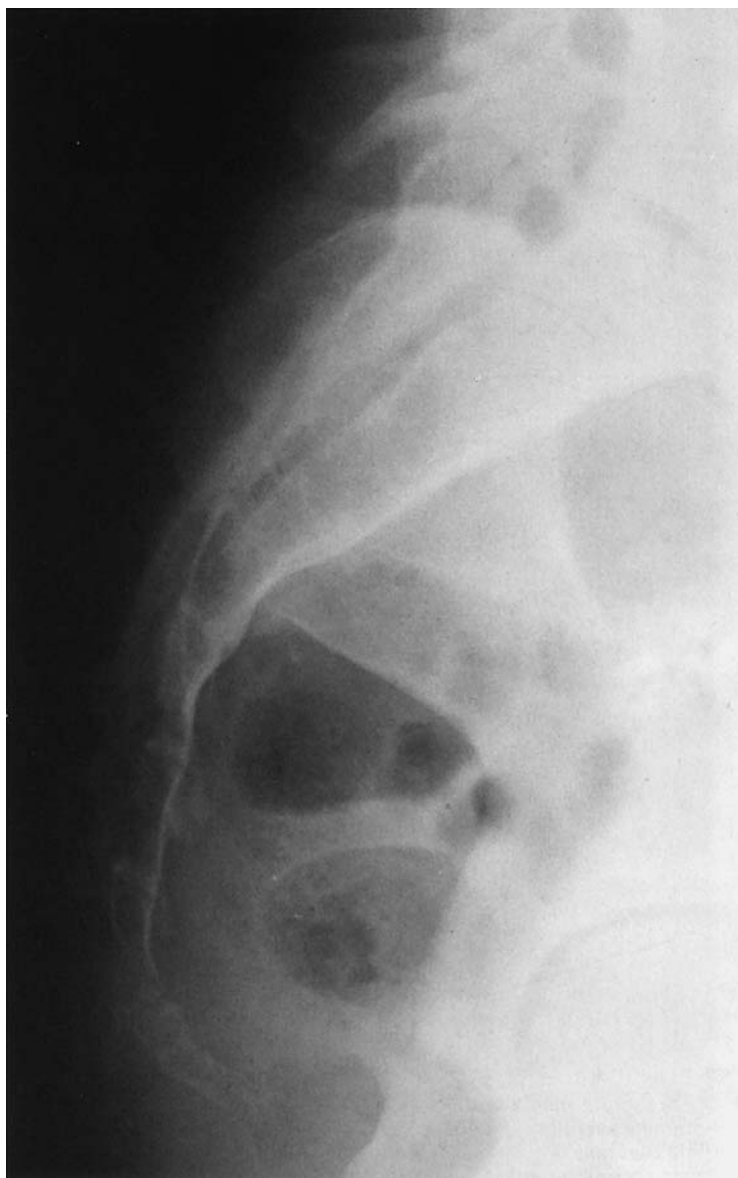
- 8 Cornu of the sacrum
- 9 Hip
- 10 Sacral canal
- 11 Spine of the ischium
- 12 Lesser sciatic notch
- 13 Coccyx

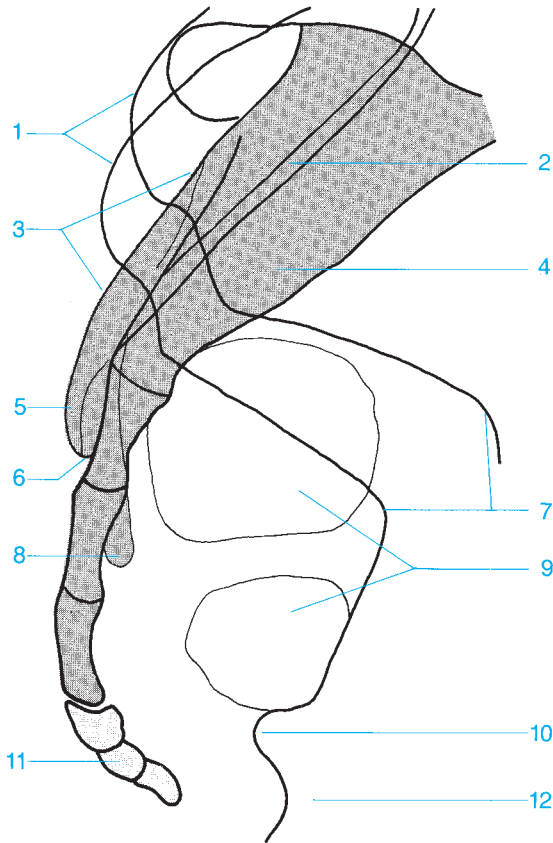




- 1 Median sacral crest
- 2 Sacral foramina
- 3 Sacral hiatus
- 4 Lateral sacral crest
- 5 Cornu of the sacrum

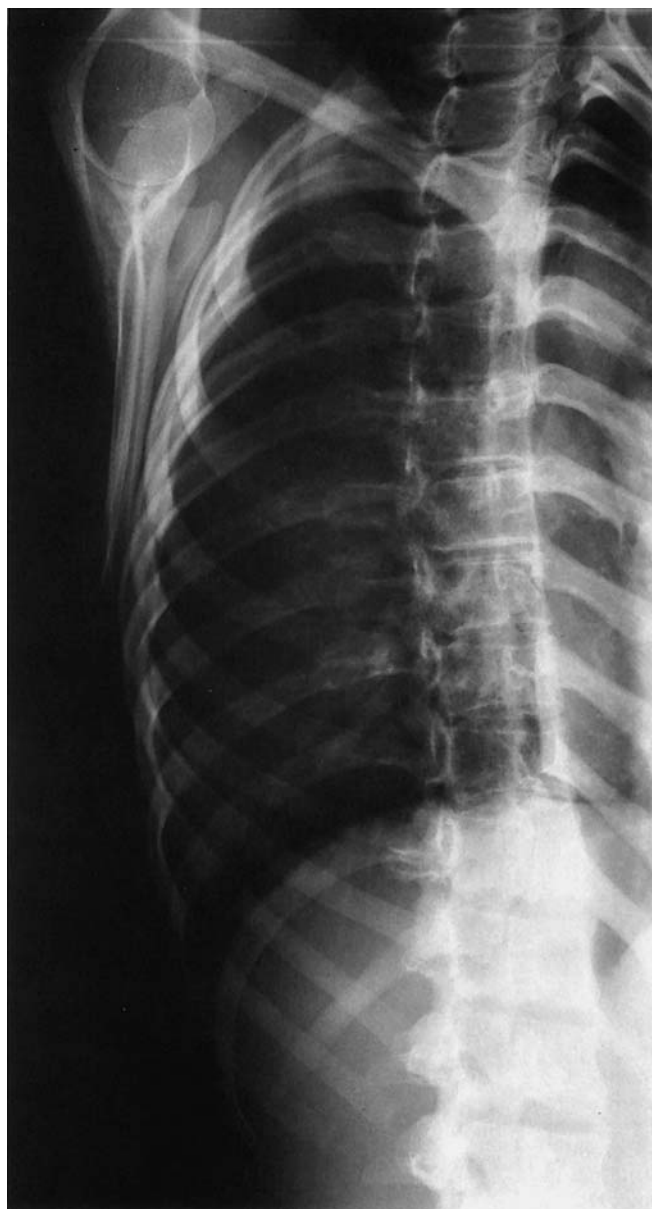- 6 Cornu of the coccyx
- 7 Transverse process
- 8 Coccyx
- 9 Pubic symphysis
- 10 Superior pubic ramus

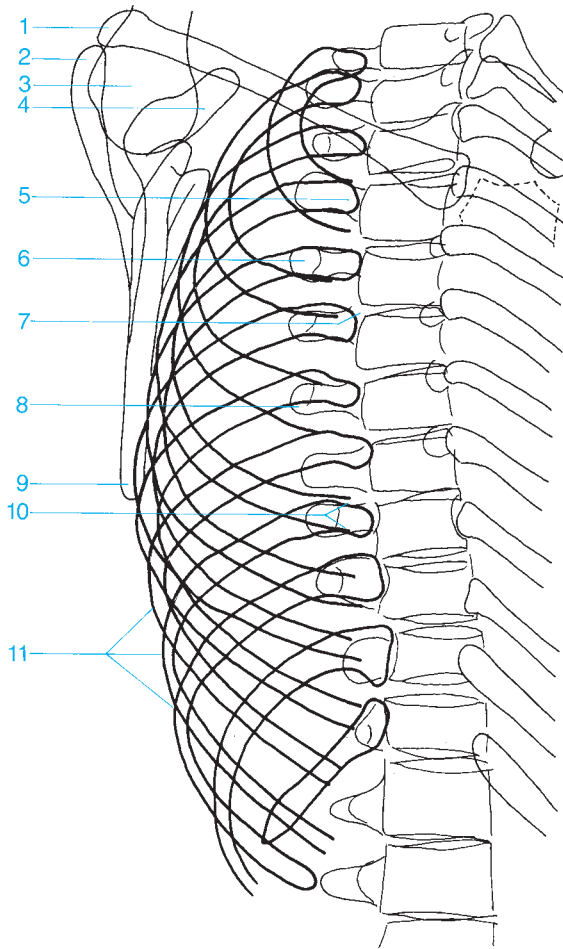




- 1 Iliac crest
- 2 Sacral canal
- 3 Median sacral crest
- 4 Sacrum
- 5 Cornu of the sacrum
- 6 Sacral canal

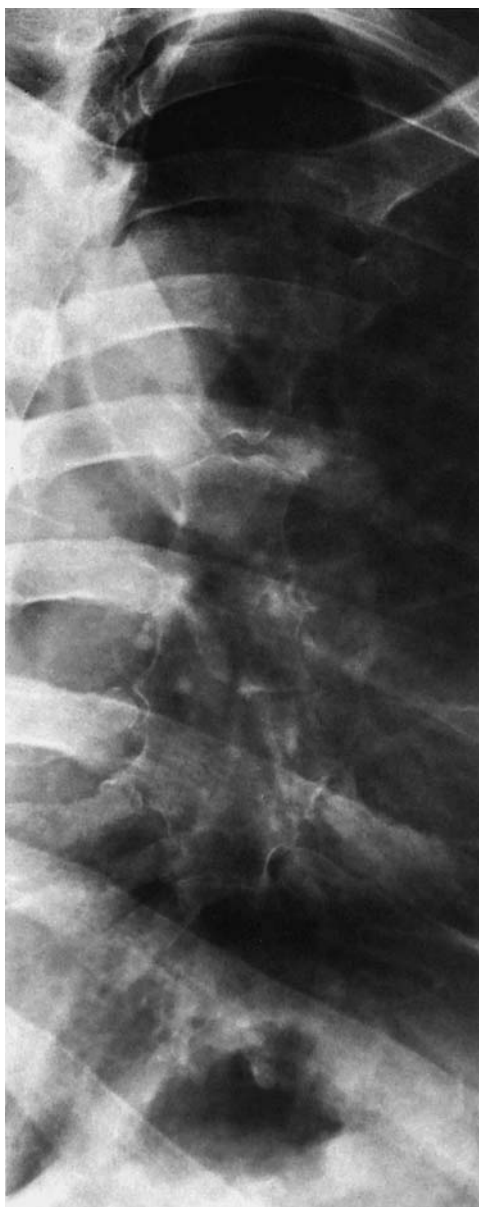- 7 Greater sciatic notch
- 8 Lateral sacral crest
- 9 Rectal gas
- 10 Spine of the ischium
- 11 Coccyx
- 12 Ischium

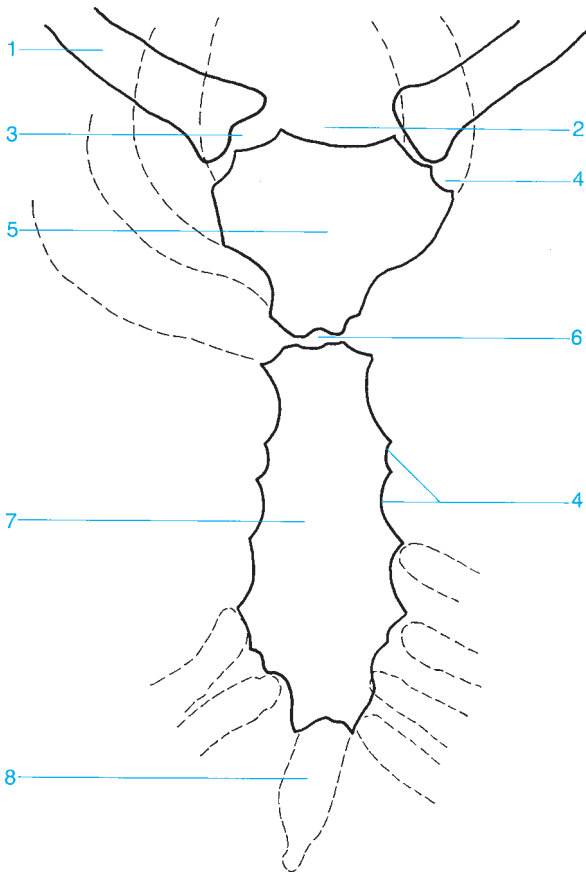




- 1 Clavicle (distal end)
- 2 Acromion
- 3 Humeral head
- 4 Coracoid process
- 5 Head of the rib
- 6 Costotransverse joint

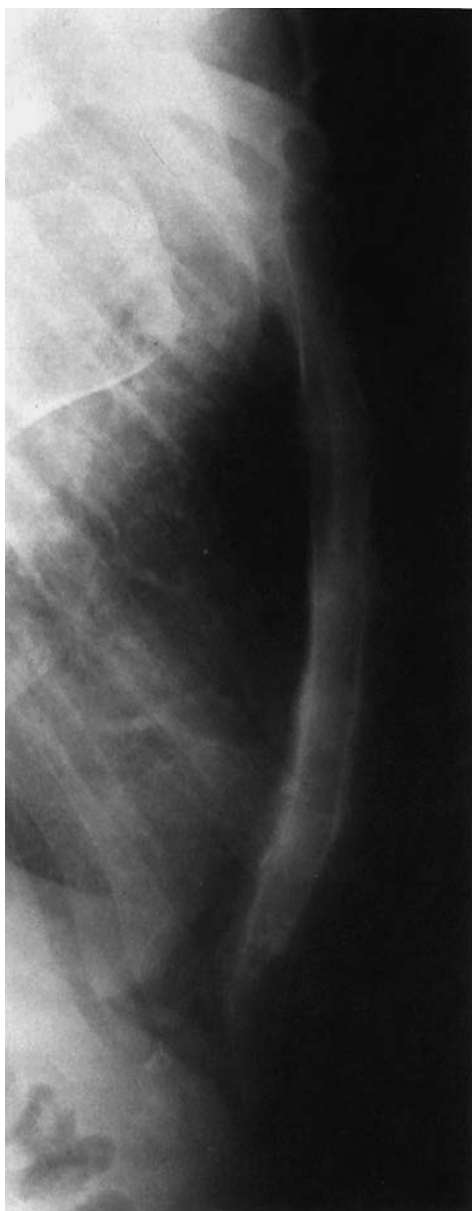
- 7 Costovertebral articulation
- 8 Transverse process
- 9 Inferior angle of the scapula
- 10 Neck of the rib
- 11 Costal arch

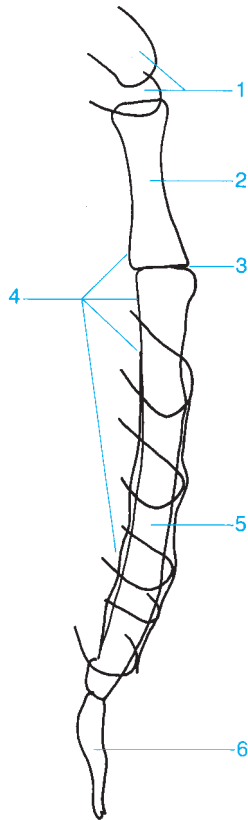




- 1 Clavicle
- 2 Sternal notch
- 3 Sternoclavicular joint
- 4 Costal notch

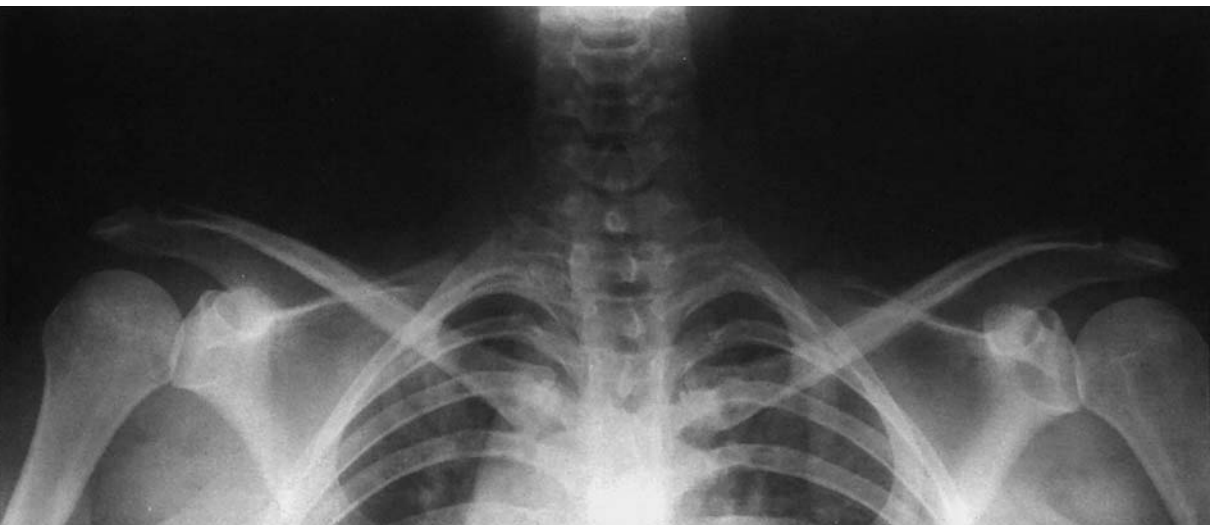- 5 Manubrium of the sternum
- 6 Sternal angle
- 7 Body of the sternum
- 8 Xiphoid process





- 1 Clavicles
- 2 Manubrium of the sternum
- 3 Sternal angle

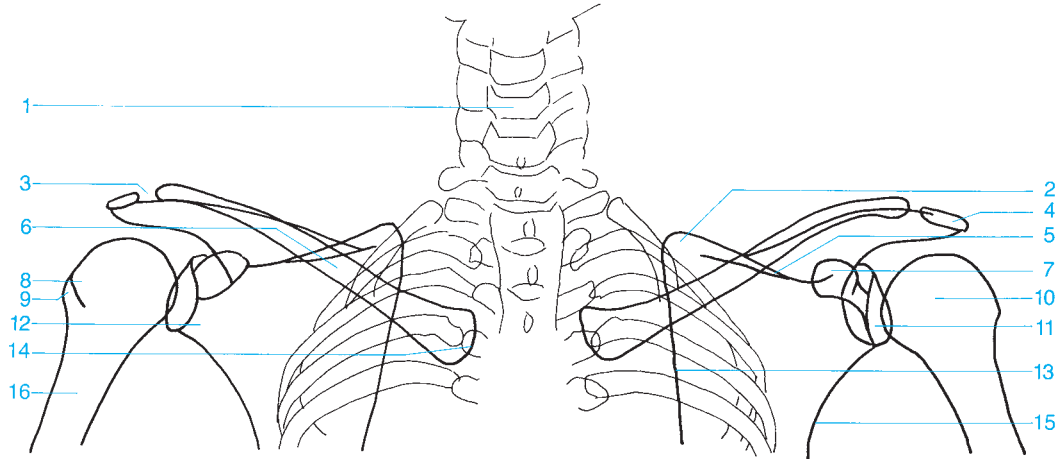
- 4 Retrosternal space
- 5 Body of the sternum
- 6 Xiphoid process

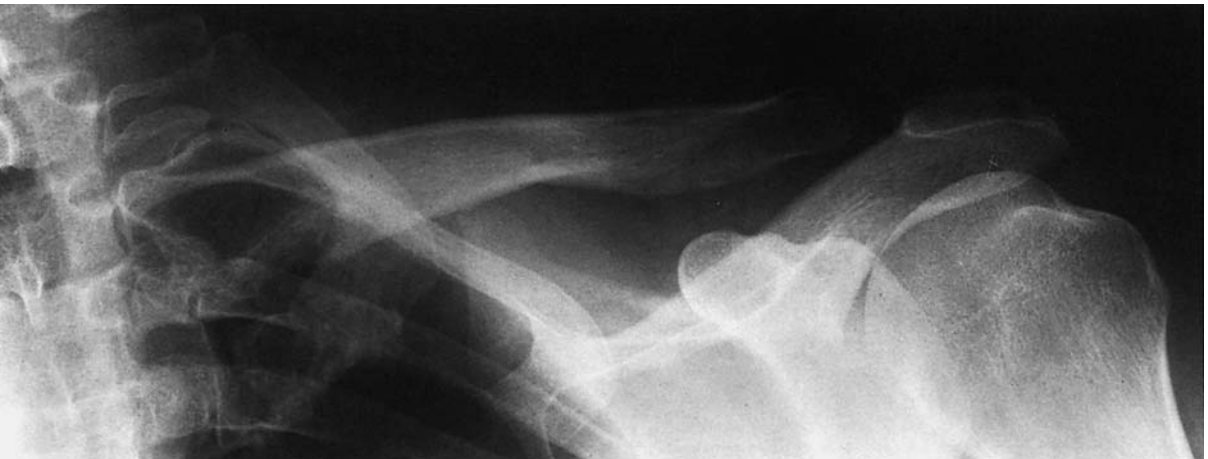

- 1 Cervical spine
- 2 Superior angle of the scapula
- 3 Acromioclavicular joint
- 4 Acromion
- 5 Spine of the scapula
- 6 Clavicle

- 7 Coracoid
- 8 Lesser tubercle of the humerus
- 9 Greater tubercle of the humerus
- 10 Humeral head
- 11 Glenoid fossa (articular surface)
- 12 Glenoid process of the scapula

- 13 Medial margin of the scapula
- 14 Proximal clavicle
- 15 Lateral margin of the scapula
- 16 Humerus

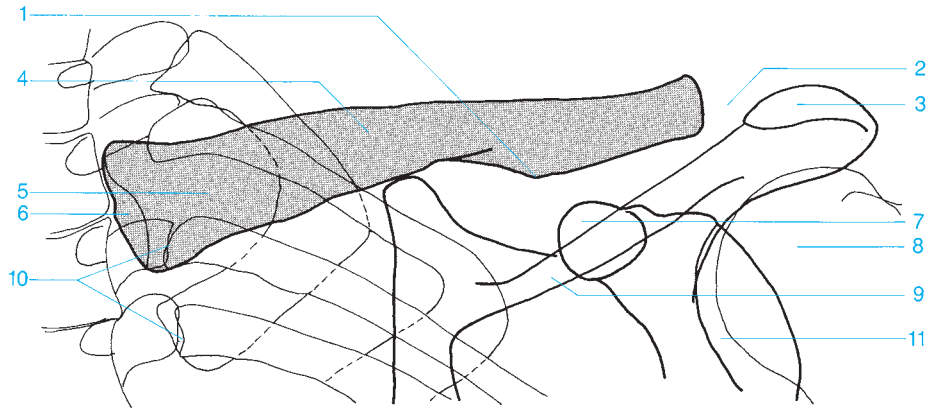


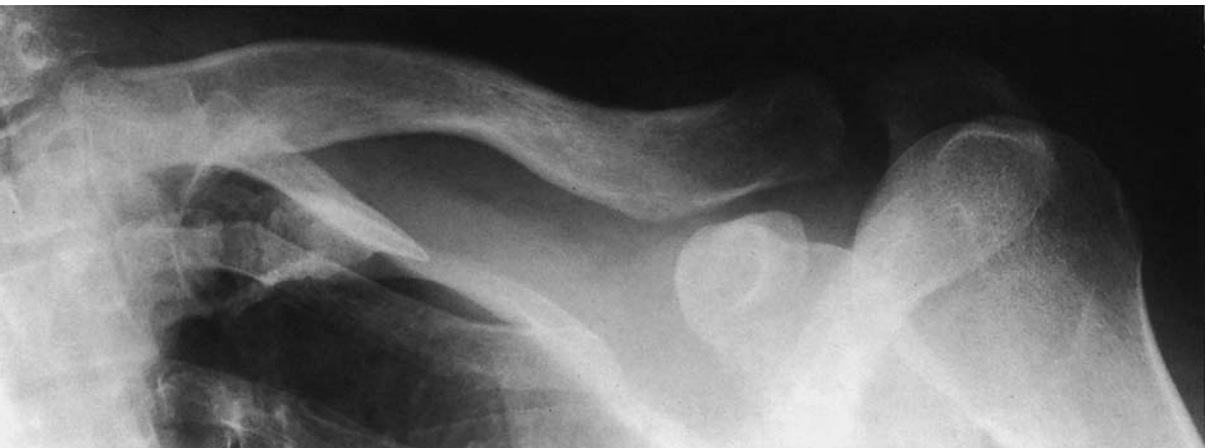

- 1 Conoid tubercle of the clavicle
- 2 Acromioclavicular joint
- 3 Acromion
- 4 Clavicle

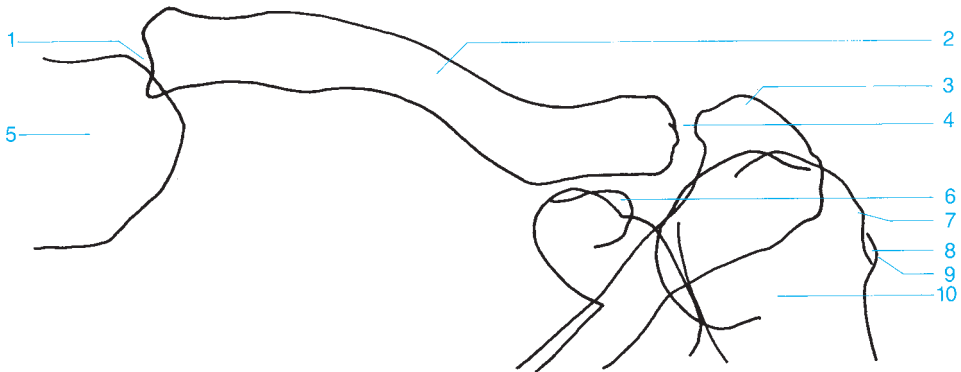
- 5 Superior angle of the scapula
- 6 Proximal clavicle
- 7 Coracoid process
- 8 Humeral head

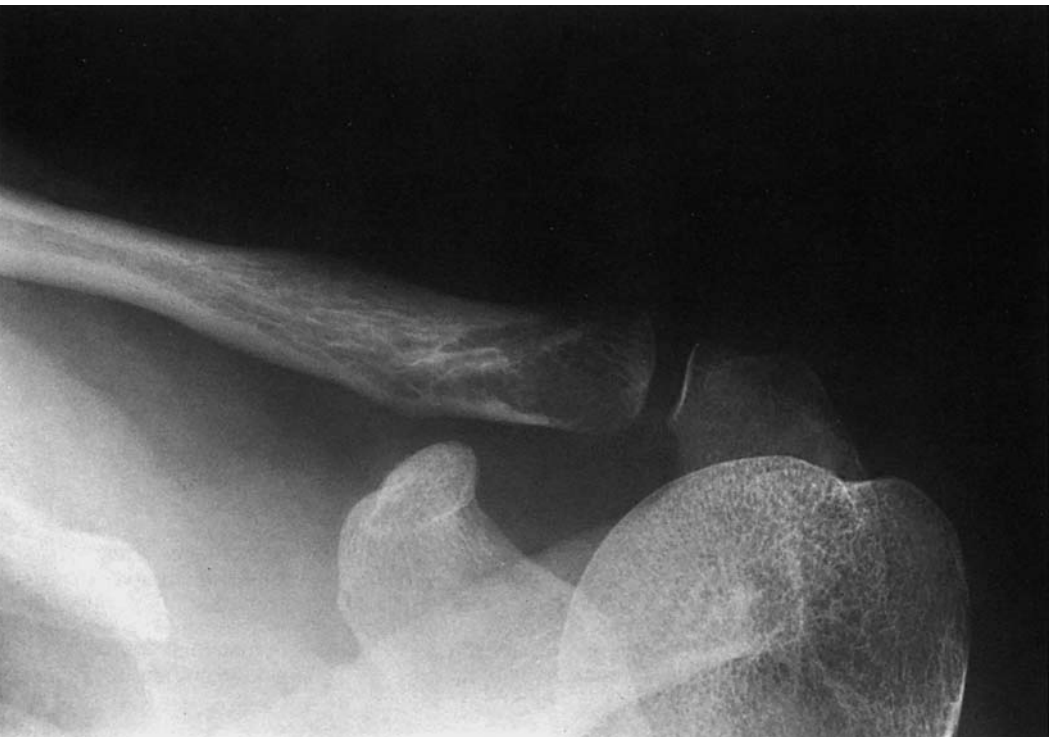- 9 Spine of the scapula
- 10 Costoclavicular joint
- 11 Glenoid fossa





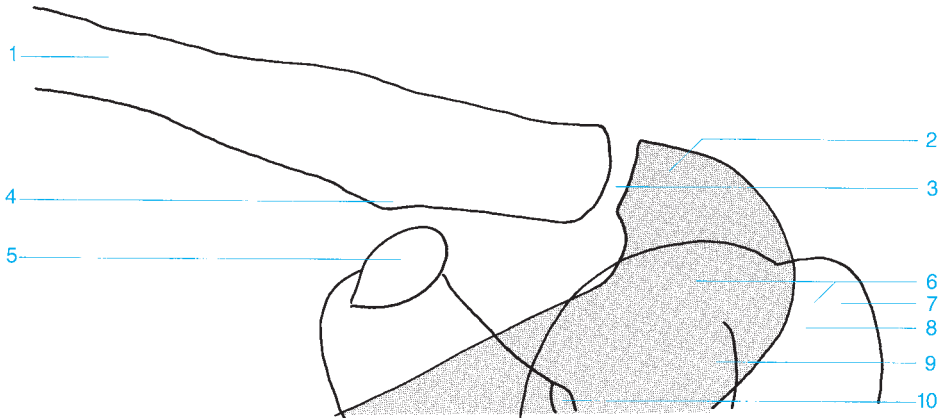
- | | |
|---------------------------|-----------------------------------|
| 1 Sternoclavicular joint | 6 Coracoid process |
| 2 Clavicle | 7 Greater tubercle of the humerus |
| 3 Acromion | 8 Bicipital groove |
| 4 Acromioclavicular joint | 9 Lesser tubercle of the humerus |
| 5 Sternum (manubrium) | 10 Humeral head |

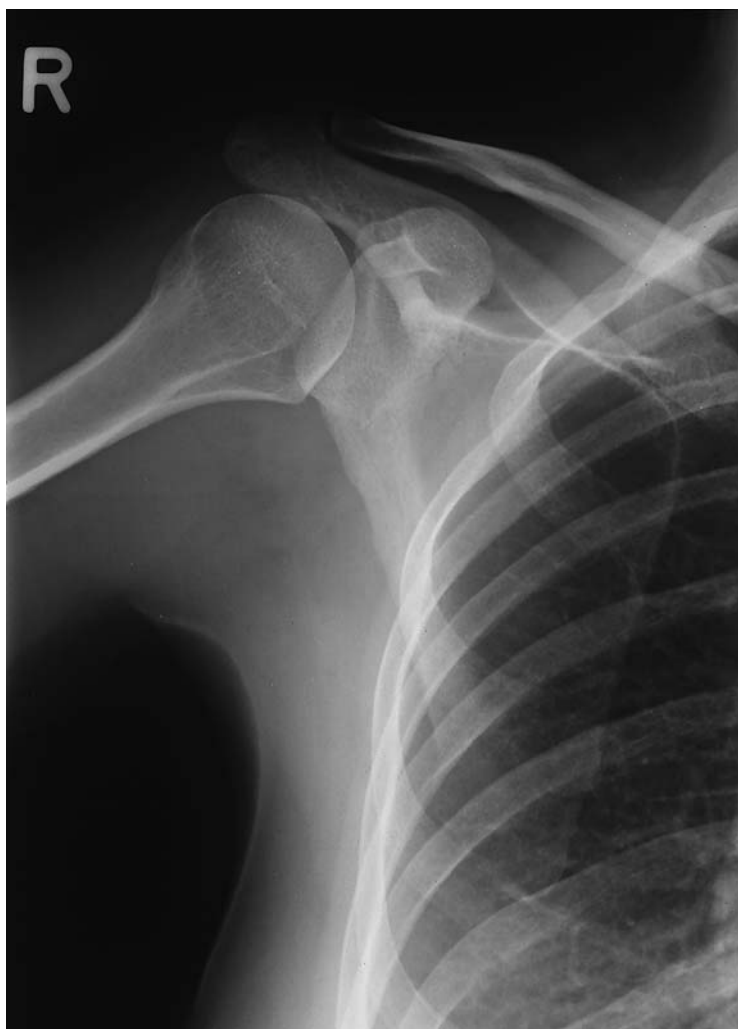

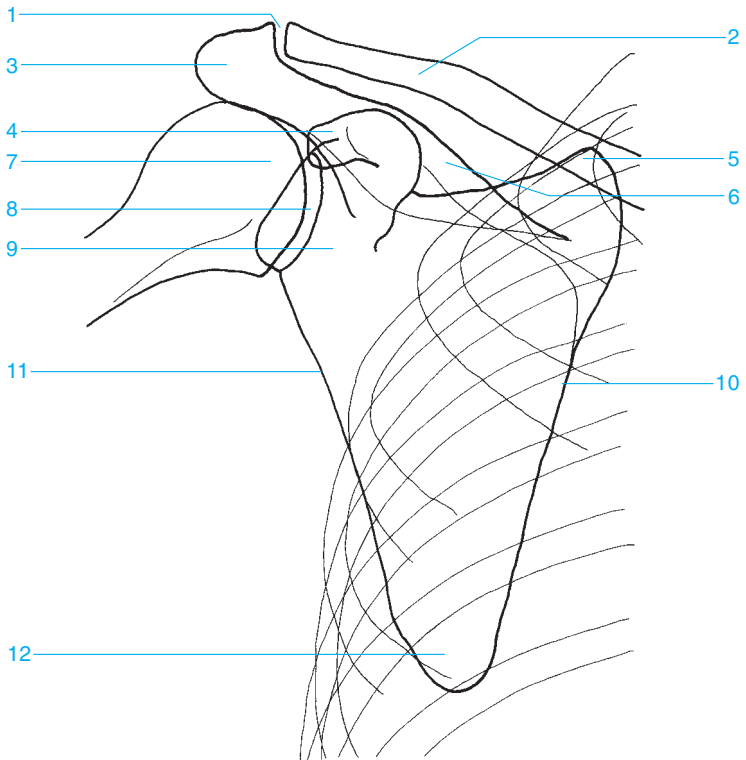


- 1 Clavicle
- 2 Acromion
- 3 Acromioclavicular joint
- 4 Conoid tubercle of the clavicle
- 5 Coracoid process

- 6 Humeral head
- 7 Greater tubercle of the humerus
- 8 Bicipital groove
- 9 Lesser tubercle of the humerus
- 10 Glenoid fossa







1 Acromioclavicular joint

2 Clavicle

3 Acromion

4 Coracoid process

5 Superior angle

6 Spine of the scapula

7 Humeral head

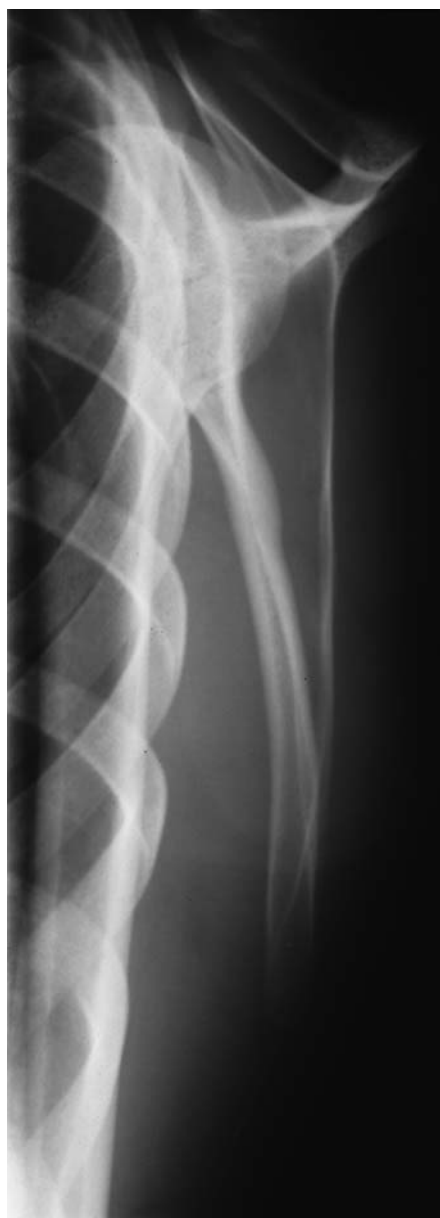8 Articular surface

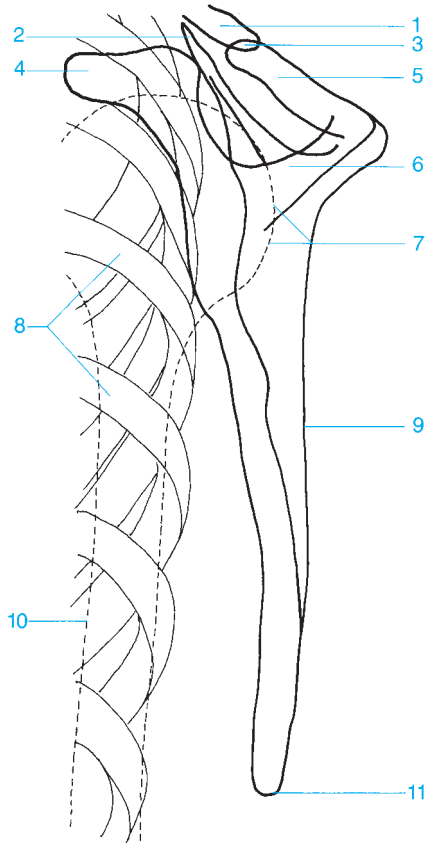
9 Lateral process (neck) of the scapula

10 Medial margin

11 Lateral margin

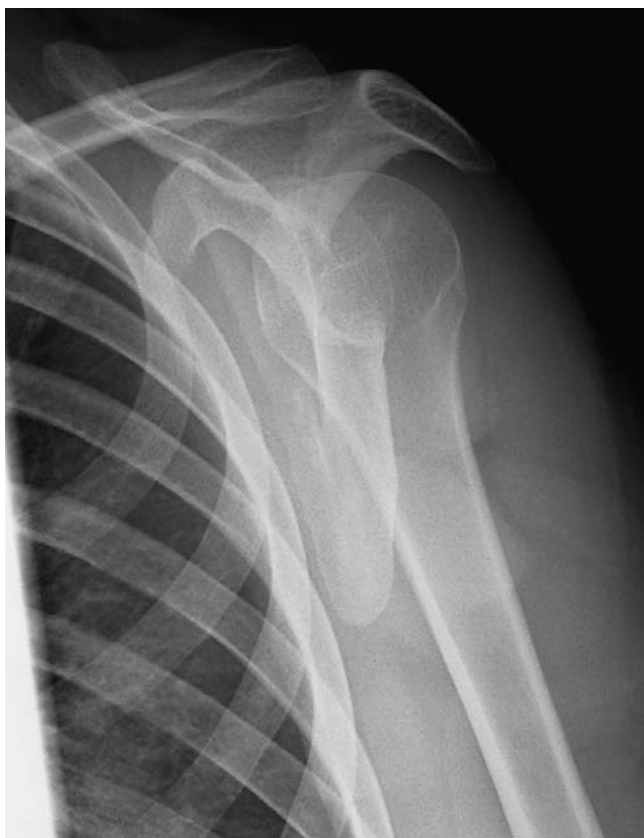12 Inferior angle

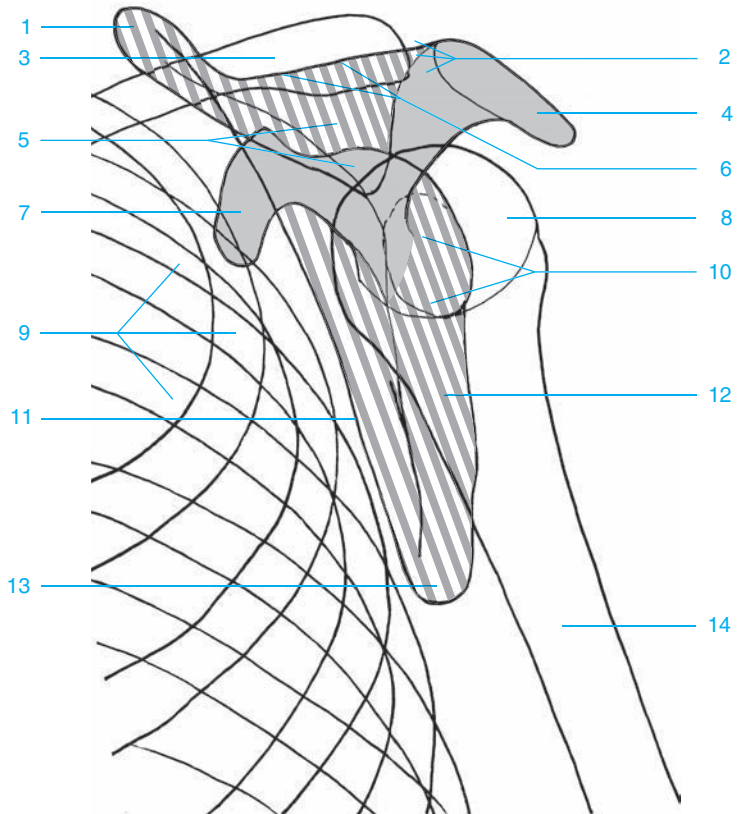




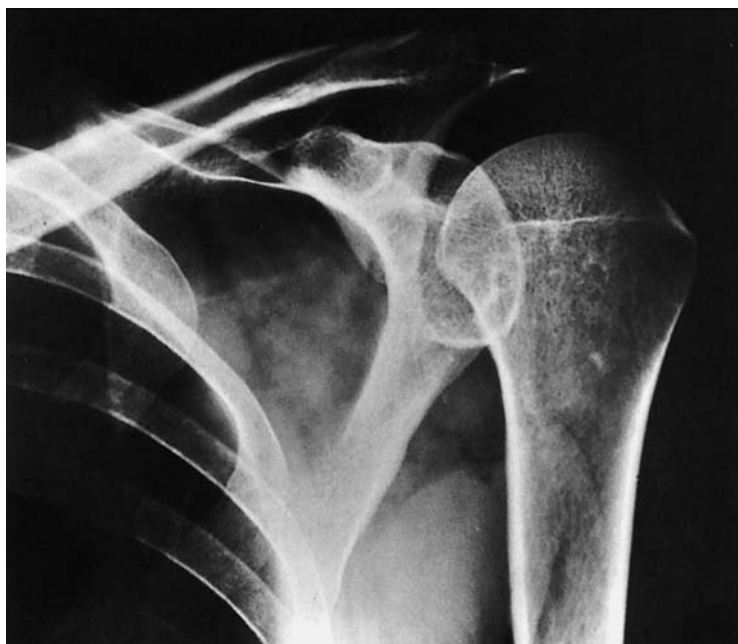- 1 Distal clavicle
- 2 Superior angle of the scapula
- 3 Acromioclavicular joint
- 4 Coracoid process
- 5 Acromion
- 6 Spine of the scapula

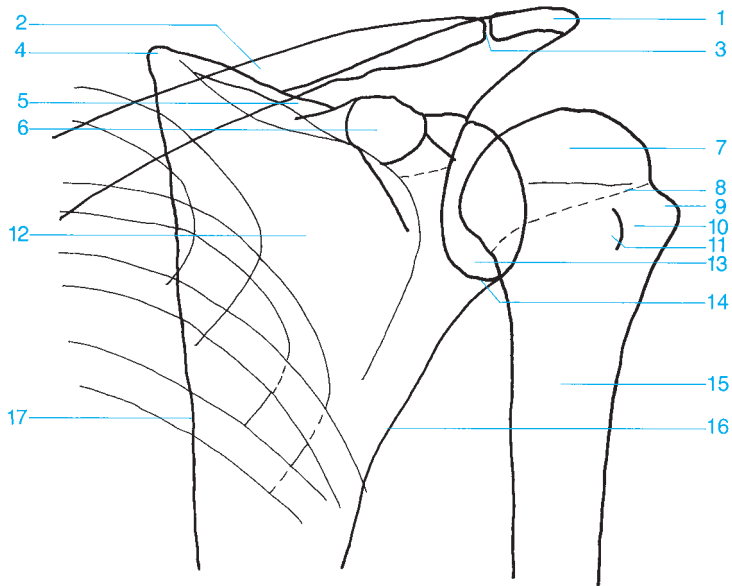
- 7 Humeral head
- 8 Ribs
- 9 Lateral margin of the scapula
- 10 Humeral shaft
- 11 Inferior angle of the scapula



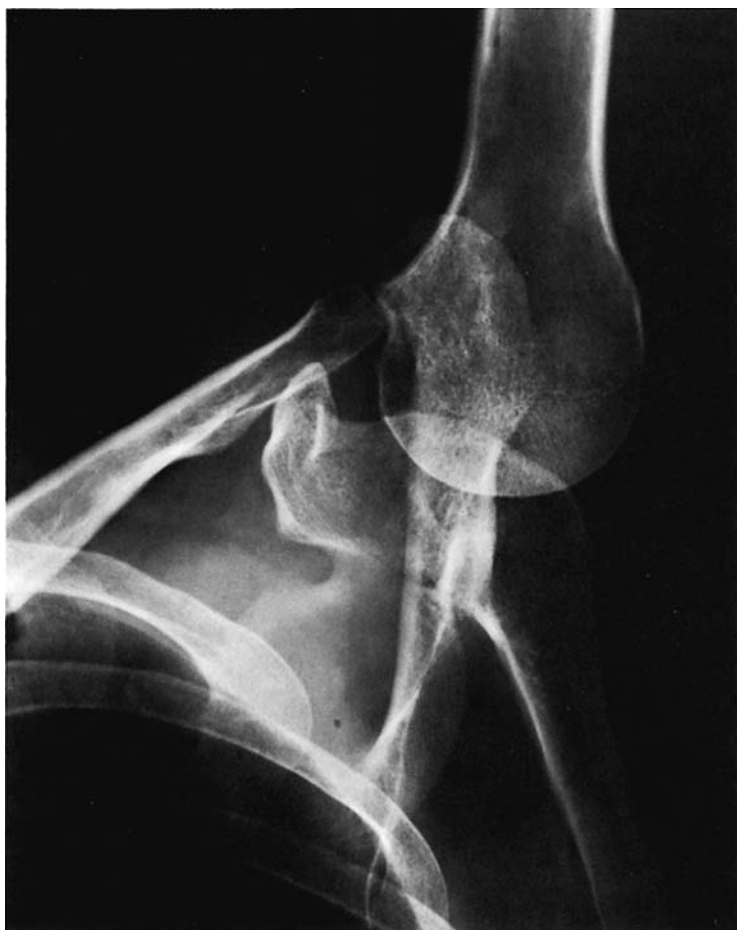

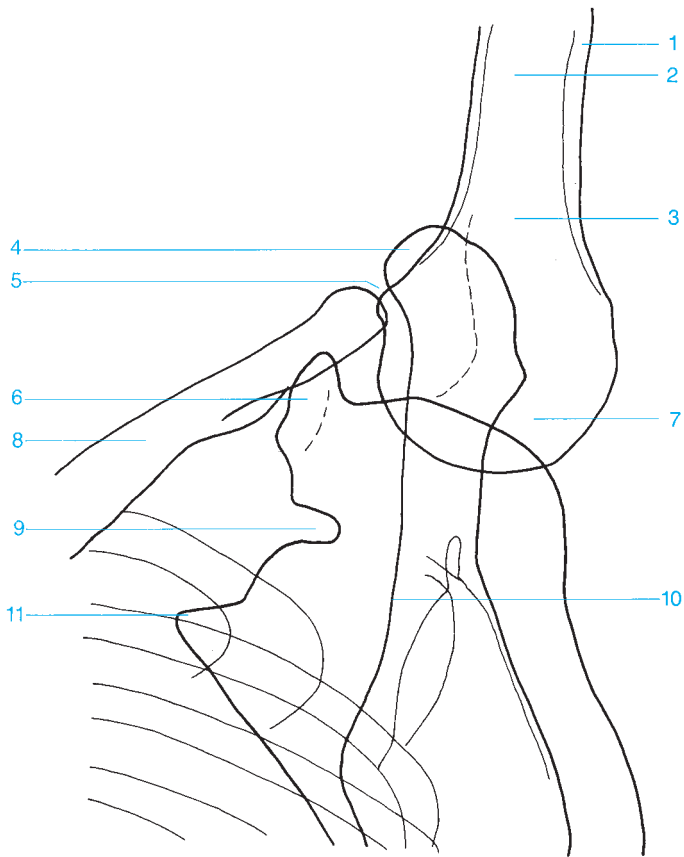
- | | |
|---------------------------------|-------------------------------------|
| 1 Superior angle of the scapula | 8 Humeral head |
| 2 Acromioclavicular joint | 9 Rib |
| 3 Clavicle | 10 Glenoid fossa |
| 4 Acromion | 11 Costal surface of the scapula |
| 5 Supraspinatus fossa | 12 Posterior surface of the scapula |
| 6 Spine of the scapula | 13 Inferior angle of the scapula |
| 7 Coracoid process | 14 Humeral shaft |





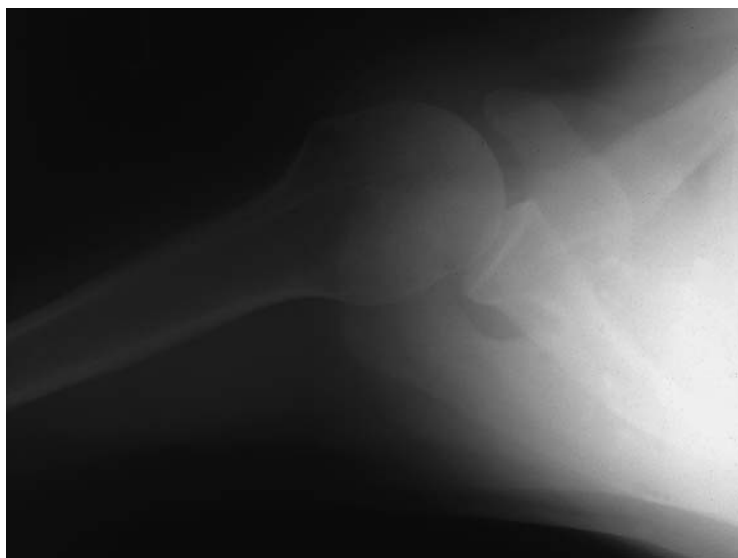
- | | |
|--|--|
| 1 Acromion | 10 Bicipital groove |
| 2 Clavicle | 11 Lesser tubercle of the humerus |
| 3 Acromioclavicular joint | 12 Scapula |
| 4 Superior angle of the scapula | 13 Glenoid fossa |
| 5 Spine of the scapula | 14 Glenoid labrum |
| 6 Coracoid process | 15 Surgical neck |
| 7 Humeral head | 16 Lateral margin of the scapula |
| 8 Anatomical neck | 17 Medial margin of the scapula |
| 9 Greater tubercle of the humerus | |

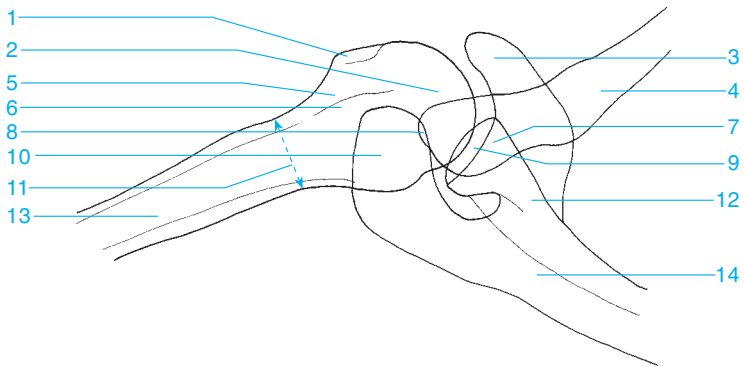




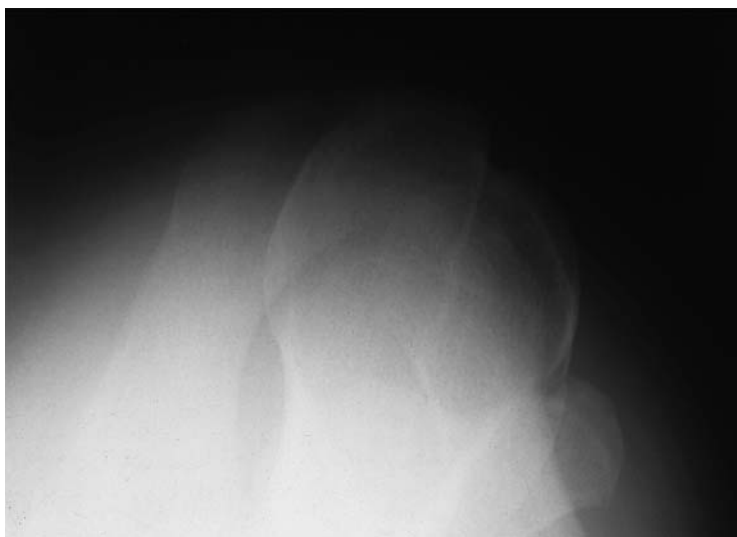- 1 Cortex
- 2 Metaphysis
- 3 Surgical neck
- 4 Acromion
- 5 Acromioclavicular joint
- 6 Coracoid process

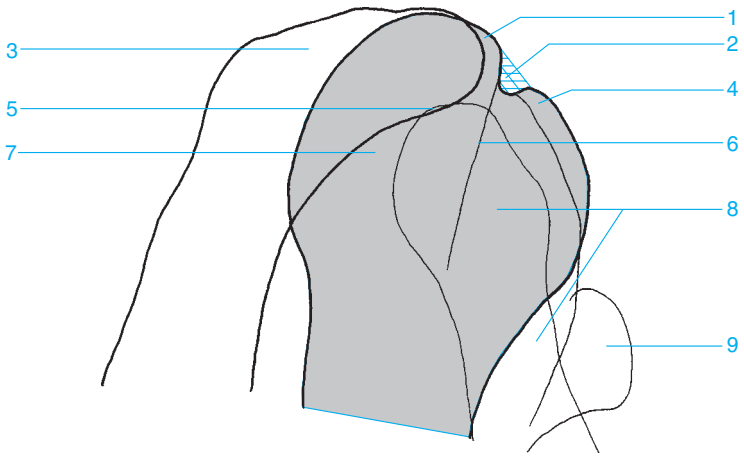
- 7 Humeral head
- 8 Clavicle
- 9 Suprascapular notch
- 10 Spine of the scapula
- 11 Superior angle of the scapula





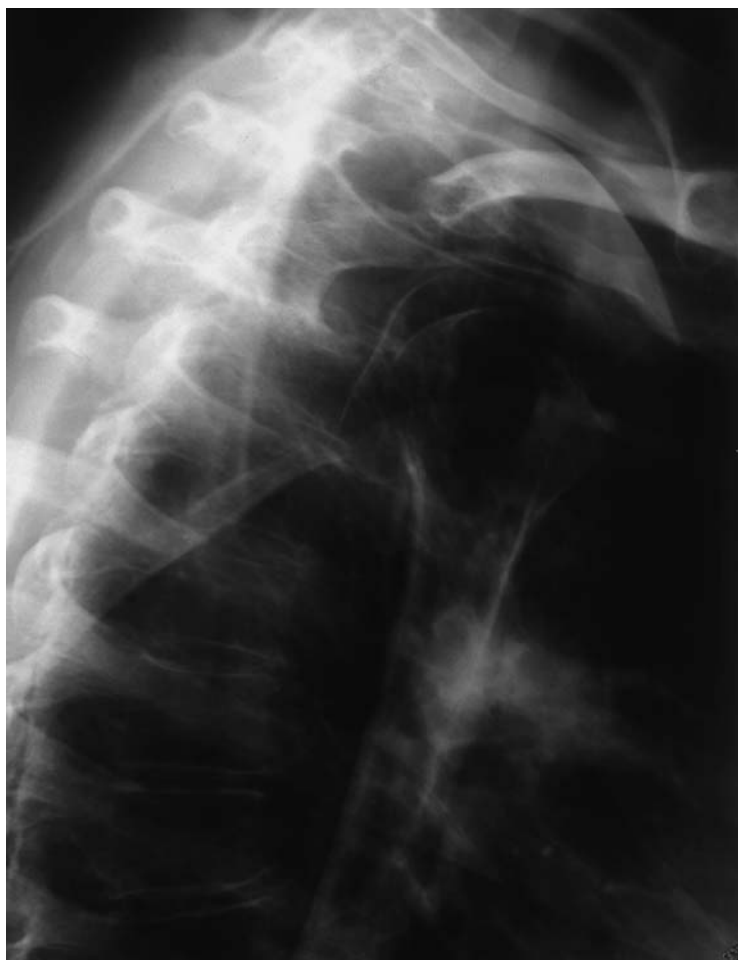- | | |
|-----------------------------------|----------------------------------|
| 1 Lesser tubercle of the humerus | 8 Acromioclavicular joint |
| 2 Humeral head | 9 Glenohumeral joint |
| 3 Coracoid process | 10 Acromion |
| 4 Clavicle | 11 Superior angle of the scapula |
| 5 Bicipital groove | 12 Neck of the scapula |
| 6 Greater tubercle of the humerus | 13 Humerus |
| 7 Glenoid fossa | 14 Scapula |

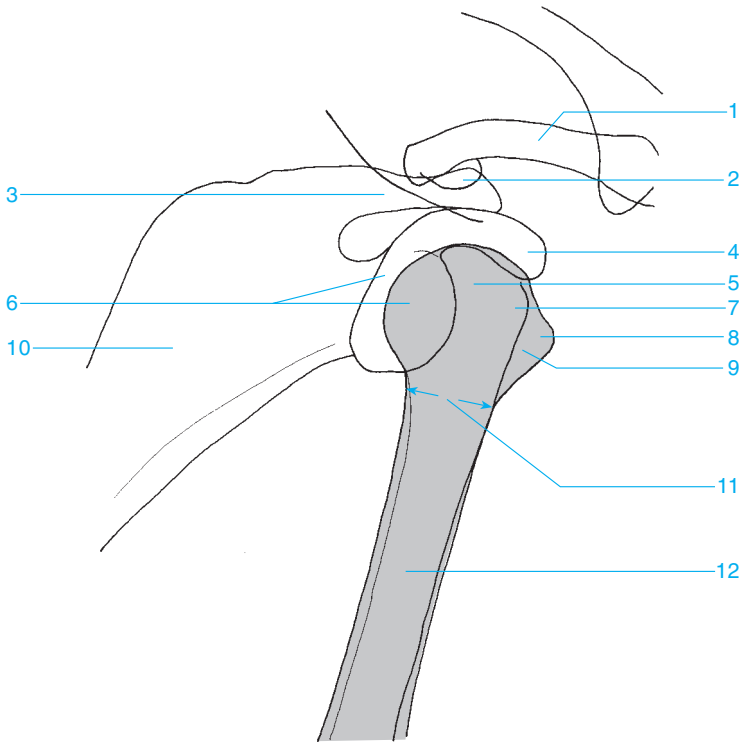




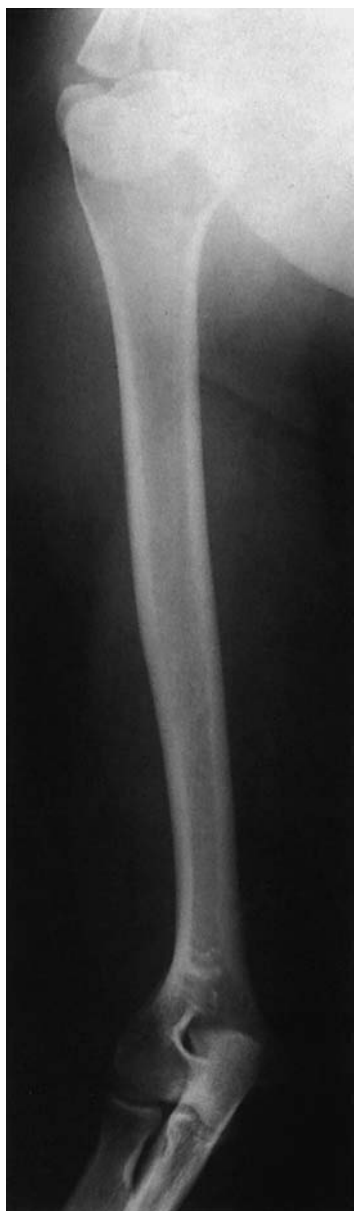- 1 Greater tubercle of the humerus
- 2 Bicipital groove
- 3 Acromion
- 4 Lesser tubercle of the humerus
- 5 Acromioclavicular joint

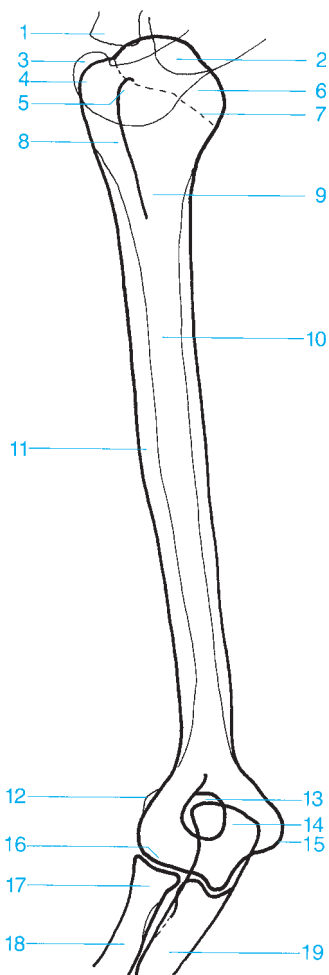
- 6 Crest of the greater tubercle
- 7 Humeral head
- 8 Clavicle
- 9 Coracoid process



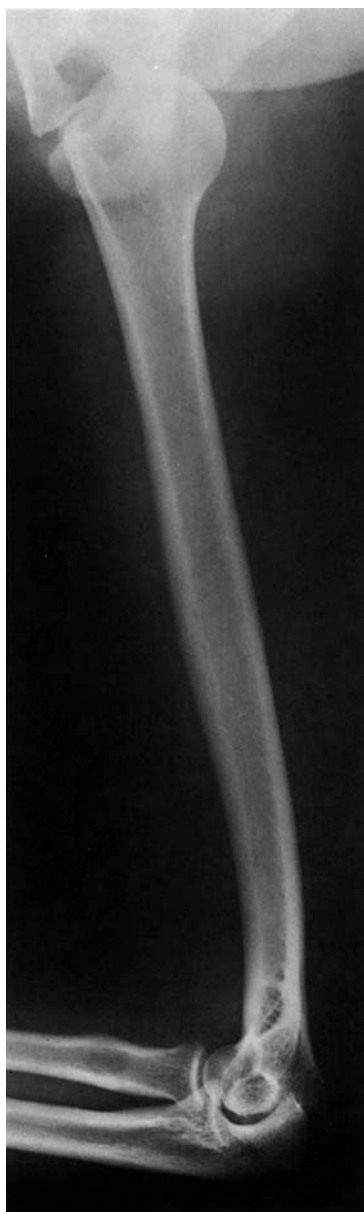

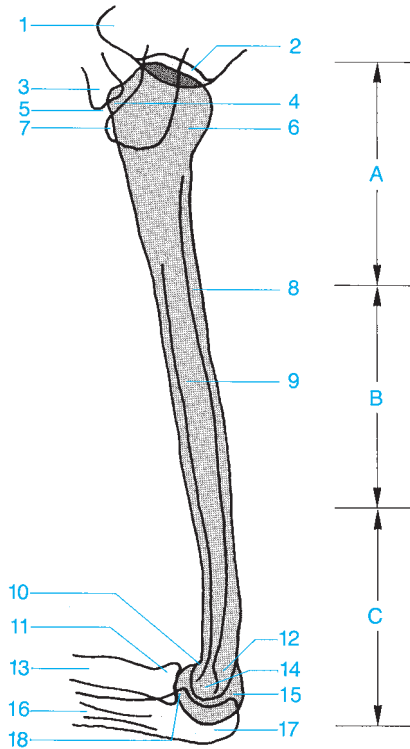
- | | |
|----------------------------------|--|
| 1 Clavicle | 7 Greater tubercle of the humerus |
| 2 Acromioclavicular joint | 8 Lesser tubercle of the humerus |
| 3 Acromion | 9 Bicipital groove |
| 4 Coracoid process | 10 Scapula |
| 5 Humeral head | 11 Surgical neck |
| 6 Glenoid fossa | 12 Humerus |



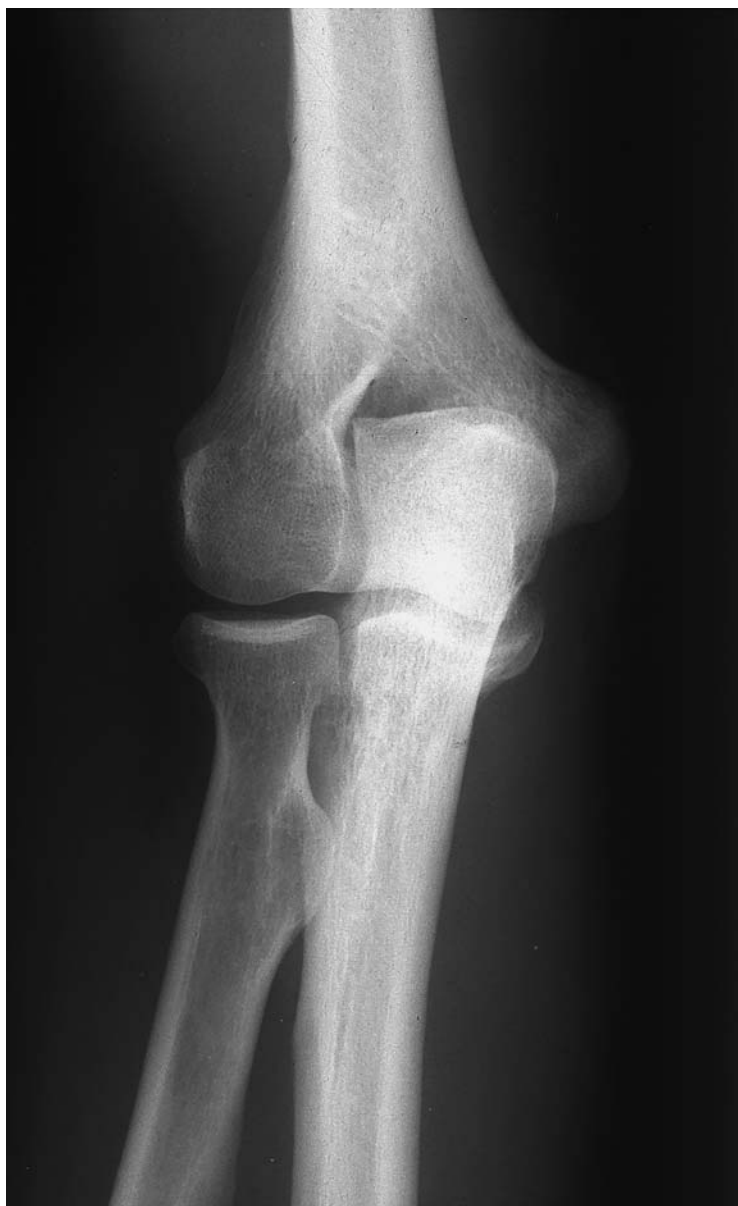

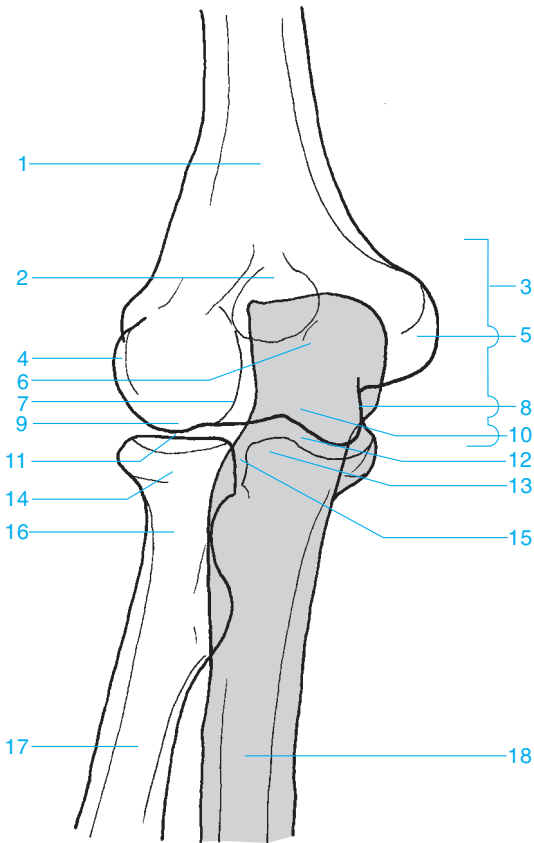
- 1 Clavicle
- 2 Lateral process (neck) of the scapula
- 3 Acromion
- 4 Greater tubercle of the humerus
- 5 Lesser tubercle of the humerus
- 6 Humeral head
- 7 Anatomical neck
- 8 Bicipital groove
- 9 Surgical neck
- 10 Humerus
- 11 Deltoid tuberosity
- 12 Lateral epicondyle
- 13 Olecranon fossa
- 14 Olecranon
- 15 Medial epicondyle
- 16 Trochlea
- 17 Radial head
- 18 Radius
- 19 Ulna



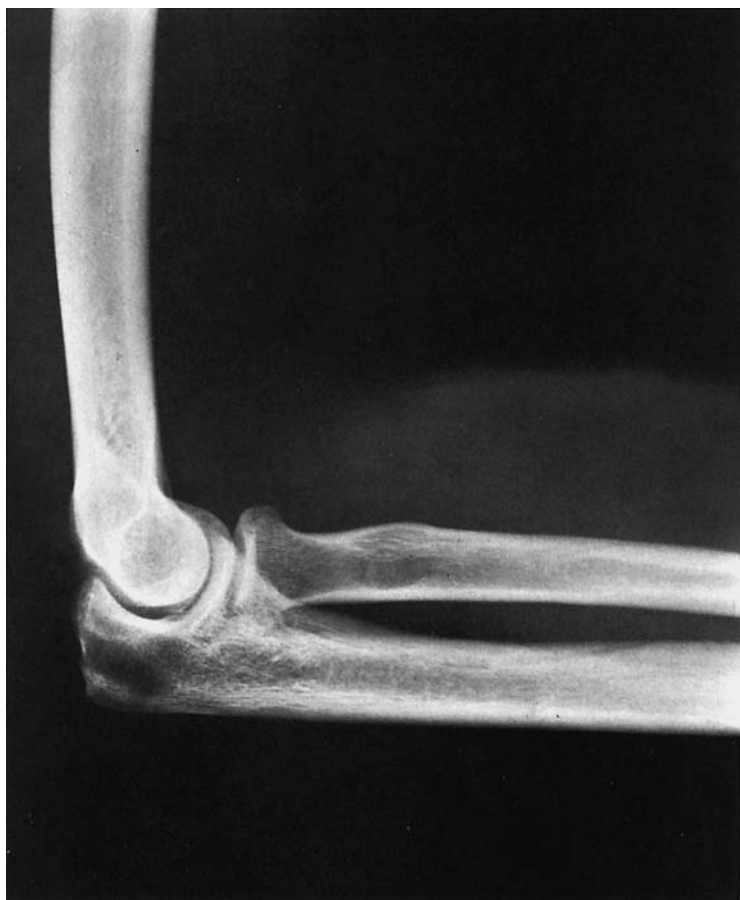

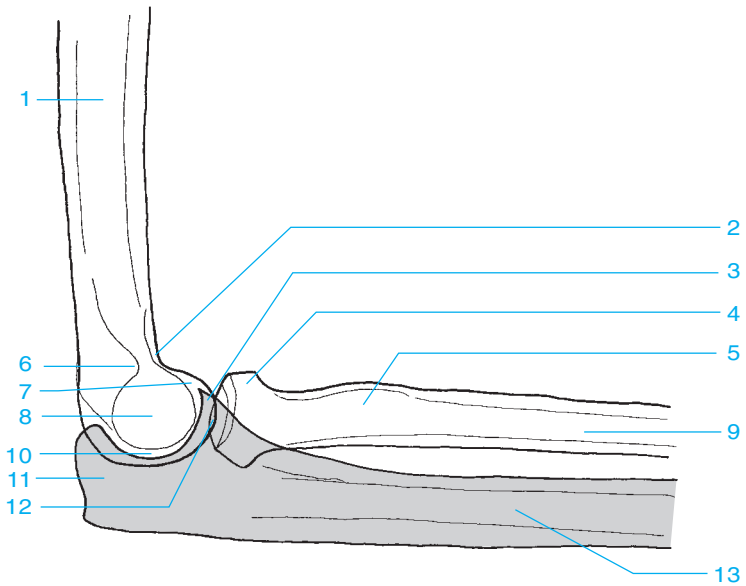
- | | |
|---|----------------------------|
| A Proximal third of the humerus | 9 Humeral shaft |
| B Medial third of the humerus | 10 Coronoid fossa |
| C Distal third of the humerus | 11 Radial head |
| 1 Coracoid process | 12 Olecranon fossa |
| 2 Glenoid fossa | 13 Radius |
| 3 Clavicle | 14 Trochlea |
| 4 Lesser tubercle of the humerus | 15 Capitellum |
| 5 Acromioclavicular joint | 16 Ulna |
| 6 Humeral head | 17 Olecranon |
| 7 Acromion | 18 Coronoid process |
| 8 Cortex | |



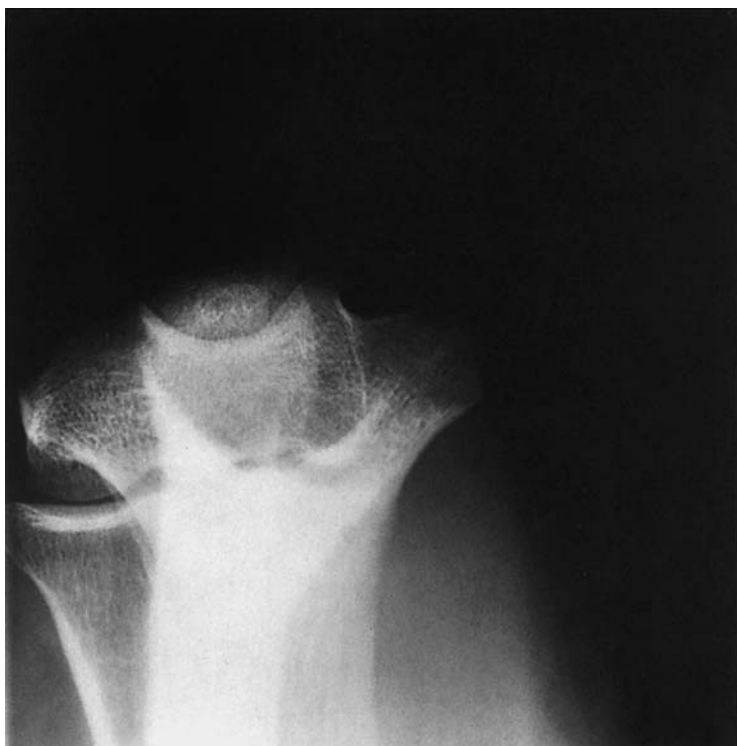

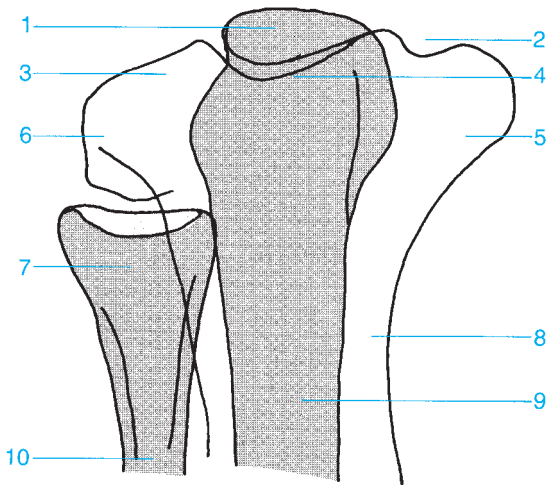
- | | |
|---|-------------------------------------|
| 1 Humerus | 10 Trochlea |
| 2 Olecranon fossa | 11 Humeroradial joint |
| 3 Medial epicondyle of the humerus | 12 Humeroulnar joint |
| 4 Lateral epicondyle of the humerus | 13 Coronoid process |
| 5 Apex of the medial epicondyle of the humerus | 14 Radial head |
| 6 Olecranon | 15 Proximal radioulnar joint |
| 7 Lateral margin of the trochlea | 16 Radial neck |
| 8 Medial margin of the trochlea | 17 Radius |
| 9 Capitellum | 18 Ulna |





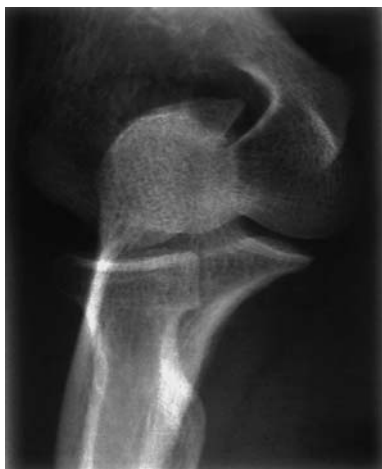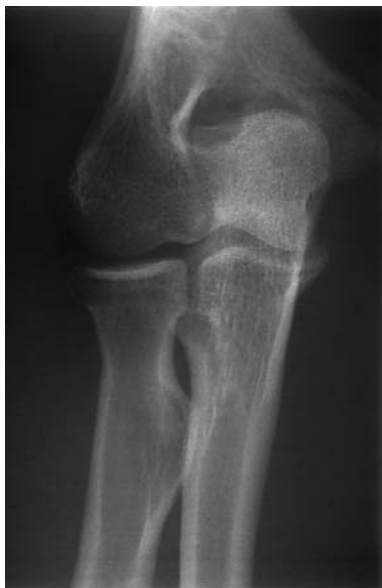- | | |
|---------------------|-----------------------|
| 1 Humerus | 8 Lateral epicondyle |
| 2 Coronoid fossa | 9 Radius |
| 3 Coronoid process | 10 Humeroulnar joint |
| 4 Radial head | 11 Olecranon |
| 5 Radial tuberosity | 12 Humeroradial joint |
| 6 Olecranon fossa | 13 Ulna |
| 7 Medial epicondyle | |

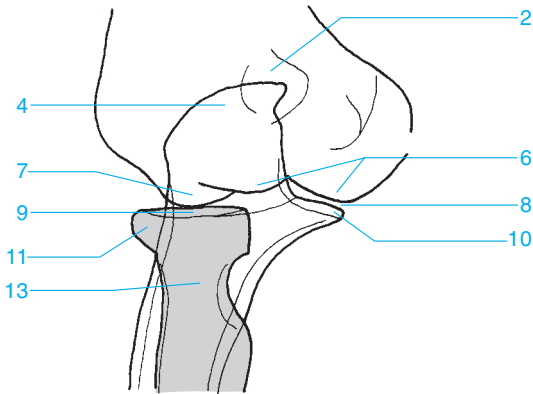
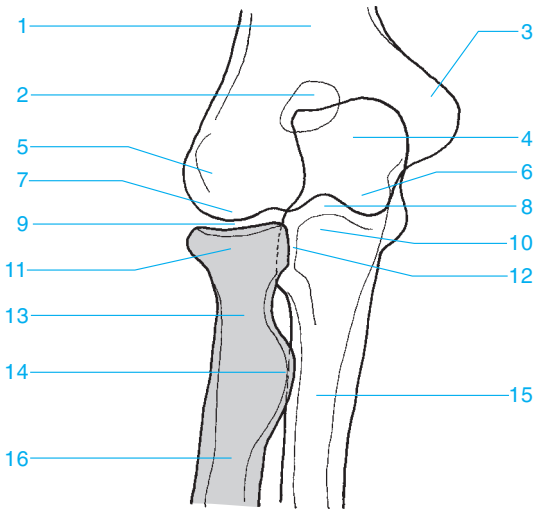




- 1** Olecranon
- 2** Cubital tunnel
- 3** Capitellum
- 4** Trochlea
- 5** Medial epicondyle

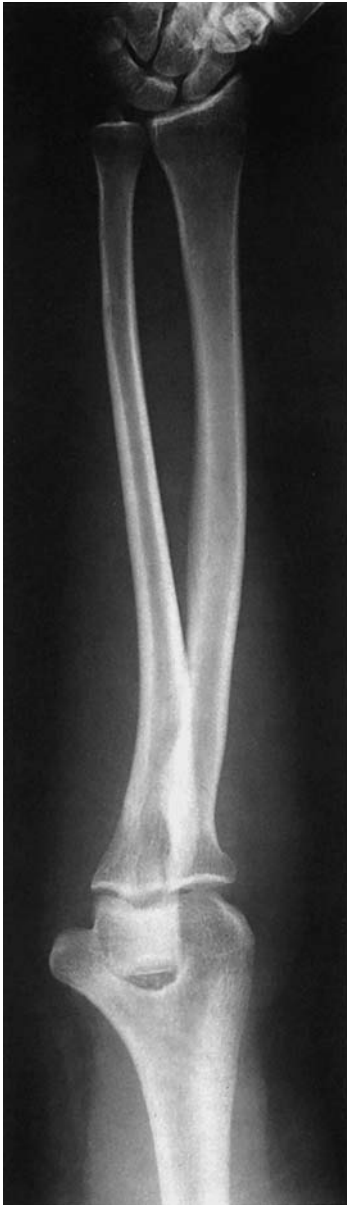- 6** Lateral epicondyle
- 7** Radial head
- 8** Humerus
- 9** Ulna
- 10** Radius



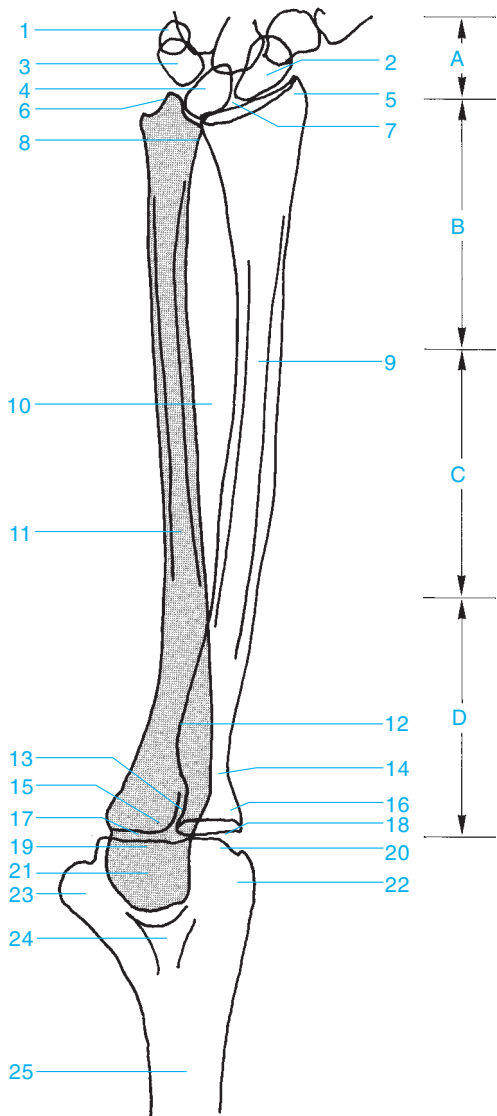


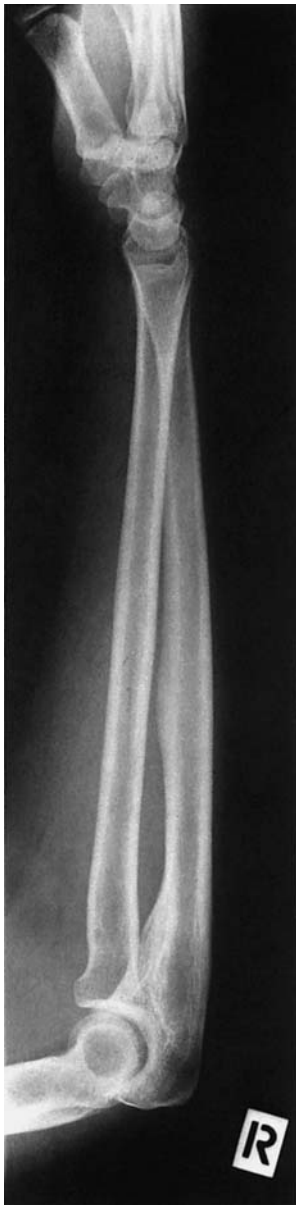- 1 Humerus
- 2 Olecranon fossa
- 3 Medial epicondyle
- 4 Olecranon
- 5 Lateral epicondyle
- 6 Trochlea
- 7 Capitellum
- 8 Humeroulnar joint

- 9 Humeroradial joint
- 10 Coronoid process
- 11 Radial head
- 12 Proximal radioulnar joint
- 13 Radial neck
- 14 Radial tuberosity
- 15 Ulna
- 16 Radius

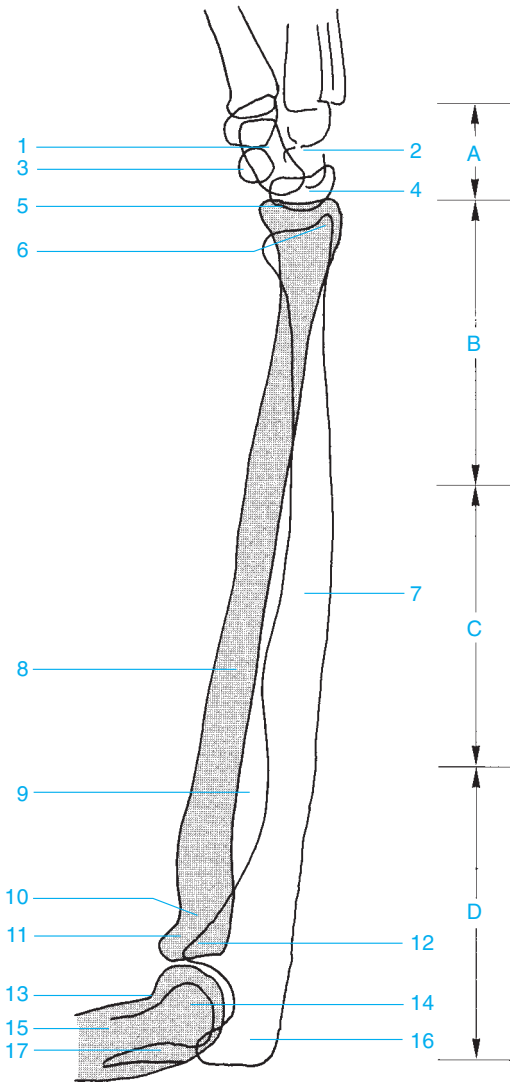


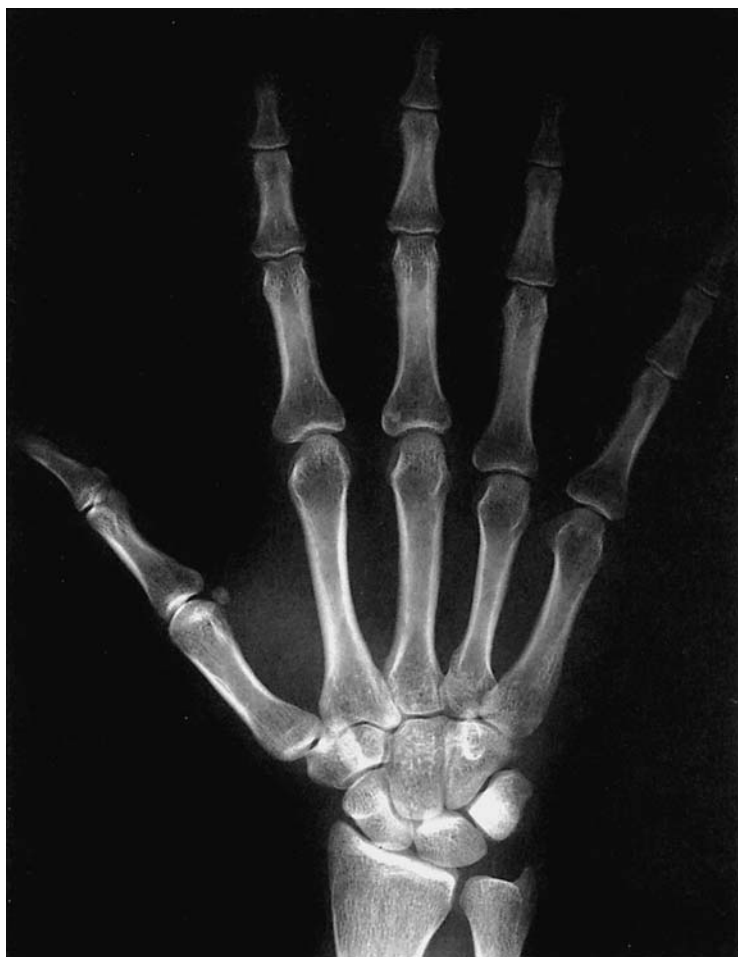- A Carpal bones
- B Distal third of the forearm
- C Middle third of the forearm
- D Proximal third of the forearm
- 1 Pisiform bone
- 2 Scaphoid
- 3 Triquetrum
- 4 Lunate bone
- 1-4 Proximal carpal row
- 5 Radial styloid
- 6 Ulnar styloid
- 7 Radiocarpal joint
- 8 Distal radioulnar joint
- 9 Radius
- 10 Interosseous membrane
- 11 Ulna
- 12 Radial tuberosity
- 13 Proximal radioulnar joint
- 14 Radial neck
- 15 Coronoid process
- 16 Radial head
- 17 Humeroulnar joint
- 18 Humeroradial joint
- 19 Trochlea
- 20 Capitellum
- 21 Olecranon
- 22 Lateral epicondyle of the humerus
- 23 Medial epicondyle of the humerus
- 24 Olecranon fossa
- 25 Humerus

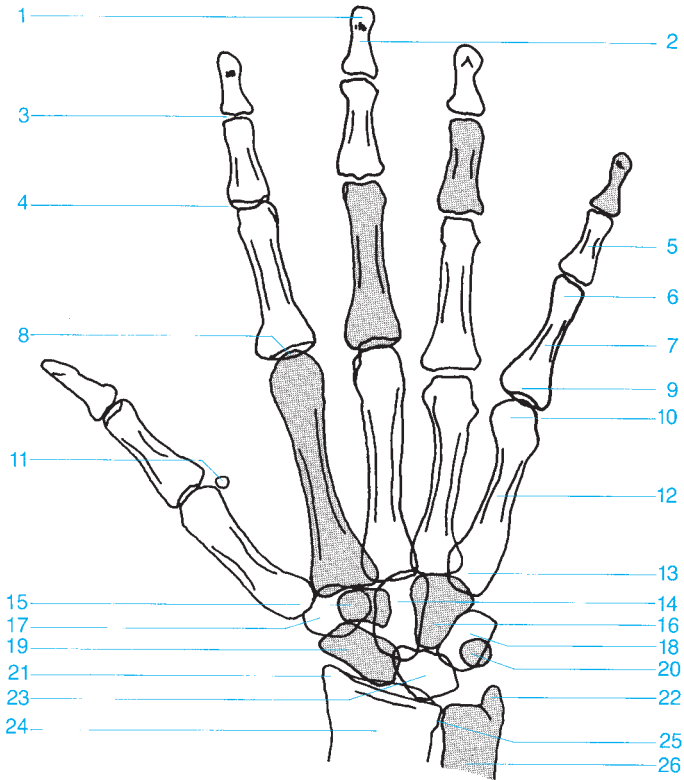




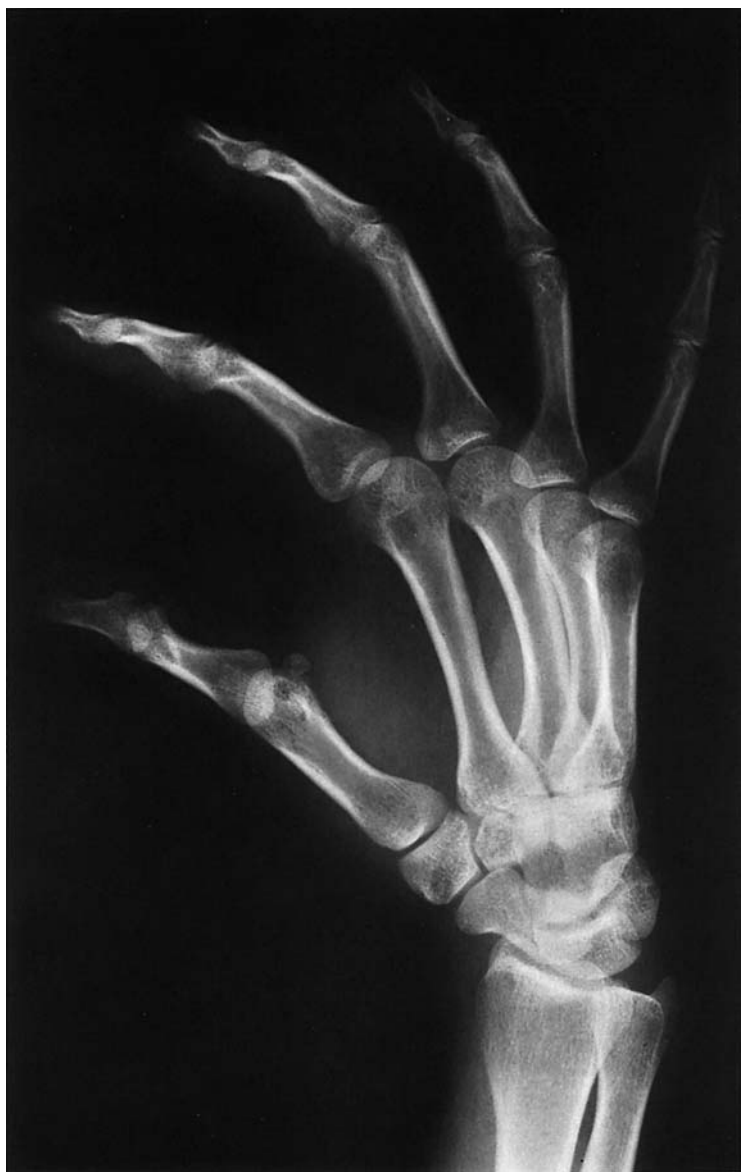- A Carpal bones
- B Distal third of the forearm
- C Middle third of the forearm
- D Proximal third of the forearm
- 1 Triquetrum
- 2 Scapoid
- 3 Pisiform bone
- 4 Lunate bone
- 1-4 Proximal carpal row
- 5 Radiocarpal joint
- 6 Ulnar styloid
- 7 Ulna
- 8 Radius
- 9 Interosseous membrane
- 10 Radial neck
- 11 Radial head
- 12 Coronoid process
- 13 Coronoid fossa
- 14 Trochlea of the humerus
- 15 Humerus
- 16 Olecranon
- 17 Olecranon fossa

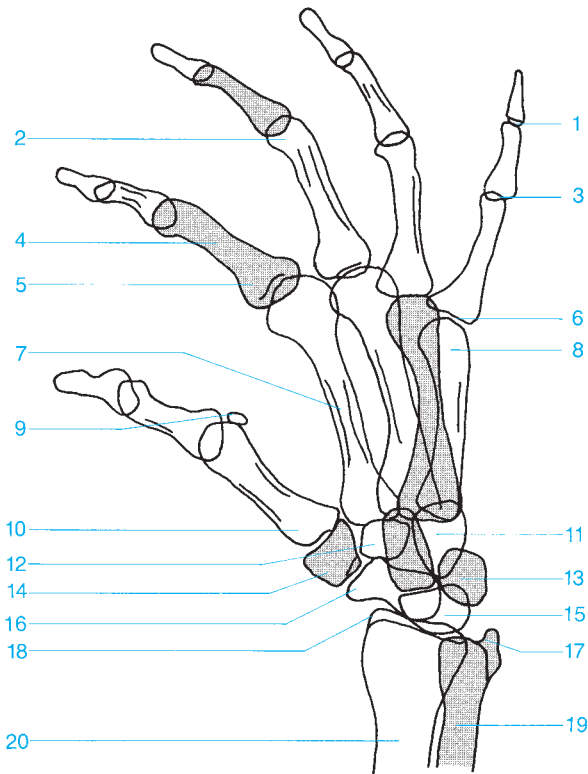




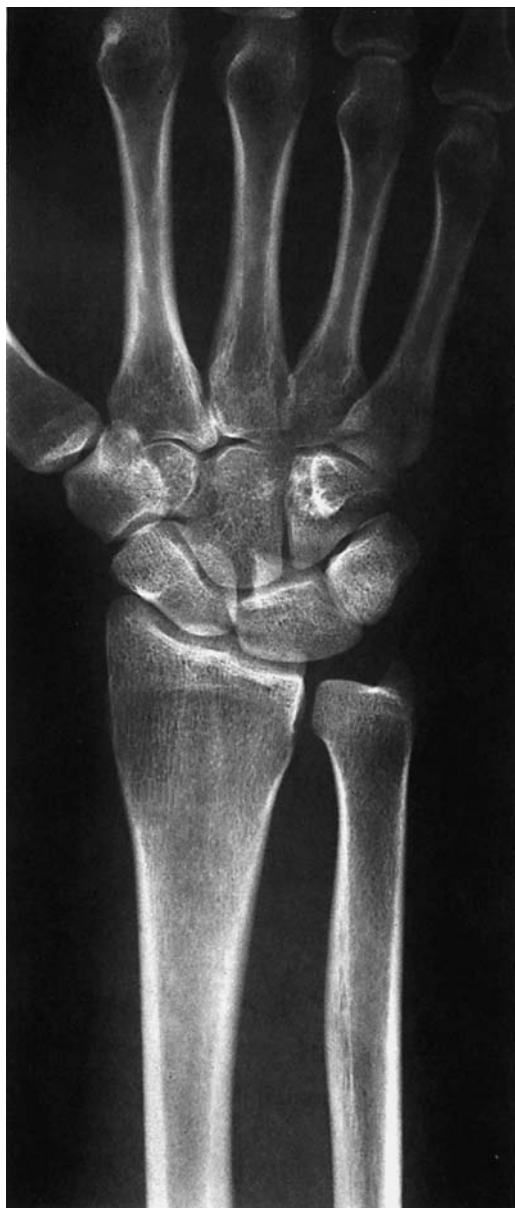

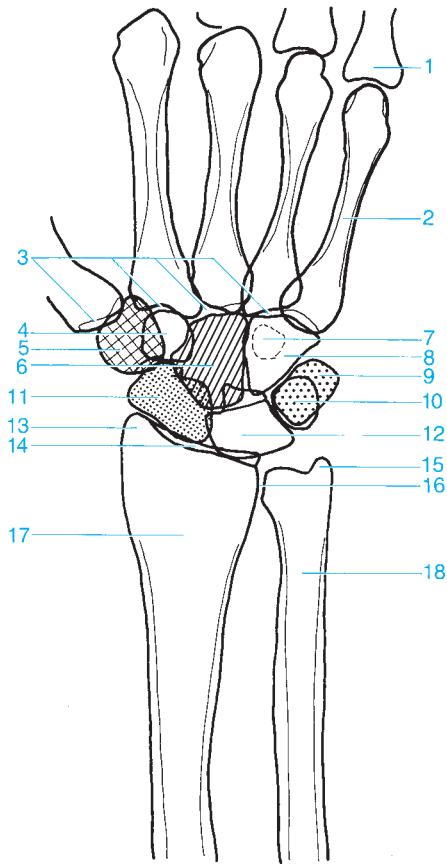
- | | |
|----------------------------------|----------------------------|
| 1 Distal phalanx (tuft) | 14 Capitate |
| 2 Distal phalanx | 15 Trapezoid |
| 3 Distal interphalangeal joint | 16 Hamate |
| 4 Proximal interphalangeal joint | 17 Trapezium |
| 5 Middle phalanx | 18 Triquetrum |
| 6 Head of the proximal phalanx | 19 Scaphoid |
| 7 Proximal phalanx | 20 Pisiform |
| 8 Metacarpophalangeal joint | 21 Radial styloid |
| 9 Base of the proximal phalanx | 22 Ulnar styloid |
| 10 Metacarpal head | 23 Lunate |
| 11 Sesamoid | 24 Distal radius |
| 12 Metacarpal | 25 Distal radioulnar joint |
| 13 Metacarpal base | 26 Distal ulna |





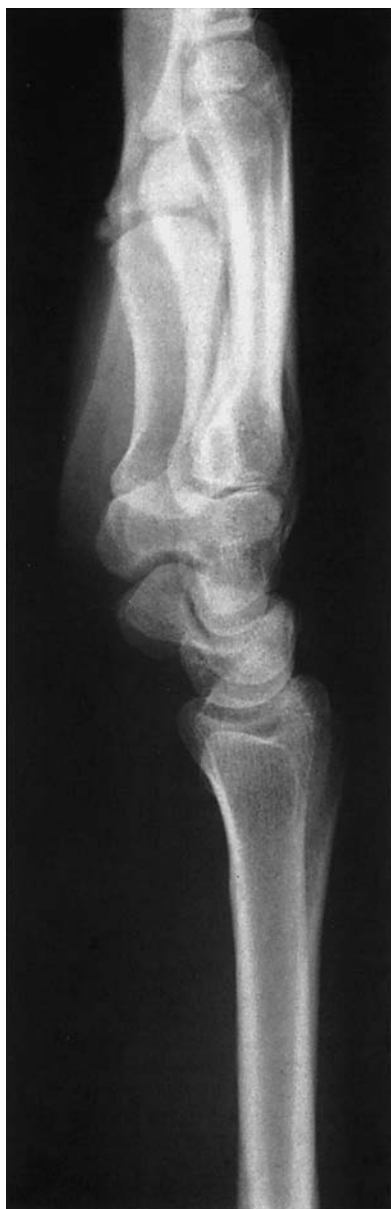- | | |
|---|-------------------------------|
| 1 Distal interphalangeal joint | 11 Capitate and hamate |
| 2 Head of the proximal phalanx | 12 Trapezoid |
| 3 Proximal interphalangeal joint | 13 Triquetrum |
| 4 Proximal phalanx | 14 Trapezium |
| 5 Base of the proximal phalanx | 15 Lunate |
| 6 Metacarpophalangeal joint | 16 Scaphoid |
| 7 Metacarpal | 17 Ulnar styloid |
| 8 Metacarpal head | 18 Radial styloid |
| 9 Sesamoid | 19 Distal ulna |
| 10 Metacarpal base | 20 Distal radius |

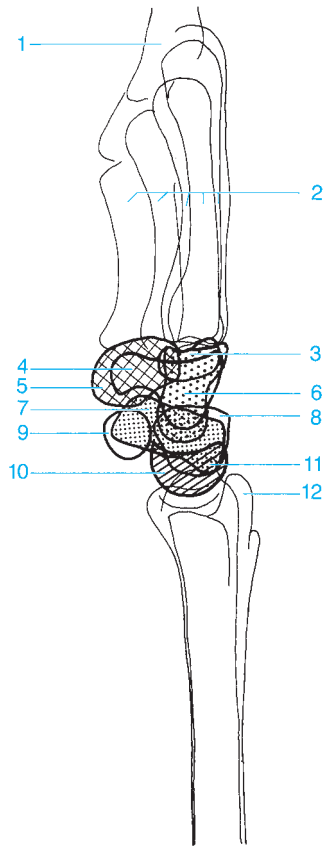








- 1 Proximal phalanx
- 2 Fifth metacarpal
- 3 Carpometacarpal joint
- 4 Trapezoid
- 5 Trapezium
- 6 Capitate
- 7 Hook of the Hamate
- 8 Hamate
- 9 Triquetrum

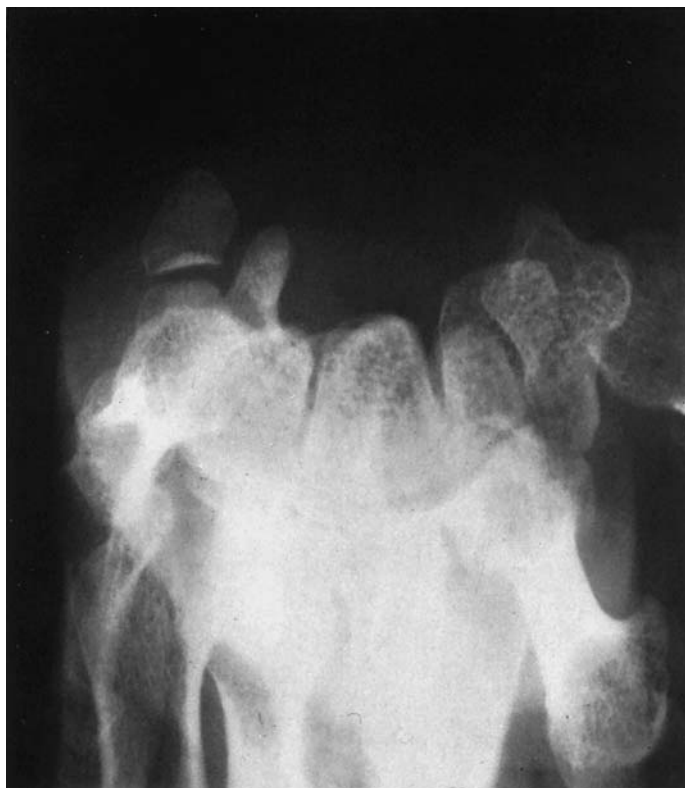- 10 Pisiform
- 11 Scaphoid
- 12 Lunate
- 13 Radial styloid
- 14 Radiocarpal joint
- 15 Ulnar styloid
- 16 Radioulnar joint
- 17 Radius
- 18 Ulna

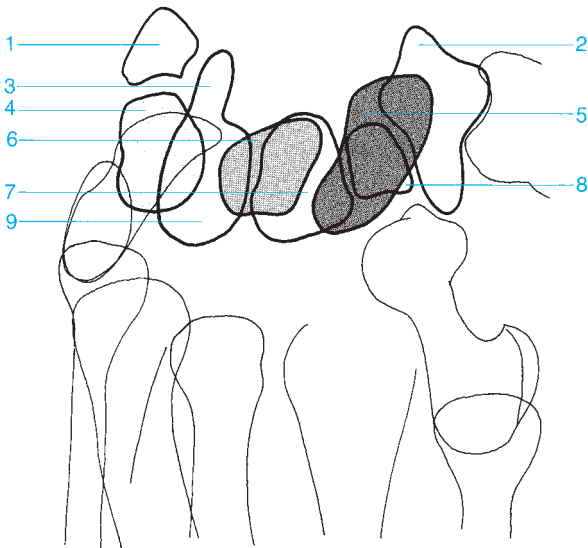



- 1 Proximal phalanx
- 2 Metacarpals
- 3 Trapezoid
- 4 Hook of the Hamate
- 5 Trapezium 
- 6 Capitate 

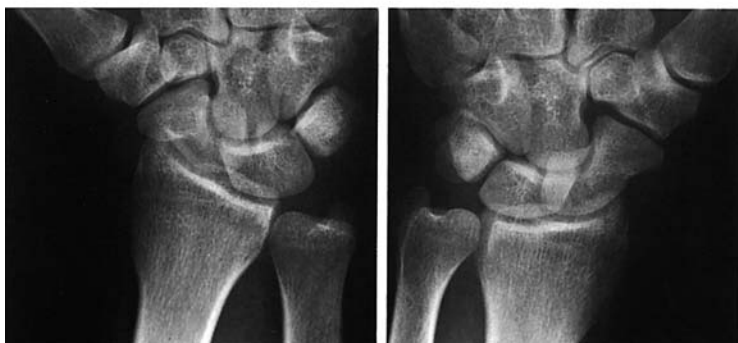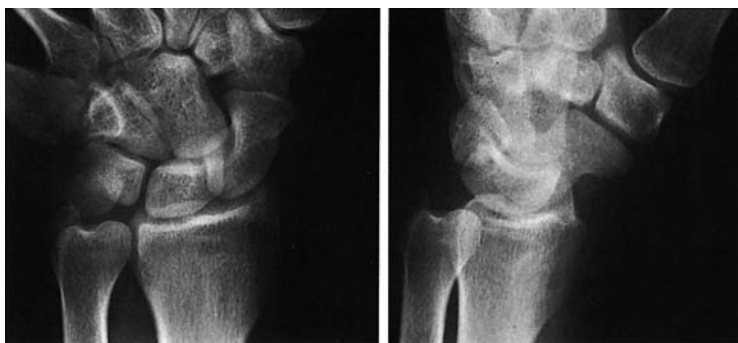- 7 Scaphoid 
- 8 Triquetrum
- 9 Pisiform
- 10 Lunate 
- 11 Radial styloid
- 12 Ulnar styloid

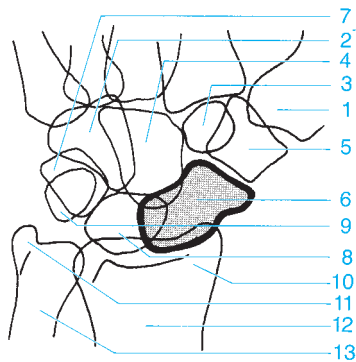
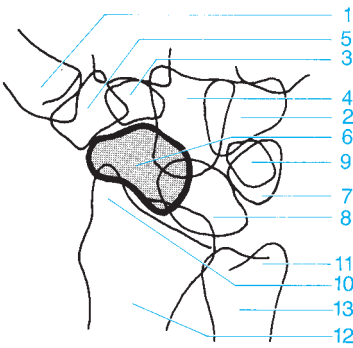
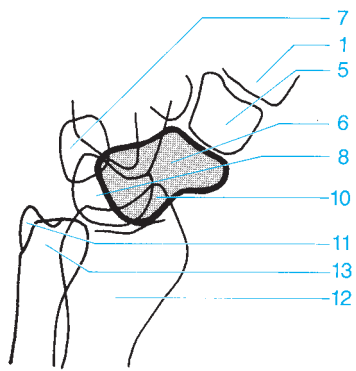
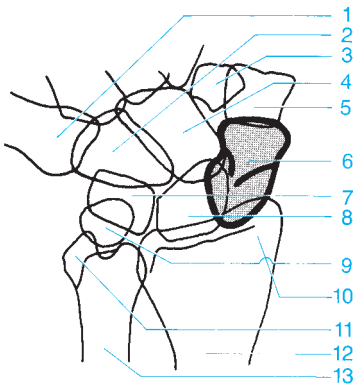




- 1 Pisiform
- 2 Trapezium
- 3 Hook of the hamate
- 4 Triquetrum
- 5 Scaphoid

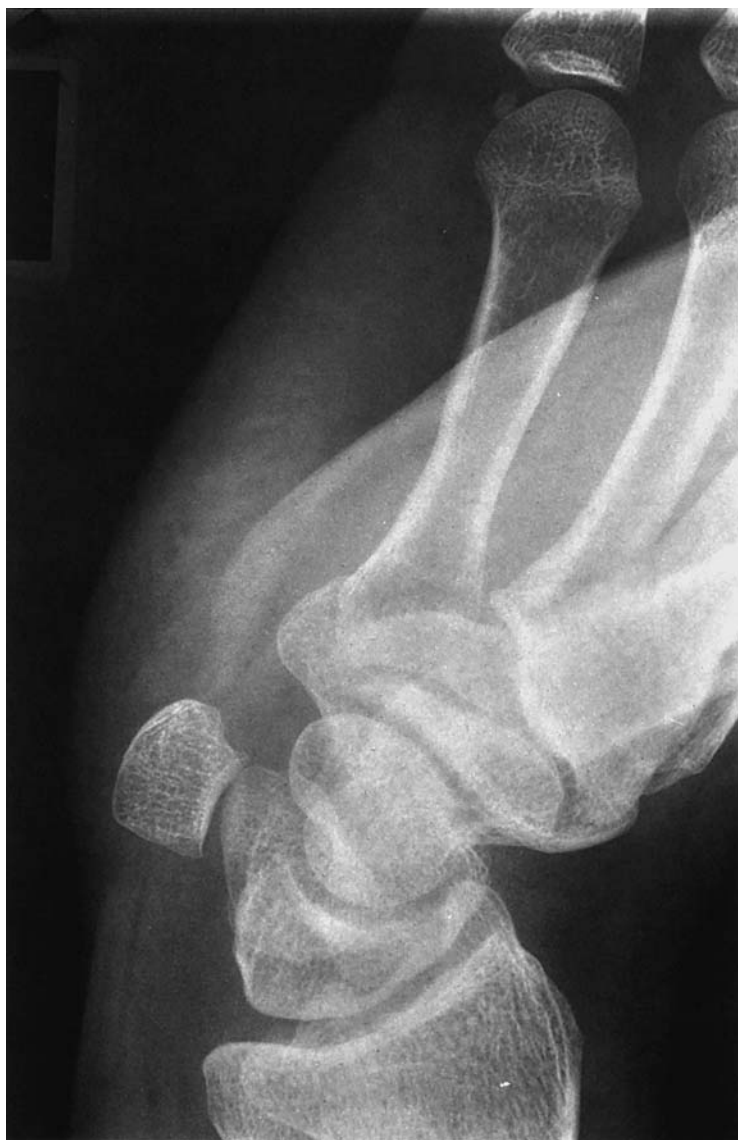- 6 Lunate
- 7 Capitate
- 8 Trapezoid
- 9 Hamate

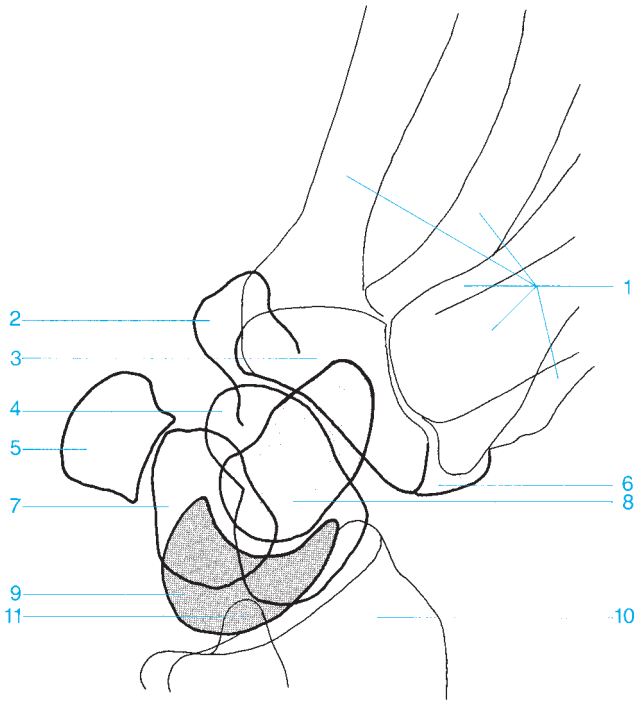




- 1 Metacarpal
- 2 Hamate
- 3 Trapezoid
- 4 Capitate
- 5 Trapezium
- 6 Scaphoid
- 7 Triquetrum

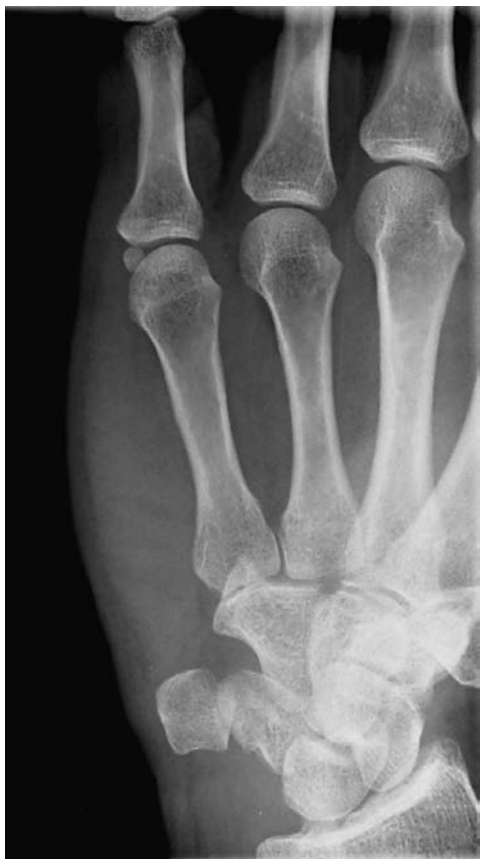- 8 Lunate
- 9 Pisiform
- 10 Radial styloid
- 11 Ulnar styloid
- 12 Radius
- 13 Ulna

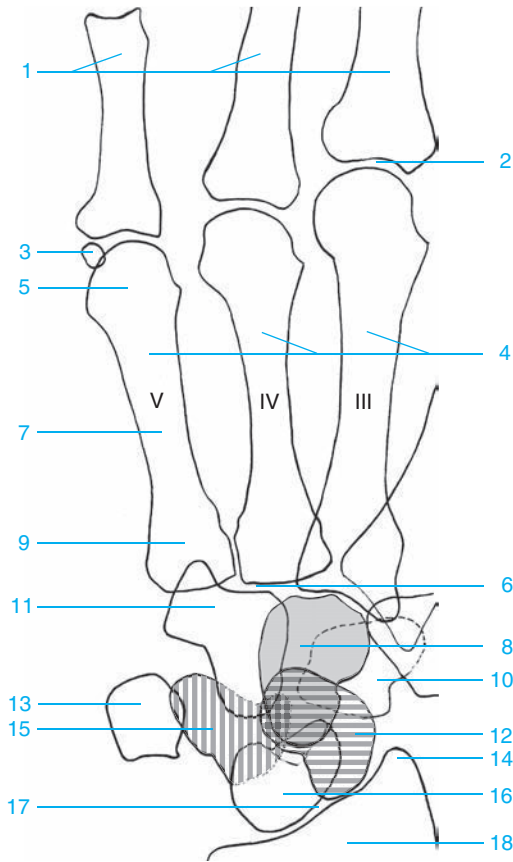









- 1 Metacarpals
- 2 Hamate
- 3 Trapezoid
- 4 Scaphoid
- 5 Pisiform
- 6 Trapezium

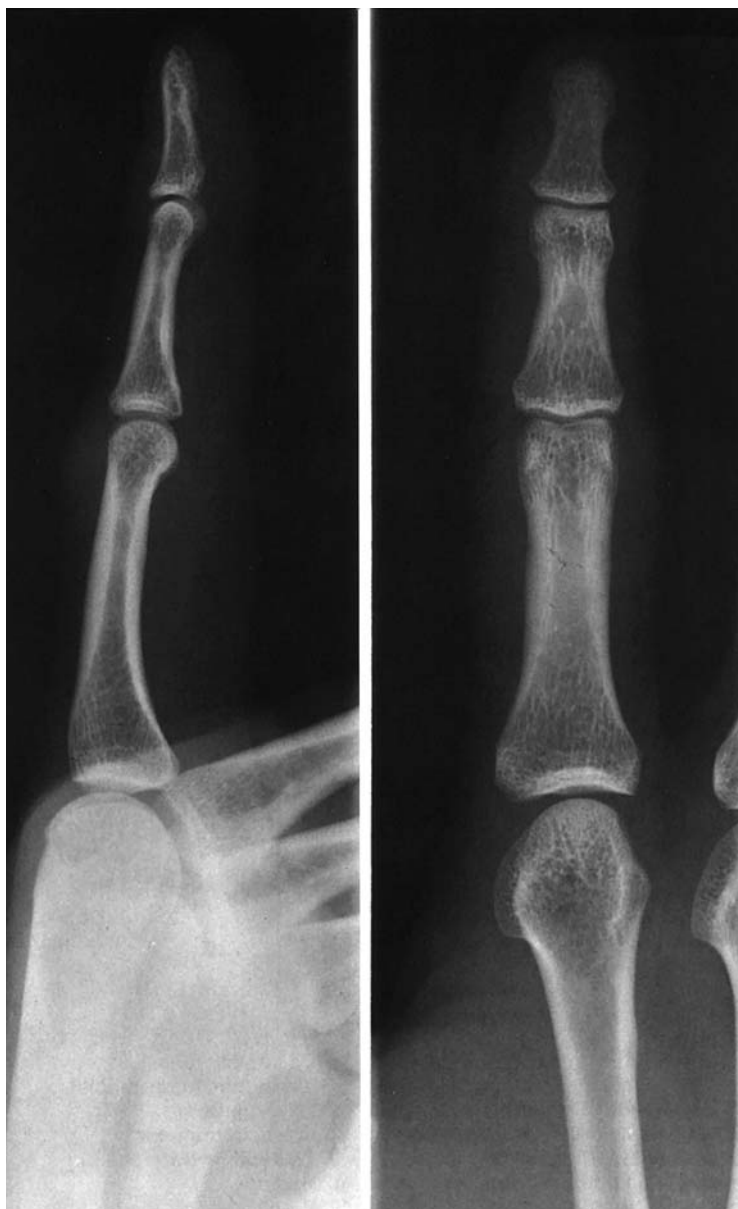- 7 Triquetrum
- 8 Capitate
- 9 Lunate
- 10 Radius
- 11 Ulnar styloid

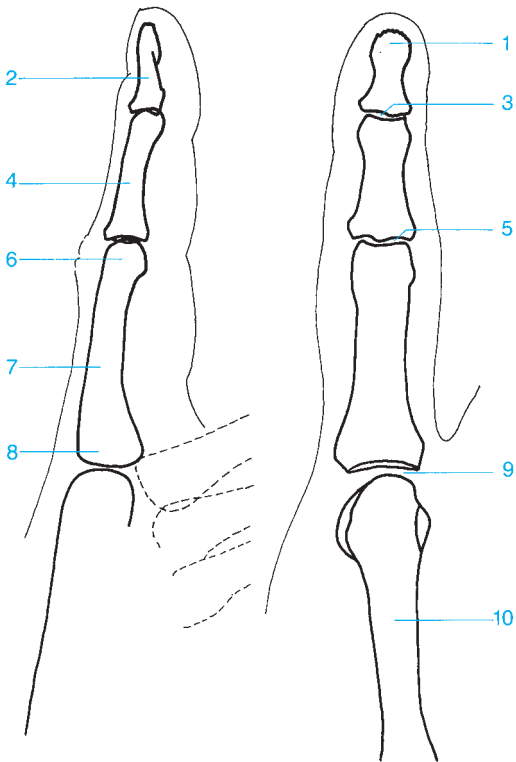




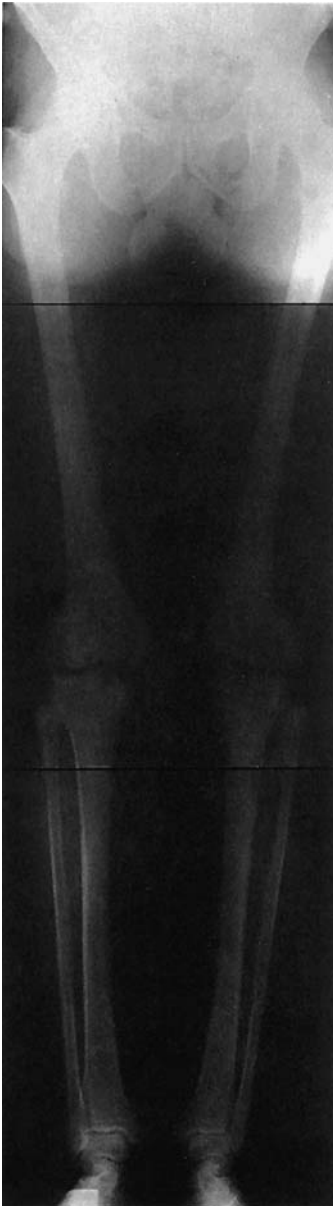- 1 Proximal phalanges
- 2 Metacarpophalangeal joint
- 3 Sesamoid
- 4 Third through fifth metacarpals
- 5 Fifth metacarpal head
- 6 Carpometacarpal joint
- 7 Fifth metacarpal shaft
- 9 Fifth metacarpal base
- 10 Trapezium and trapezoid (overlapping projections)

- 11 Hamate
- 12 Scaphoid 
- 13 Pisiform 
- 14 Radial styloid 
- 15 Triquetrum 
- 16 Lunate 
- 17 Radiocarpal joint
- 18 Radius

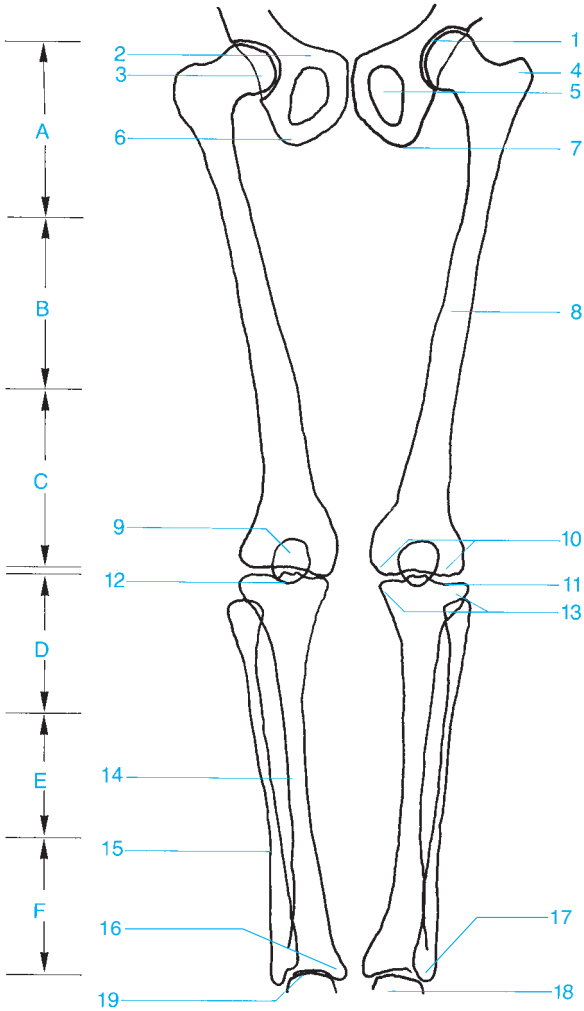


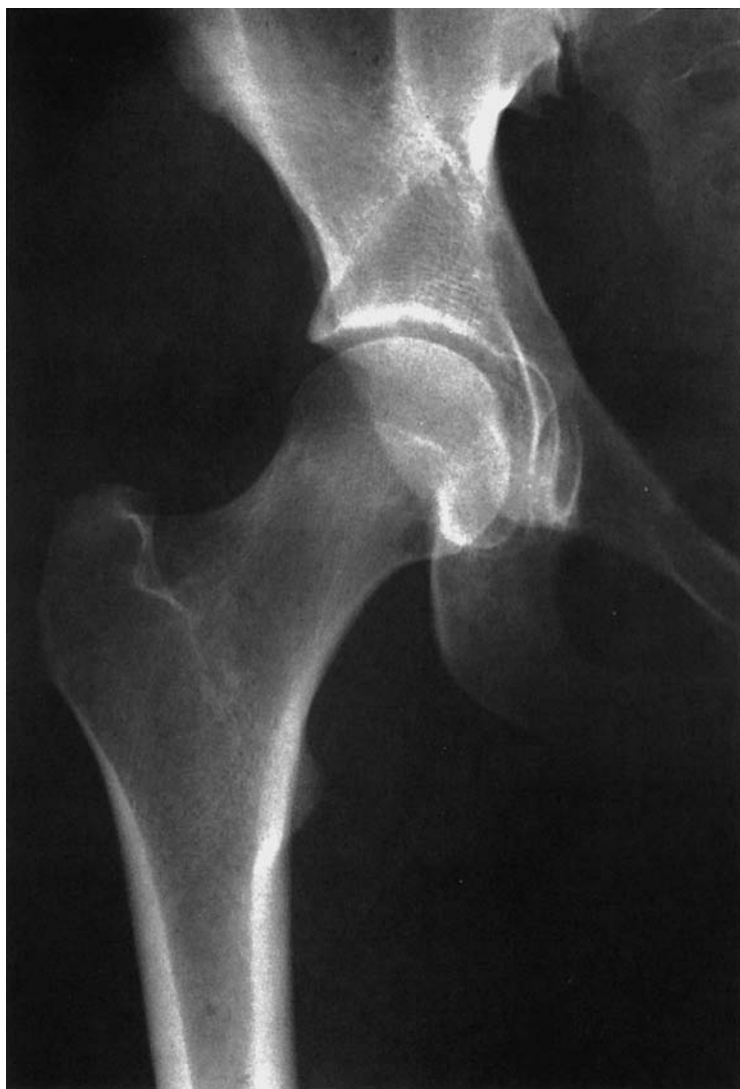

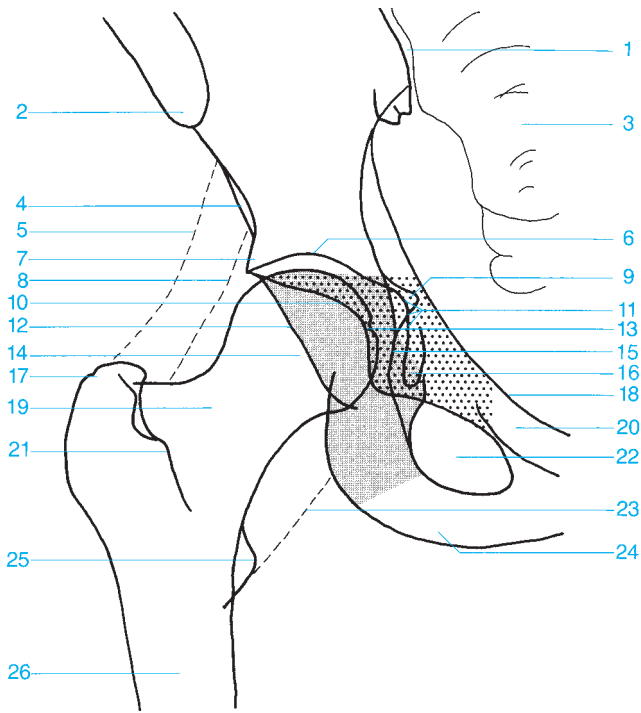
- | | |
|---|---------------------------------------|
| 1 Distal phalanx (tuft) | 6 Head of the proximal phalanx |
| 2 Distal phalanx | 7 Proximal phalanx |
| 3 Distal interphalangeal joint | 8 Base of the proximal phalanx |
| 4 Middle phalanx | 9 Metacarpophalangeal joint |
| 5 Proximal interphalangeal joint | 10 Metacarpal |



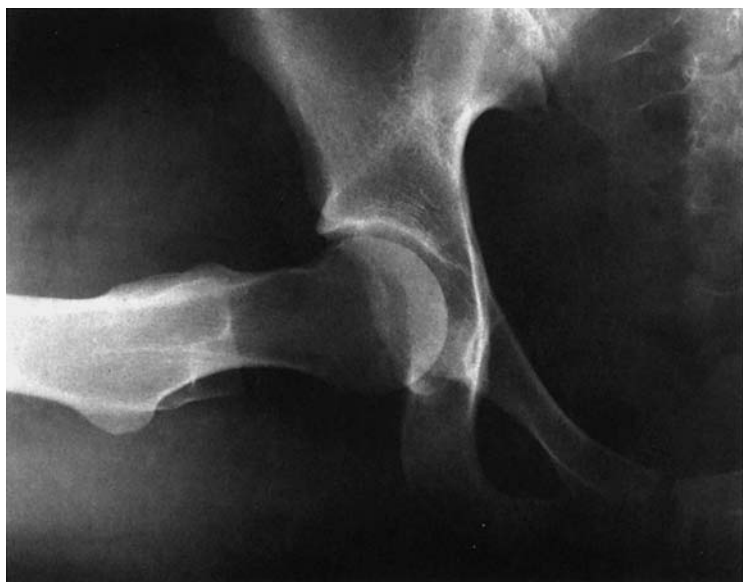- A** Proximal third of the femur
- B** Middle third of the femur
- C** Distal third of the femur
- D** Proximal third of the lower leg
- E** Medial third of the lower leg
- F** Distal third of the lower leg
- 1** Joint space of the hip
- 2** Pubic bone
- 3** Femoral head
- 4** Greater trochanter
- 5** Obturator foramen
- 6** Ischium
- 7** Ischial tuberosity
- 8** Femur
- 9** Patella
- 10** Medial and lateral femoral condyles
- 11** Joint space of the knee
- 12** Intercondylar eminence
- 13** Medial and lateral tibial condyles
- 14** Tibia
- 15** Fibula
- 16** Medial malleolus
- 17** Lateral malleolus
- 18** Trochlea of the talus
- 19** Ankle

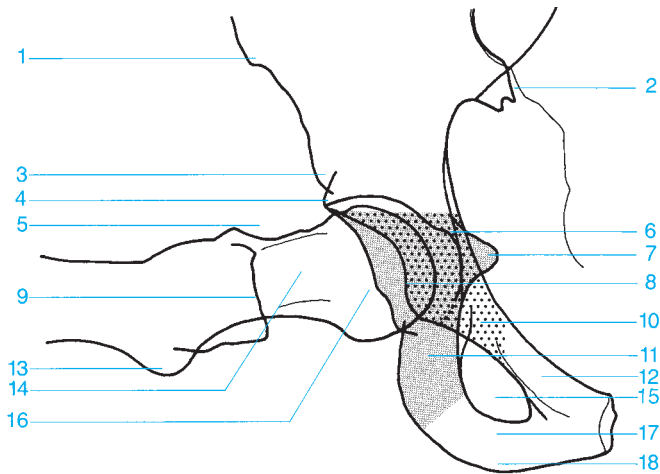






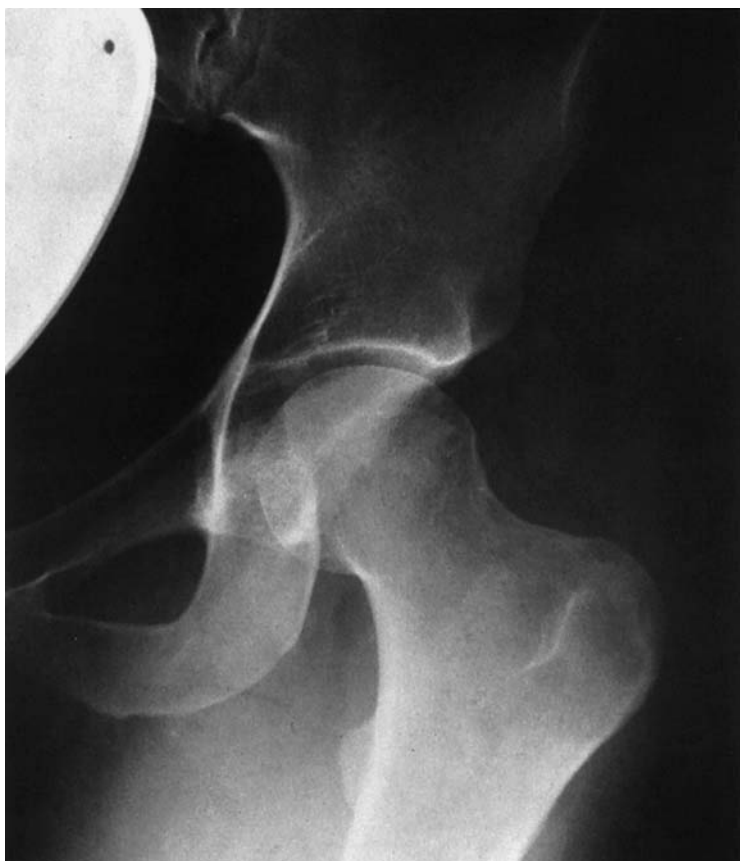
- | | |
|--|---|
| 1 Sacroiliac joint | 15 Ilioischial line |
| 2 Anterior superior iliac spine | 16 Köhler's teardrop figure |
| 3 Sacrum | 17 Greater trochanter |
| 4 Anterior inferior iliac spine | 18 Terminal line |
| 5 Intergluteal fat stripe | 19 Femoral neck |
| 6 Roof of the acetabulum | 20 Superior pubic ramus |
| 7 Acetabular convexity (promontory) | 21 Intertrochanteric crest |
| 8 Fat stripe medial to the gluteus minimus | 22 Obturator foramen |
| 9 Spine of the ischium | 23 Fat stripe medial to the iliopsoas |
| 10 Anterior acetabular rim | 24 Ischial tuberosity |
| 11 Floor of the acetabulum | 25 Lesser trochanter |
| 12 Posterior acetabular rim | 26 Femur |
| 13 Fovea of the femoral head | ■ Ischium (posterior column) |
| 14 Femoral head | ▨ Pubic bone, anterior column (anterior column) |

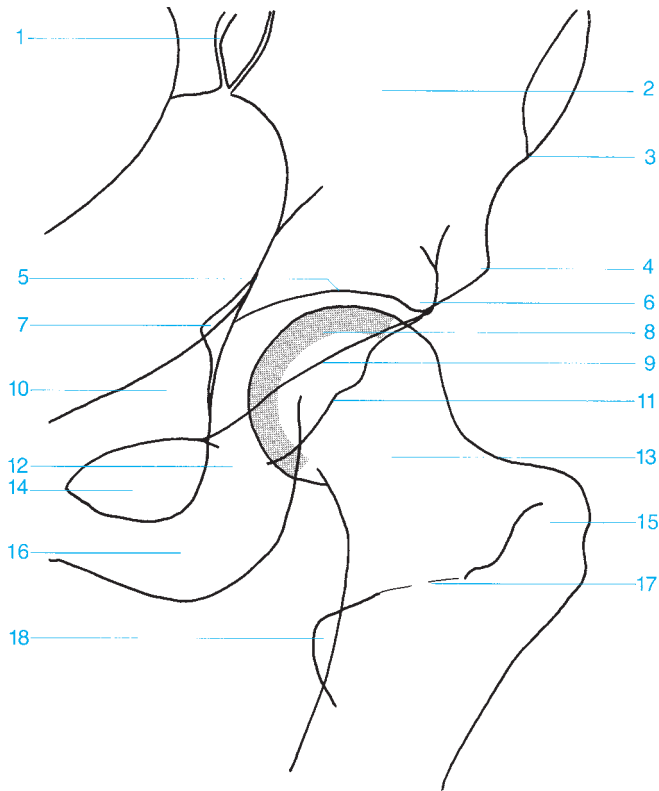




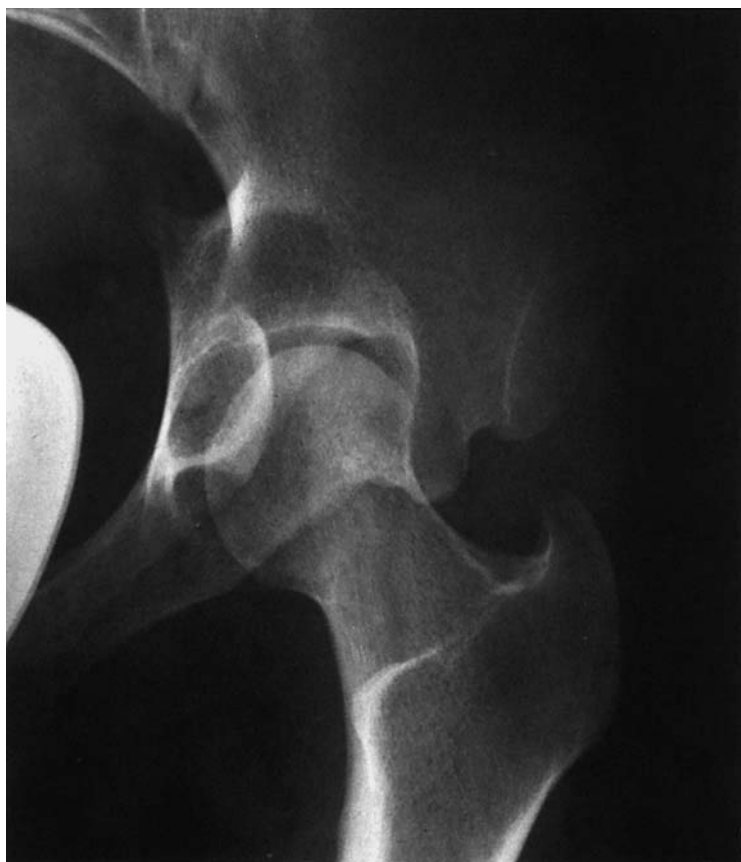- 1 Anterior superior iliac spine
- 2 Sacroiliac joint
- 3 Anterior inferior iliac spine
- 4 Superior acetabular rim
- 5 Posterior acetabular rim
- 6 Floor of the acetabulum
- 7 Spine of the ischium
- 8 Anterior acetabular rim
- 9 Greater trochanter
- 10 Pubic bone (anterior column)

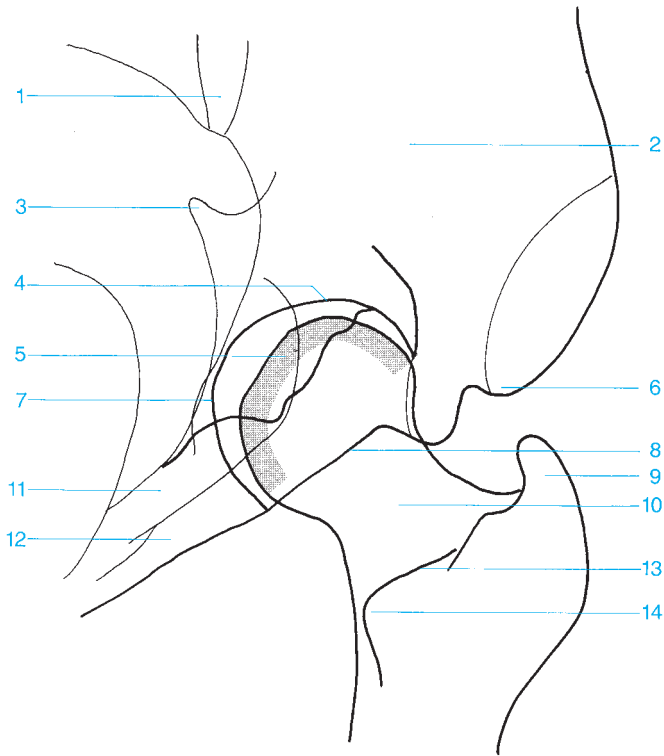
- 11 Ischium (posterior column)
 - 12 Superior pubic ramus
 - 13 Lesser trochanter
 - 14 Femoral neck
 - 15 Obturator foramen
 - 16 Femoral head
 - 17 Inferior pubic ramus
 - 18 Ischial tuberosity
- Pubic bone
 Ischium



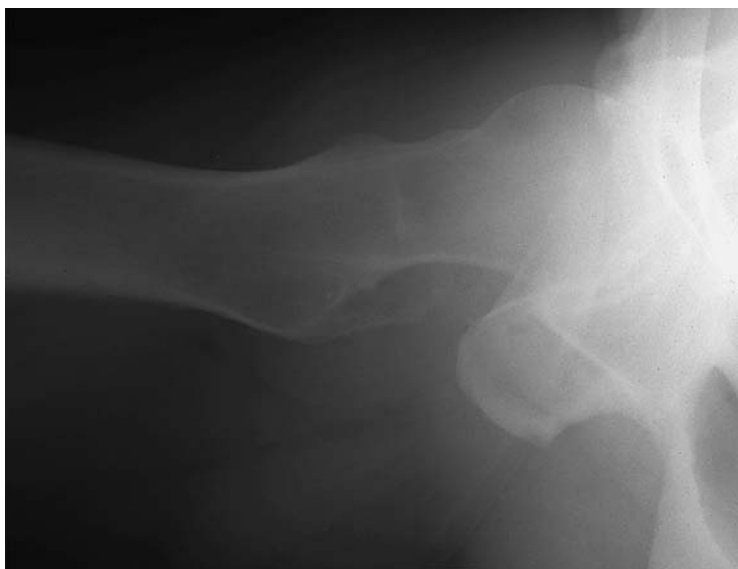

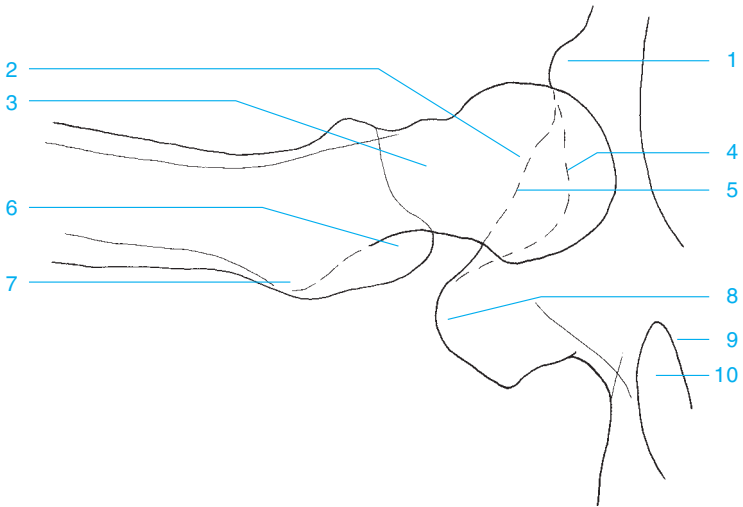
- | | |
|--|---------------------------------|
| 1 Sacroiliac joint | 10 Pubic bone (anterior column) |
| 2 Ilium | 11 Posterior acetabular rim |
| 3 Anterior superior iliac spine | 12 Ischium |
| 4 Anterior inferior iliac spine | 13 Femoral neck |
| 5 Roof of the acetabulum | 14 Obturator foramen |
| 6 Superior acetabular rim | 15 Greater trochanter |
| 7 Spine of the ischium | 16 Ischial tuberosity |
| 8 Anterior articular surface of the femoral head | 17 Intertrochanteric crest |
| 9 Anterior acetabular rim | 18 Lesser trochanter |





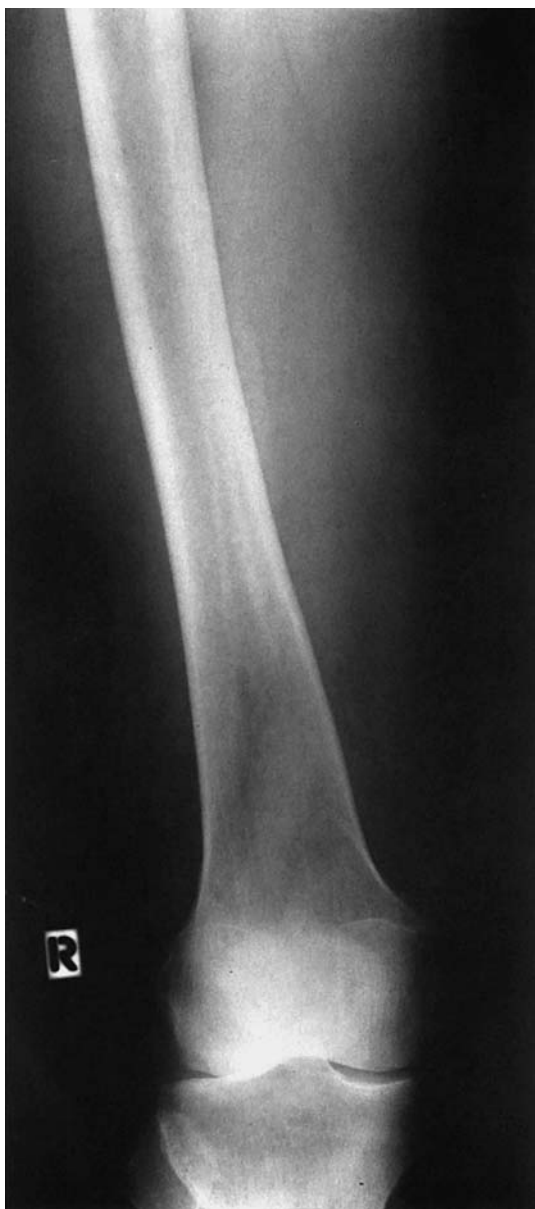- | | |
|---|----------------------------|
| 1 Sacroiliac joint | 8 Anterior acetabular rim |
| 2 Iliac bone | 9 Greater trochanter |
| 3 Spine of the ischium | 10 Femoral neck |
| 4 Roof of the acetabulum | 11 Ischium |
| 5 Posterior articular surface of the femoral head | 12 Pubic bone |
| 6 Anterior superior iliac spine | 13 Intertrochanteric crest |
| 7 Floor of the acetabulum | 14 Lesser trochanter |

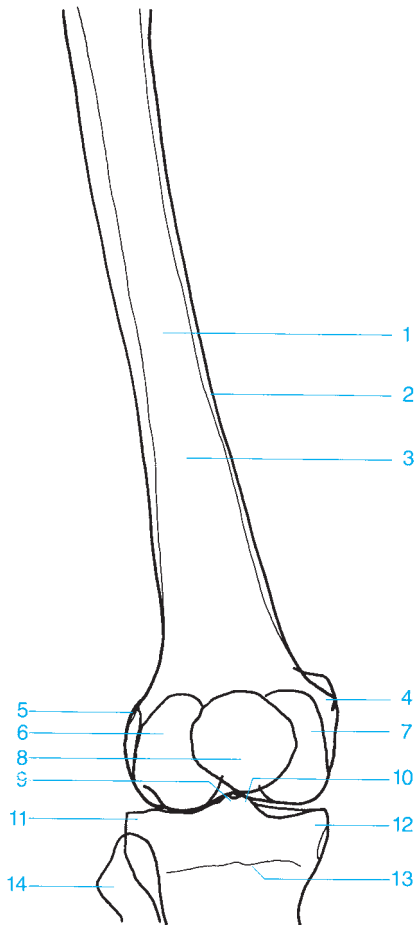




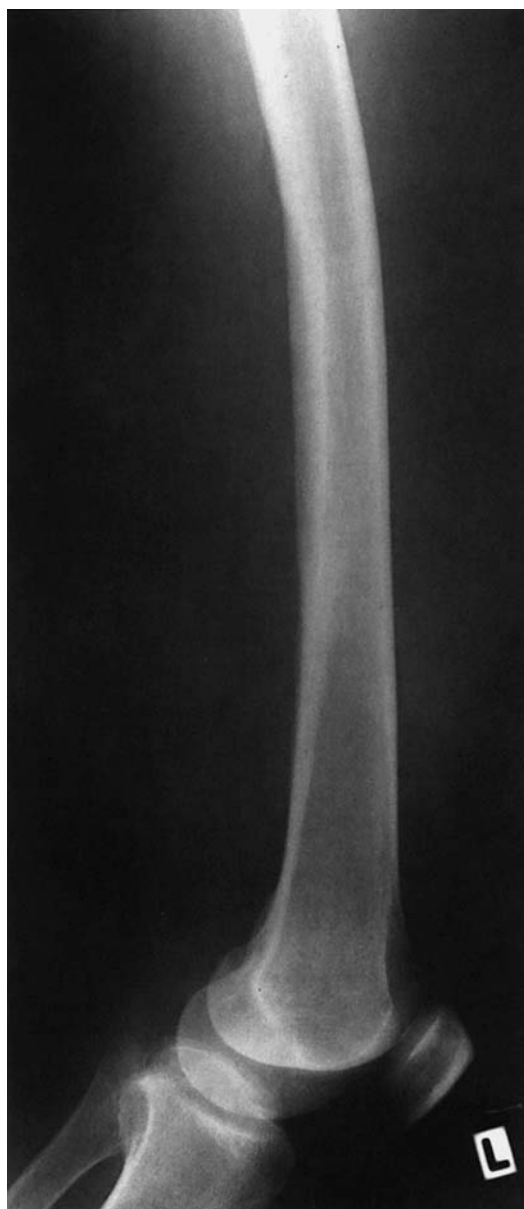- 1** Anterior inferior iliac spine
- 2** Femoral head
- 3** Femoral neck
- 4** Anterior acetabular rim
- 5** Posterior acetabular rim

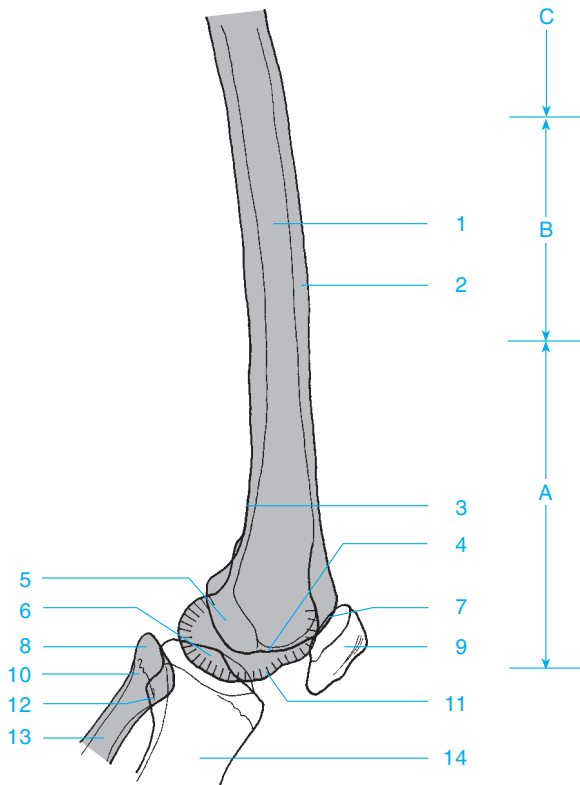
- 6** Greater trochanter
- 7** Lesser trochanter
- 8** Ischial tuberosity
- 9** Pubic bone
- 10** Obturator foramen





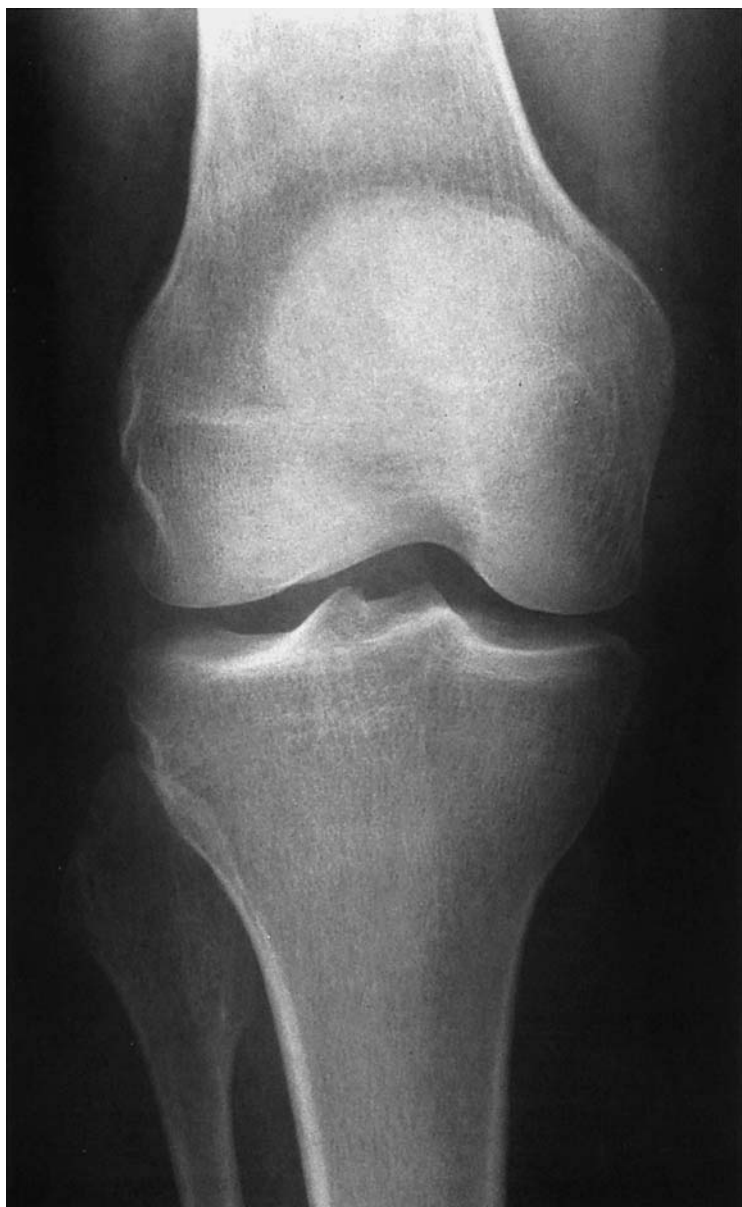
- | | |
|-------------------------------------|---|
| 1 Femoral shaft | 9 Lateral tubercle of the intercondylar eminence |
| 2 Cortex | 10 Medial tubercle of the intercondylar eminence |
| 3 Medullary canal | 11 Lateral tibial condyle |
| 4 Medial femoral epicondyle | 12 Medial tibial condyle |
| 5 Lateral femoral epicondyle | 13 Growth plate |
| 6 Lateral femoral condyle | 14 Fibular head |
| 7 Medial femoral condyle | |
| 8 Patella | |

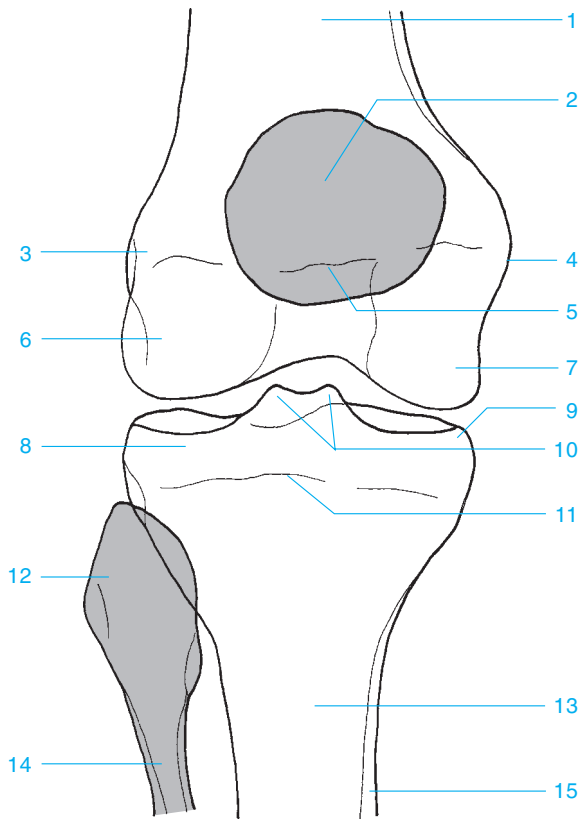




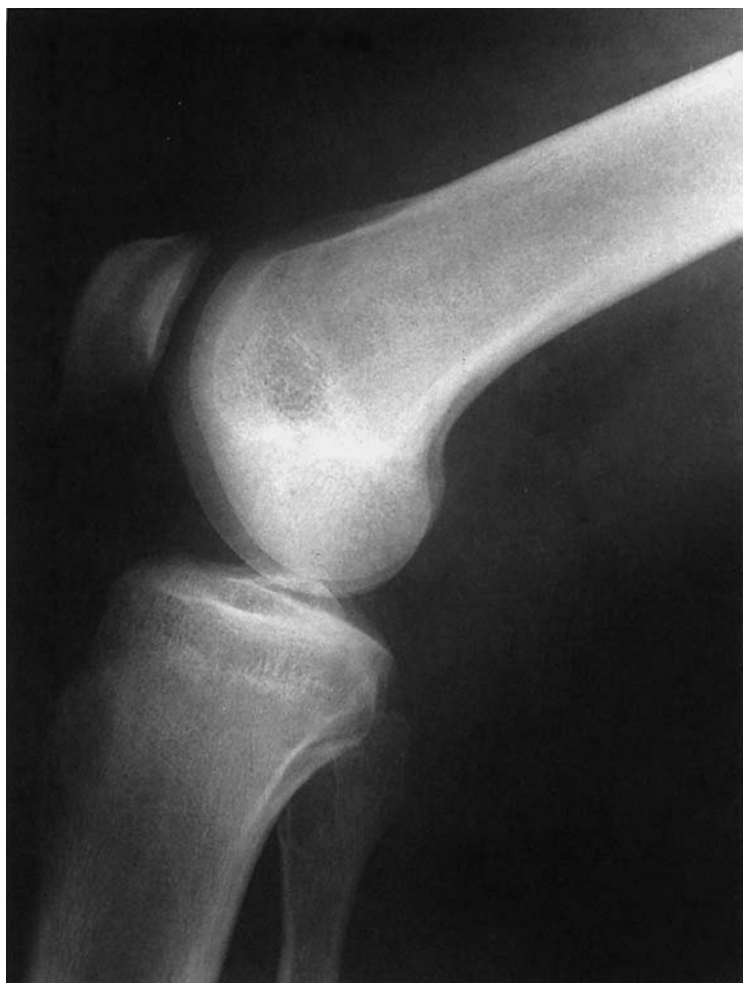- A** Distal third of the femur
- B** Middle third of the femur
- C** Proximal third of the femur
- 1** Femur
- 2** Cortex
- 3** Popliteal fossa
- 4** Lateral femoral condyle
- 5** Intercondylar fossa
- 6** Intercondylar eminence
- 7** Patellofemoral joint
- 8** Apex of the fibular head
- 9** Patella
- 10** Fibular head

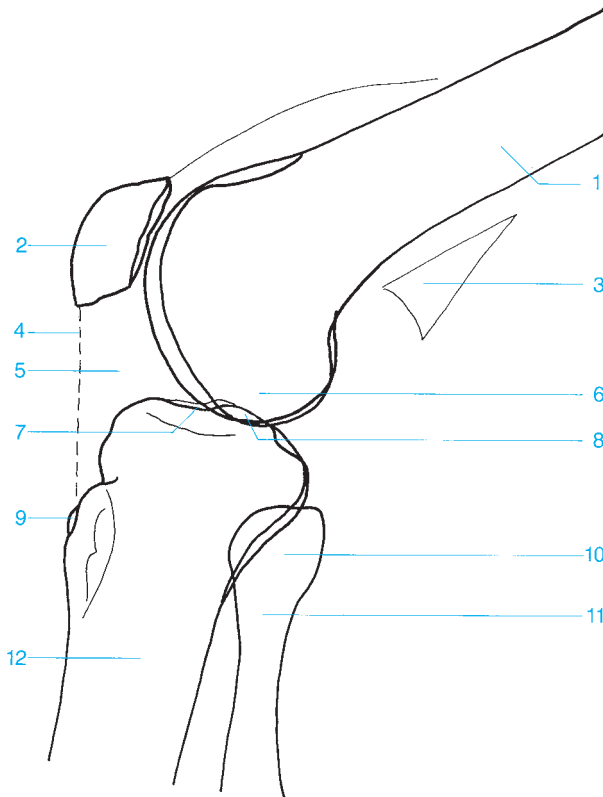
- 11** Medial femoral condyle
 - a** Opposite the lateral tibial condyle (4), which articulates with the fibula (13).
 - b** Regardless in which position the radiography was made, the corresponding lateral articular surfaces of the patella (9) and femur are longer proximal to distal than the corresponding medial articular surfaces.
- 12** Tibiofibular joint
- 13** Fibula



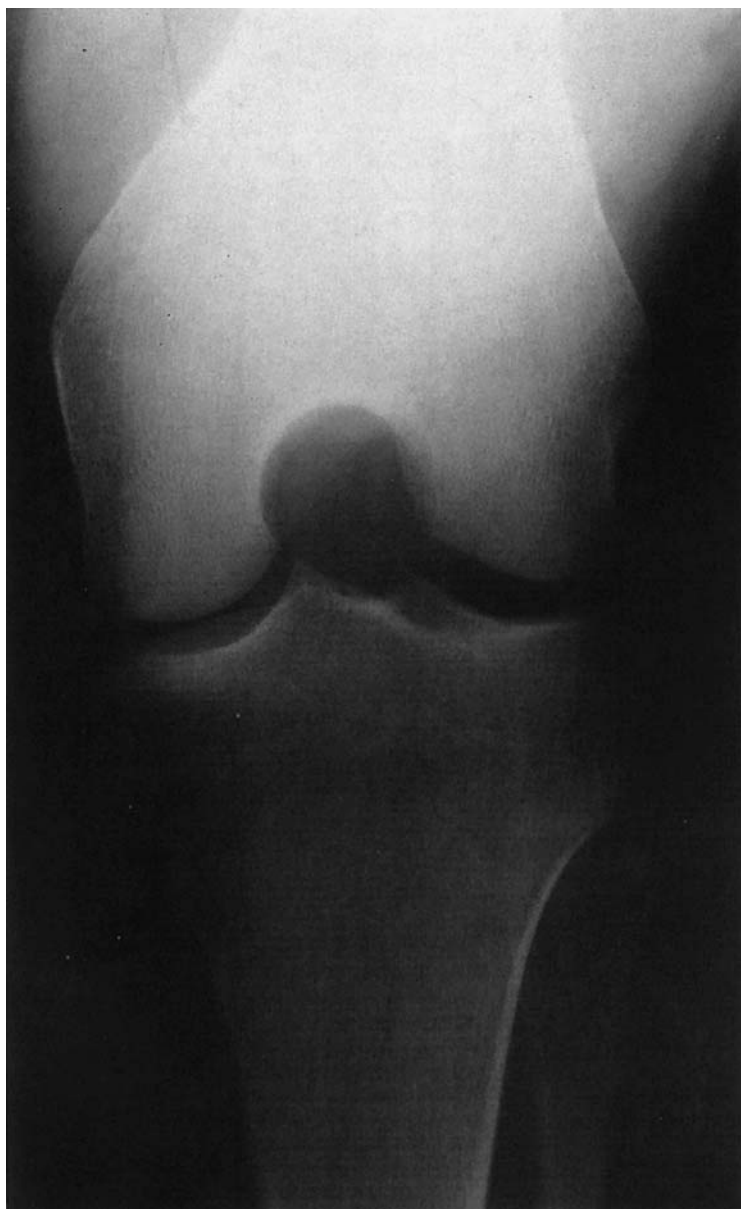


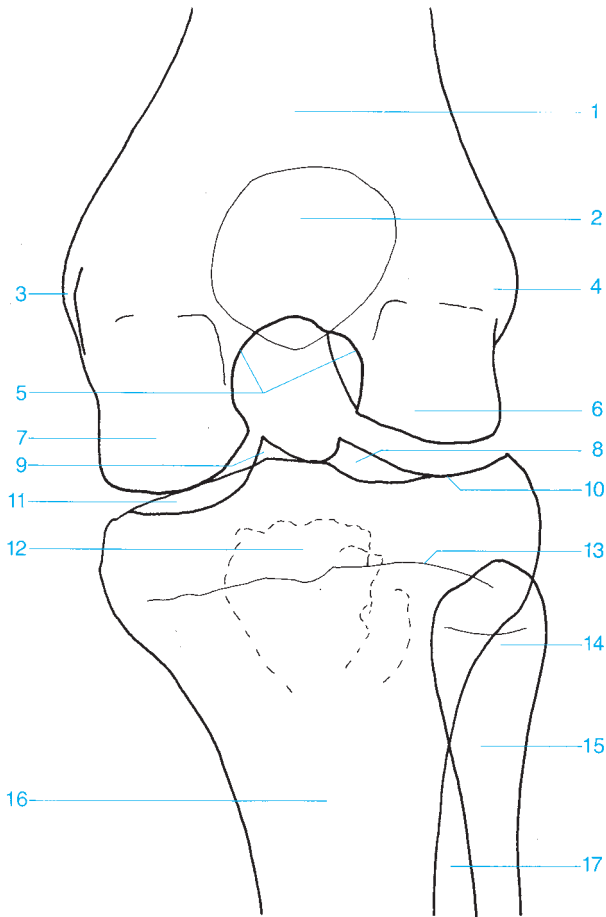
- | | |
|-------------------------------------|--|
| 1 Femur | 9 Medial tibial condyle |
| 2 Patella | 10 Medial and lateral tubercles of the intercondylar eminence |
| 3 Lateral femoral epicondyle | 11 Epiphyseal plate |
| 4 Medial femoral epicondyle | 12 Fibular head |
| 5 Growth plate | 13 Tibia |
| 6 Lateral femoral condyle | 14 Fibula |
| 7 Medial femoral condyle | 15 Cortex |
| 8 Lateral tibial condyle | |



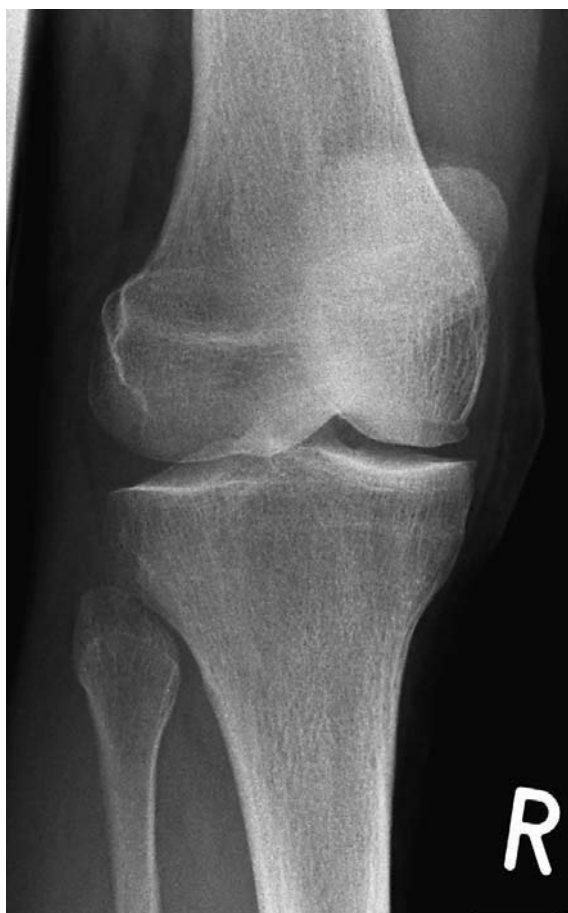

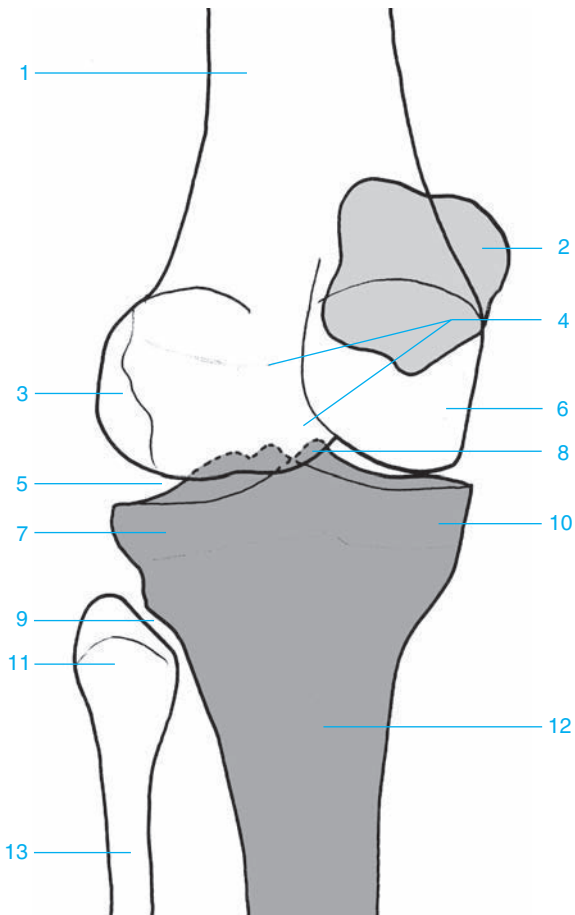
- | | |
|---------------------------|--------------------------|
| 1 Femur | 7 Tibial plateau |
| 2 Patella | 8 Intercondylar eminence |
| 3 Posterior fat | 9 Tibial tuberosity |
| 4 Patellar ligament | 10 Fibular head |
| 5 Infrapatellar fat pad | 11 Fibular neck |
| 6 Lateral femoral condyle | 12 Tibia |



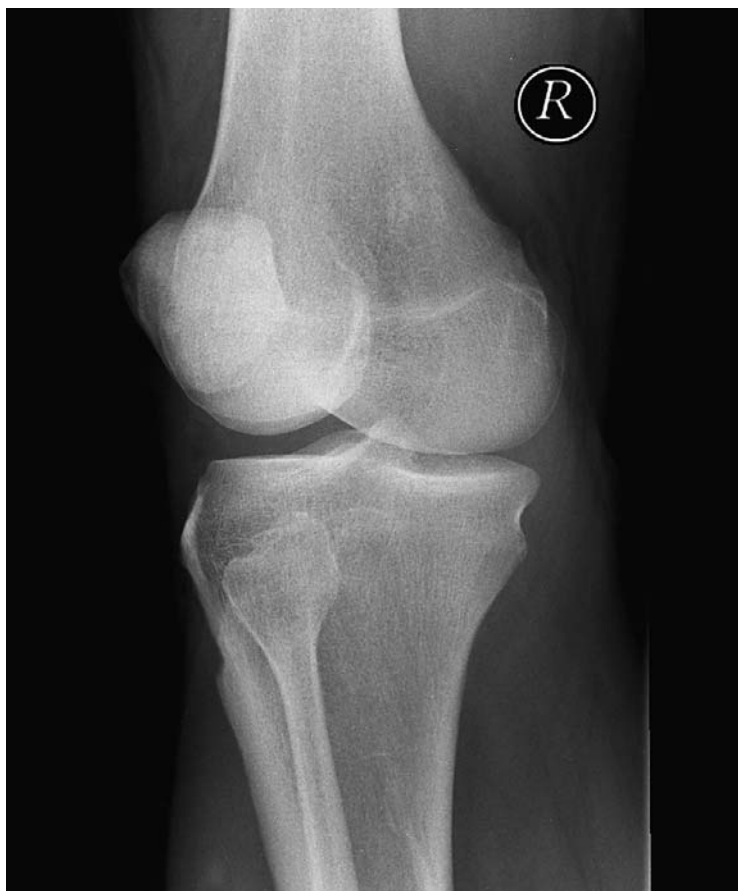

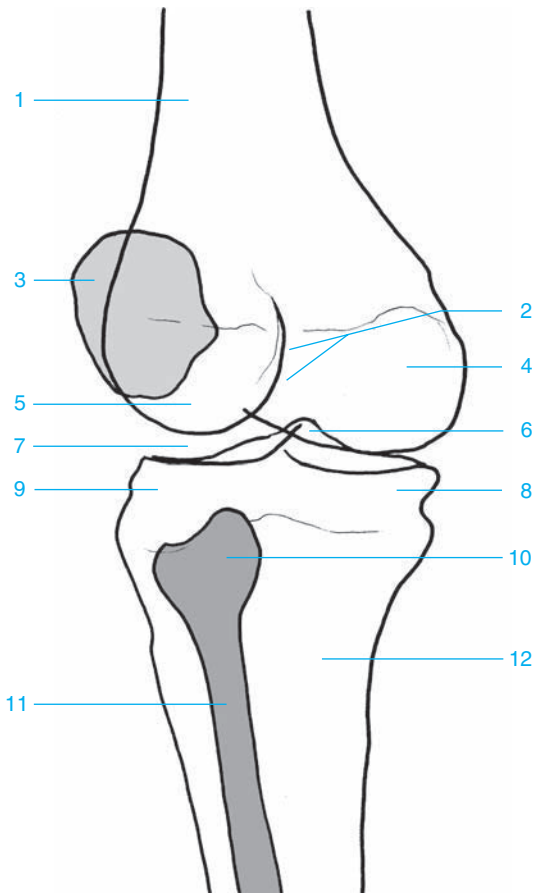
- | | |
|---|----------------------------------|
| 1 Femur | 10 Lateral tibial plateau |
| 2 Patella | 11 Medial tibial plateau |
| 3 Medial femoral epicondyle | 12 Tibial tuberosity |
| 4 Lateral femoral epicondyle | 13 Growth plate |
| 5 Intercondylar fossa | 14 Fibular head |
| 6 Lateral femoral condyle | 15 Fibular neck |
| 7 Medial femoral condyle | 16 Tibia |
| 8 Lateral tubercle of the intercondylar eminence | 17 Interosseous membrane |
| 9 Medial tubercle of the intercondylar eminence | |



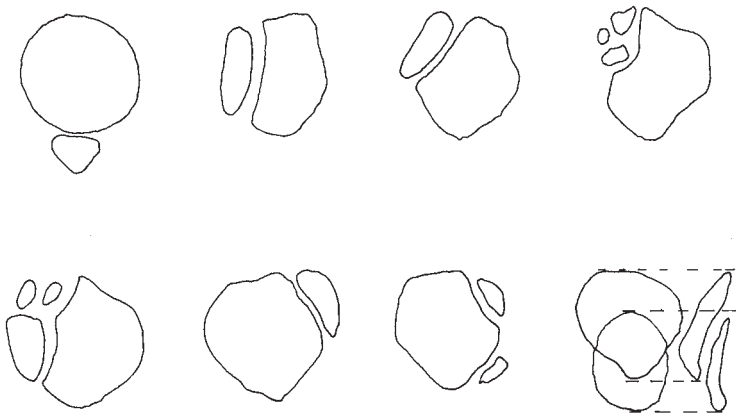


- | | |
|--------------------------------|--------------------------|
| 1 Femoral shaft | 8 Intercondylar eminence |
| 2 Medial margin of the patella | 9 Tibiofibular joint |
| 3 Lateral femoral condyle | 10 Medial tibial condyle |
| 4 Intercondylar fossa | 11 Fibular head |
| 5 Knee (joint space) | 12 Tibial shaft |
| 6 Medial femoral condyle | 13 Fibular shaft |
| 7 Lateral tibial condyle | |

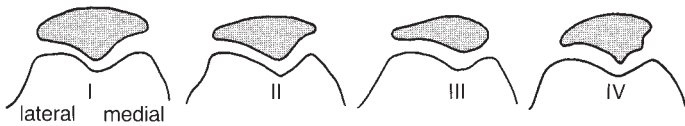



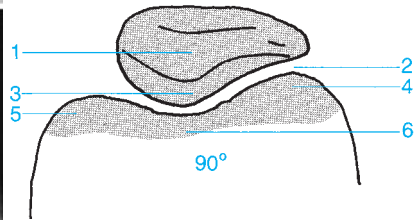
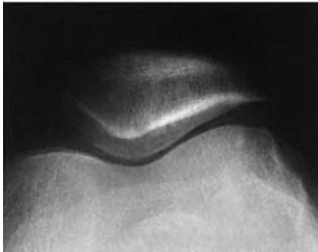
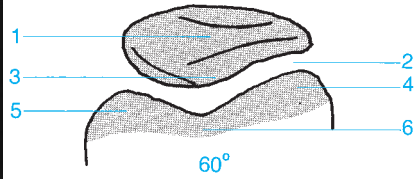
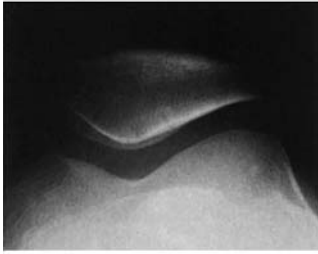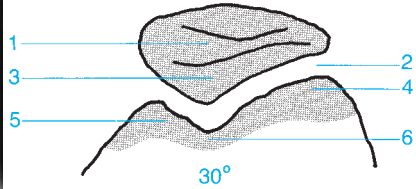
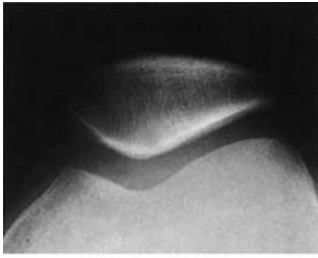
- | | |
|--|---------------------------------|
| 1 Femoral shaft | 7 Knee (joint space) |
| 2 Intercondylar fossa | 8 Medial tibial condyle |
| 3 Lateral margin of the patella | 9 Lateral tibial condyle |
| 4 Medial femoral condyle | 10 Fibular head |
| 5 Lateral femoral condyle | 11 Fibular shaft |
| 6 Intercondylar eminence | 12 Tibial shaft |



Most common forms of multipartite patella (as described by Schaer)

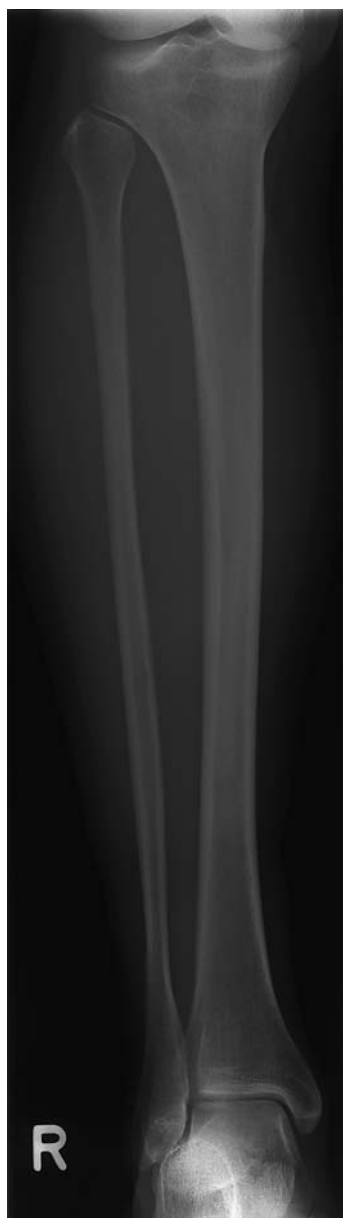

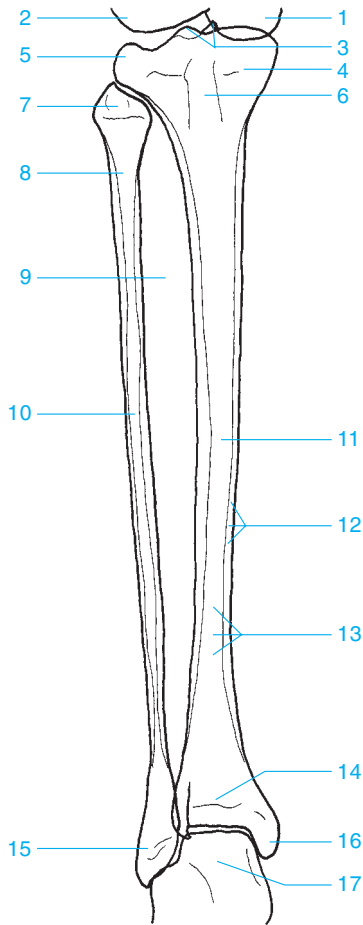
Wiberg's classification of patellar shapes (right knee)



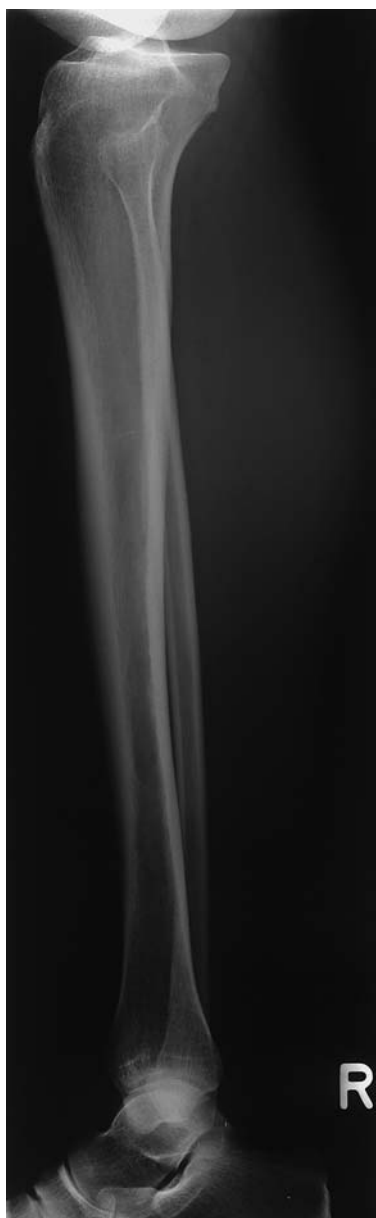- 1 Patella
- 2 Patellofemoral joint
- 3 Articular surface

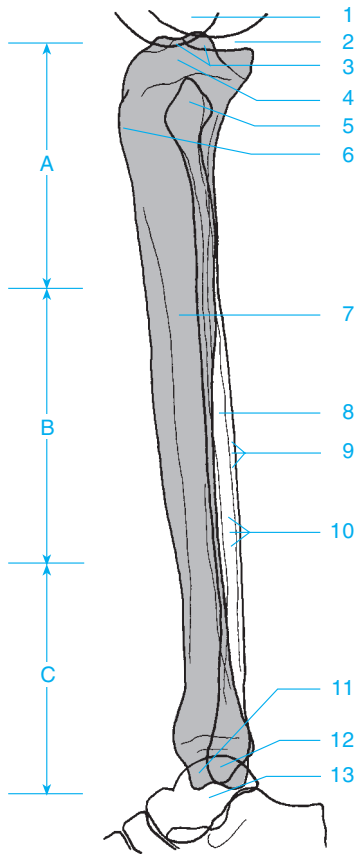
- 4 Lateral femoral condyle (generally larger)
- 5 Medial femoral condyle
- 6 Intercondylar fossa





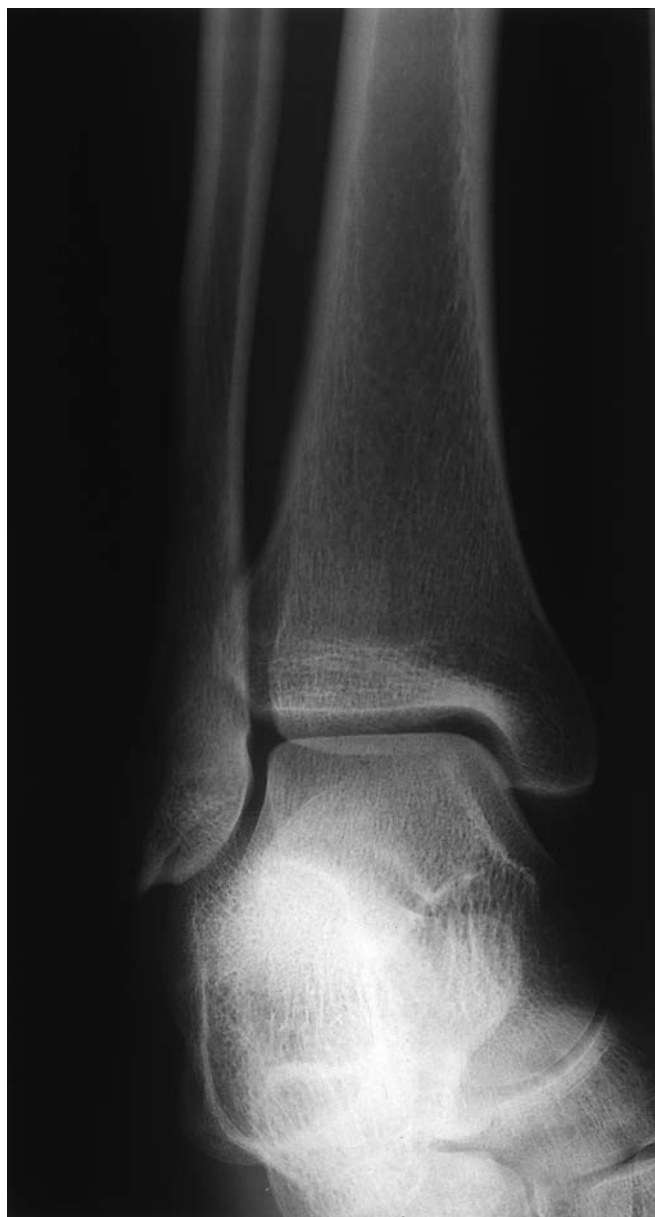- | | |
|--|-------------------------|
| 1 Medial femoral condyle | 9 Interosseous membrane |
| 2 Lateral femoral condyle | 10 Fibula |
| 3 Medial and lateral tubercles of the intercondylar eminence | 11 Tibia |
| 4 Medial tibial condyle | 12 Cortex |
| 5 Lateral tibial condyle | 13 Medullary canal |
| 6 Tibial tuberosity | 14 Growth plate |
| 7 Fibular head | 15 Lateral malleolus |
| 8 Fibular neck | 16 Medial malleolus |
| | 17 Talus |

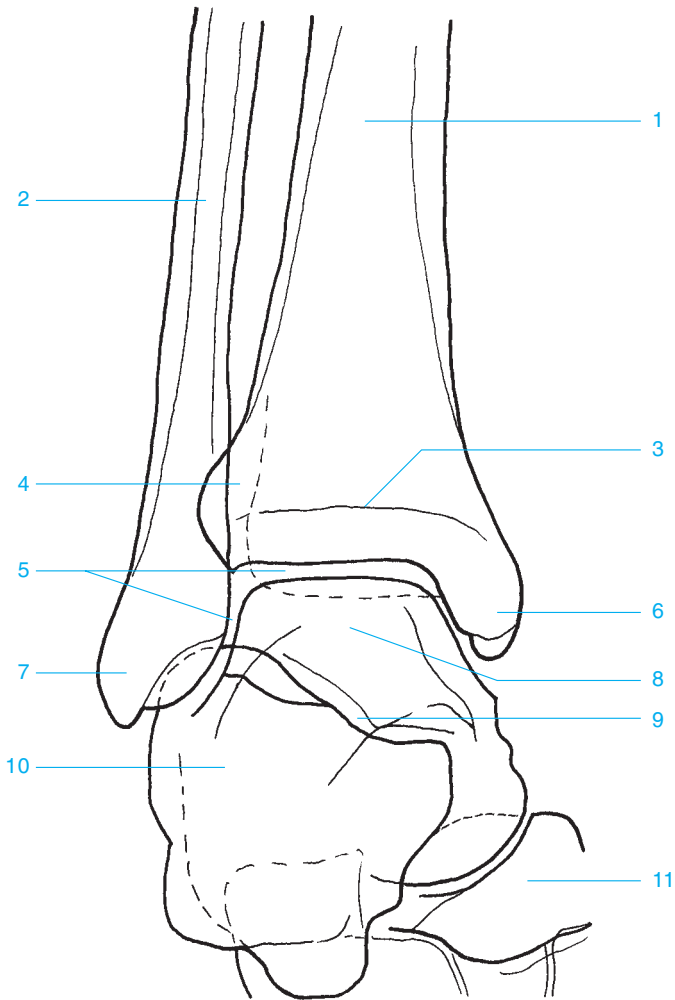




- A** Proximal third of the lower leg
B Middle third of the lower leg
C Distal third of the lower leg
1 Medial and lateral femoral condyles
2 Knee
3 Intercondylar eminence
4 Medial and lateral tibial condyles
5 Fibular head

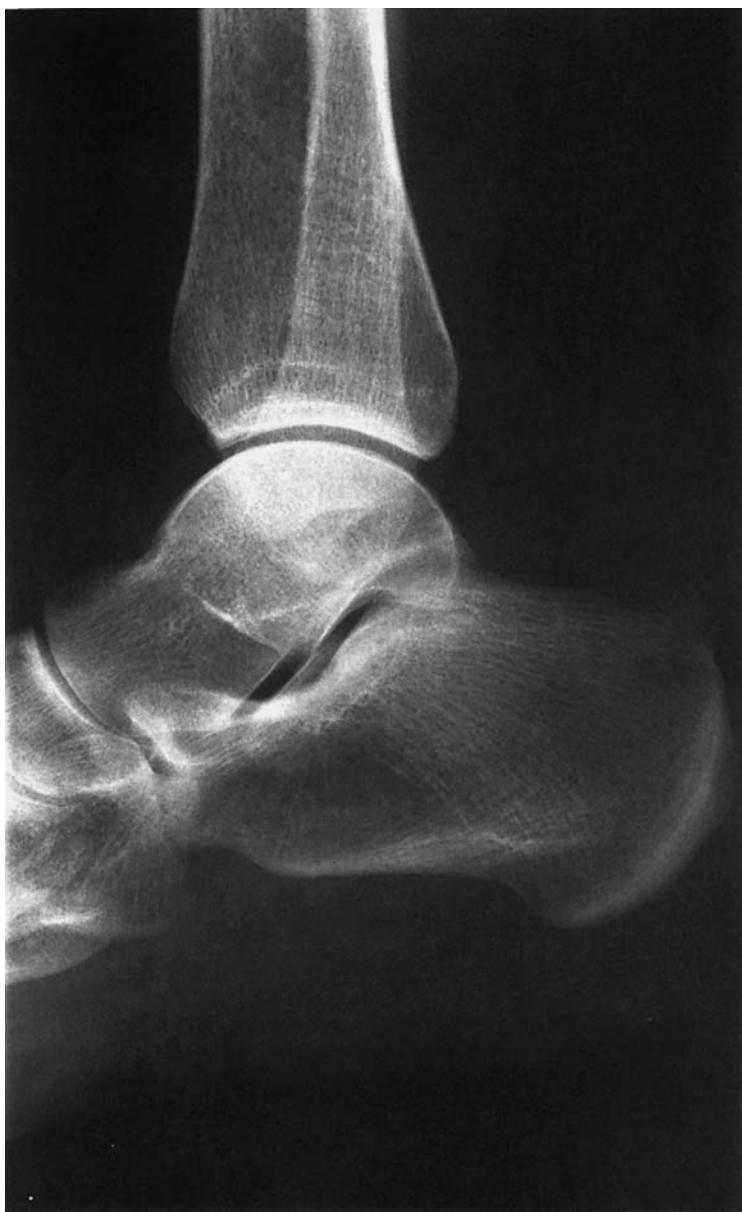
- 6** Proximal tibial apophysis (in children)
7 Tibia
8 Fibula
9 Cortex
10 Medullary canal
11 Medial malleus
12 Lateral malleus
13 Talus

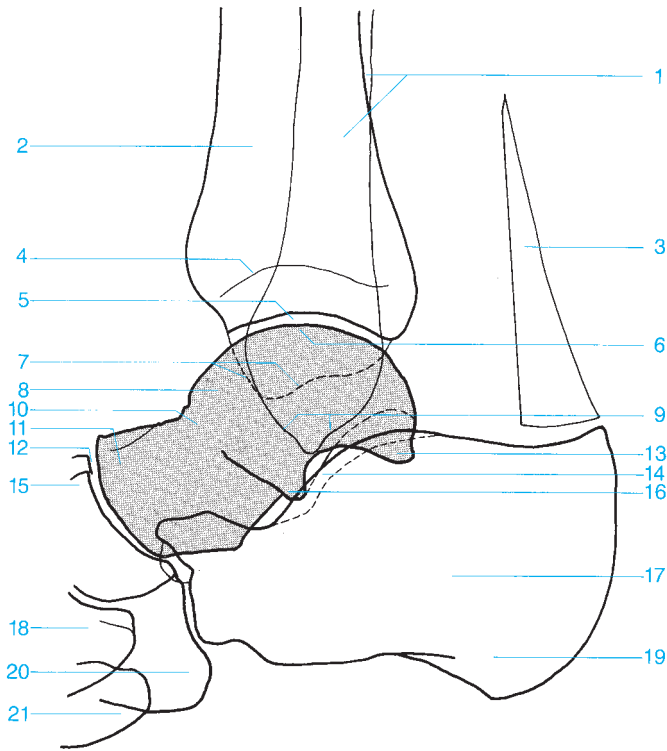




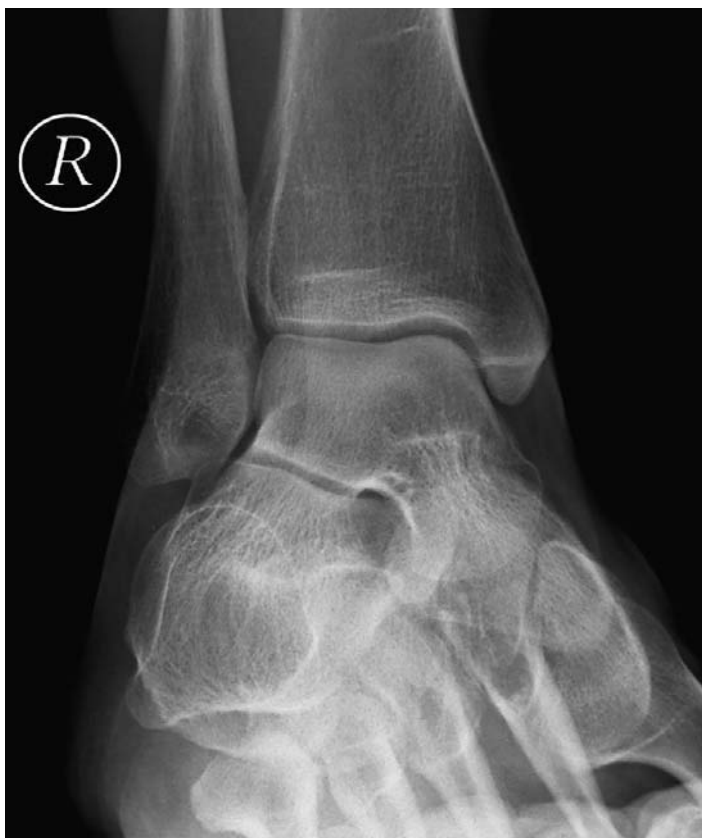- 1** Tibia
- 2** Fibula
- 3** Growth plate
- 4** Fibular notch
- 5** Ankle
- 6** Medial malleolus

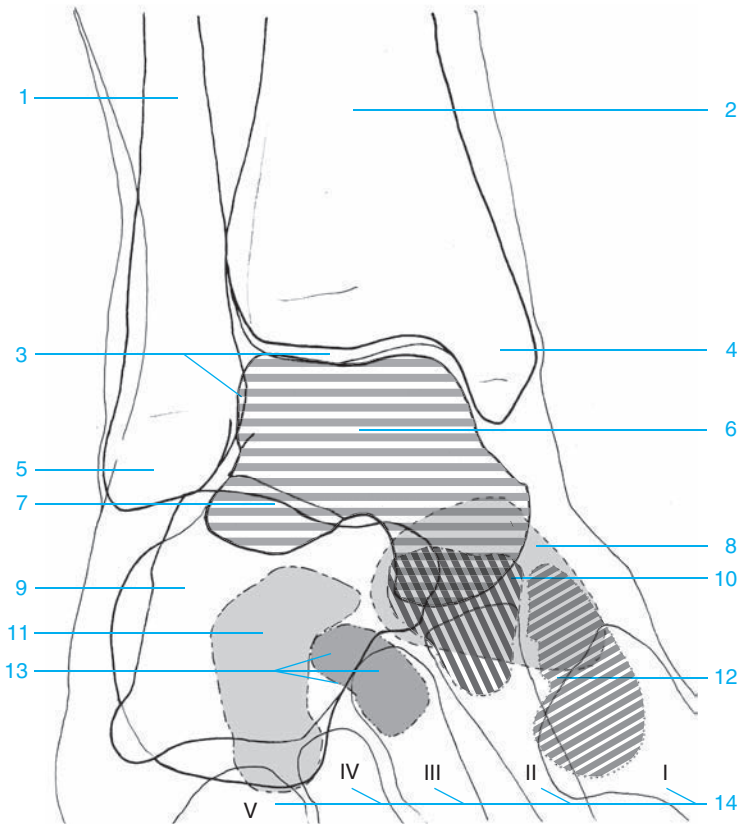
- 7** Lateral malleolus
- 8** Trochlea of the talus
- 9** Subtalar joint
- 10** Calcaneus
- 11** Navicular





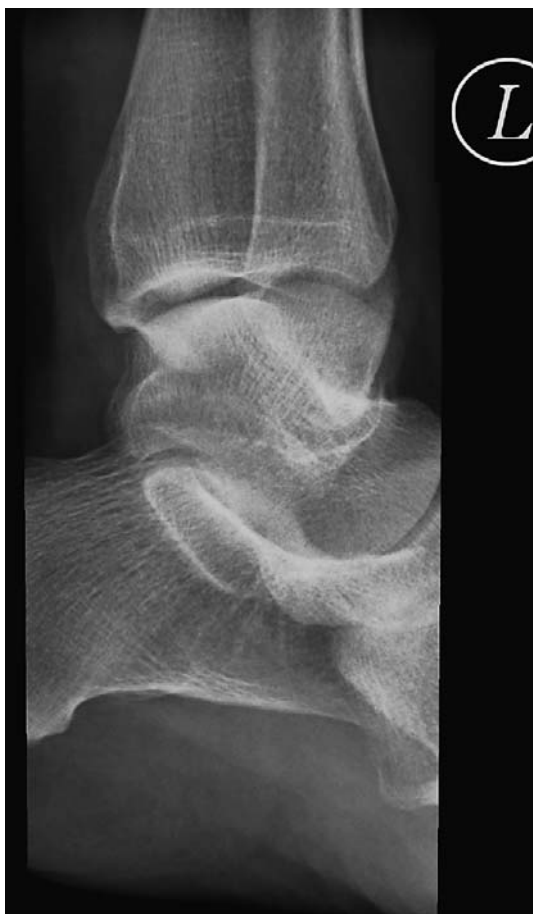- | | |
|--------------------------------|---|
| 1 Fibula | 13 Posterior process of the talus |
| 2 Tibia | 14 Sinus tarsi |
| 3 Achilles tendon | 15 Navicular |
| 4 Growth plate | 16 Lateral process of the talus |
| 5 Ankle | 17 Calcaneus |
| 6 Trochlea of the talus | 18 Medial cuneiform |
| 7 Medial malleolus | 19 Posterior tuberosity of the calcaneus |
| 8 Talus | 20 Cuboid |
| 9 Lateral malleolus | 21 Base of the fifth metatarsal |
| 10 Neck of the talus | |
| 11 Head of the talus | |
| 12 Talonavicular joint | |

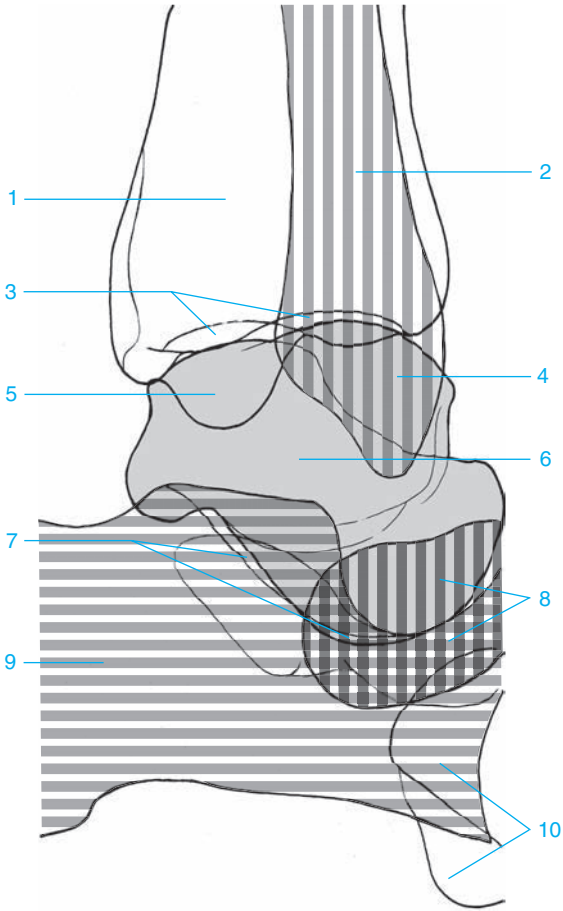








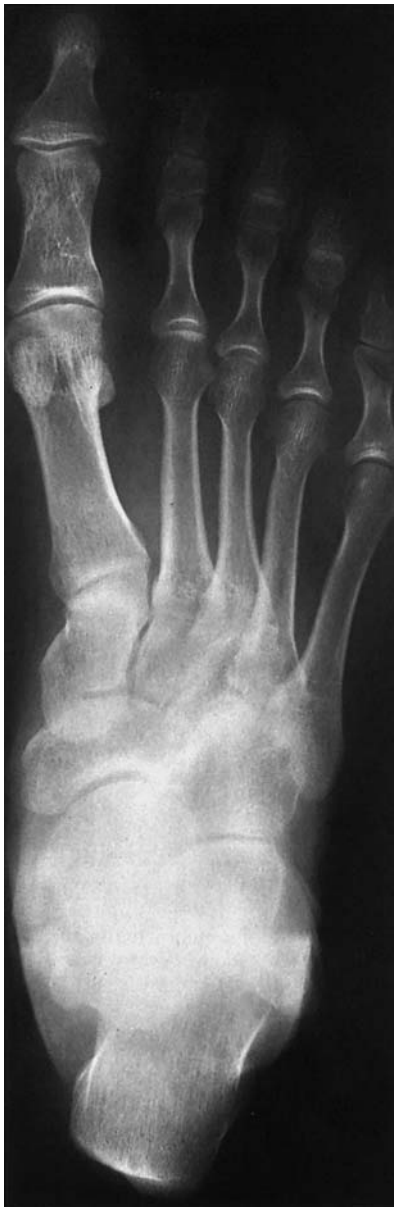- 1 Fibula
- 2 Tibia
- 3 Ankle joint space (talocrural joint)
- 4 Medial malleolus
- 5 Lateral malleolus
- 6 Talus
- 7 Talocalcaneal joint (posterior portion of the subtalar joint)

- 8 Navicular
- 9 Calcaneus
- 10 Middle cuneiform
- 11 Cuboid
- 12 Medial cuneiform
- 13 Lateral cuneiform
- 14 Metatarsals

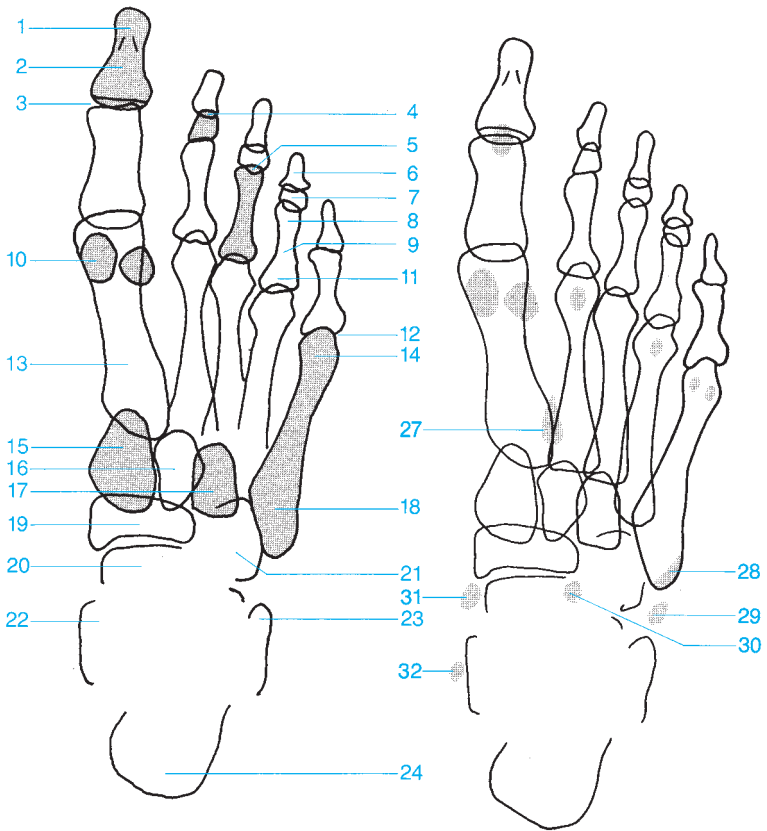




- | | |
|--|---|
| 1 Tibia | 7 Talocalcaneal joint (posterior portion of the subtalar joint) |
| 2 Fibula  | 8 Navicular  |
| 3 Ankle joint space (talocrural joint) | 9 Calcaneus  |
| 4 Lateral malleolus | 10 Cuboid |
| 5 Medial malleolus | |
| 6 Talus  | |

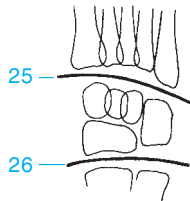


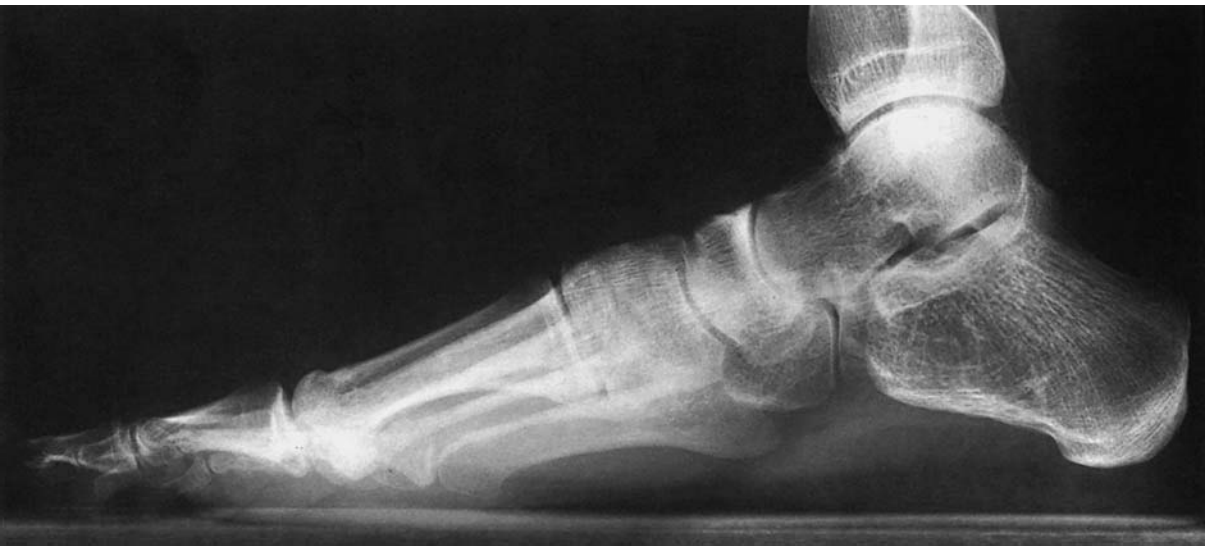- 1 Distal phalanx (tuft)
- 2 Distal phalanx of the great toe
- 3 Distal interphalangeal joint of the great toe
- 4 Distal interphalangeal joint
- 5 Proximal interphalangeal joint
- 6 Distal phalanx
- 7 Middle phalanx
- 8 Head of the proximal phalanx
- 9 Proximal phalanx
- 10 Sesamoid
- 11 Base of the phalanx
- 12 Metatarsophalangeal joint
- 13 Metatarsal
- 14 Metatarsal head
- 15 Medial cuneiform
- 16 Middle cuneiform
- 17 Lateral cuneiform
- 18 Base of the fifth metatarsal
- 19 Navicular
- 20 Head of the talus
- 21 Cuboid
- 22 Medial malleolus
- 23 Lateral malleolus
- 24 Calcaneus
- 25 Tarsometatarsal joints (Lisfranc's joints)
- 26 Transverse tarsal joint (Chopart's joint)



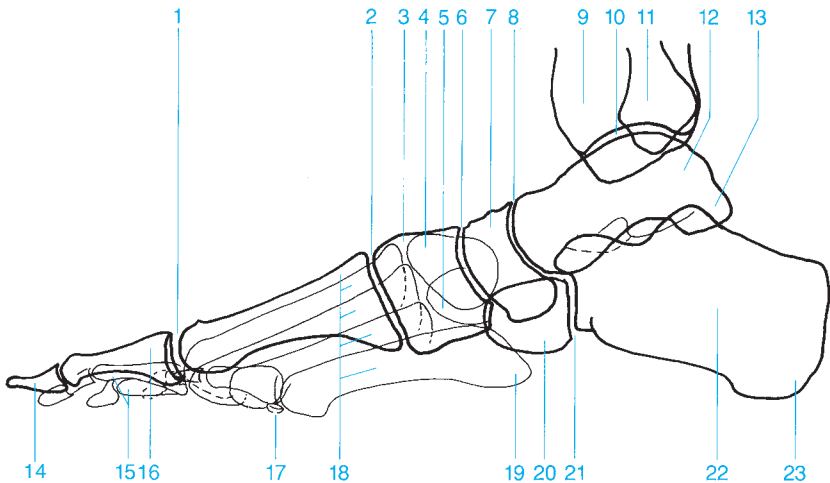
Common sesamoids and accessory bones in the foot

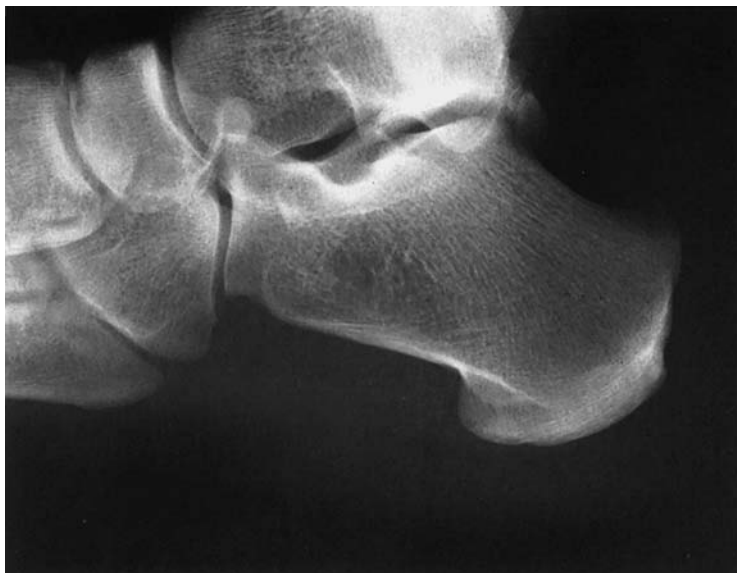
- 27 Os intermetatarsium
- 28 Os vesalianum
- 29 Os peroneum
- 30 Secondary cuboid
- 31 Os tibiale externum
- 32 Os supratalare

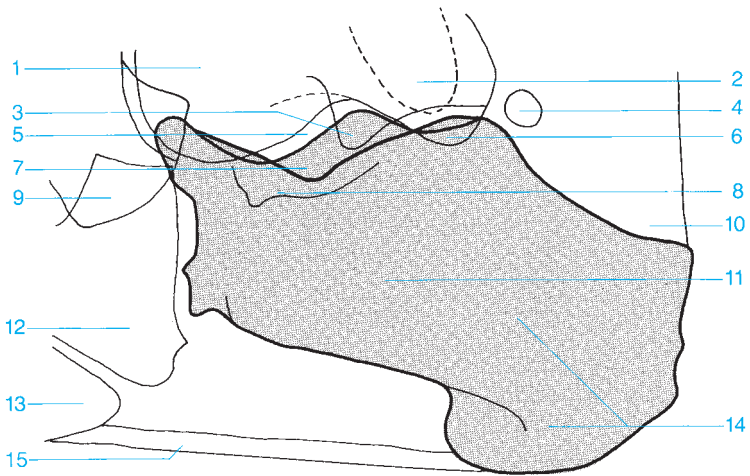




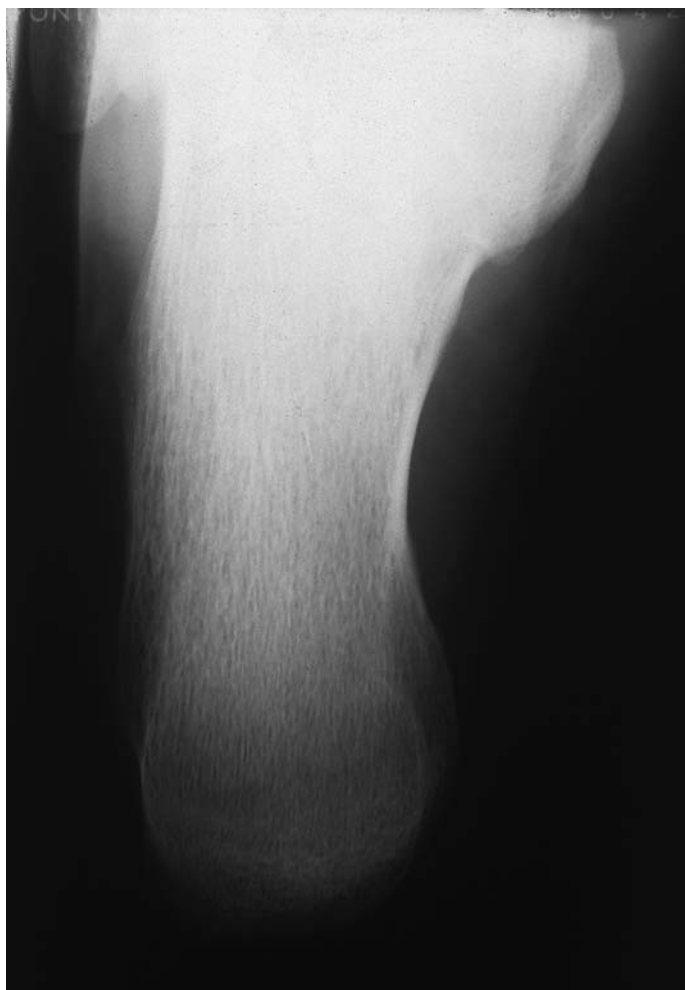- 1 Metatarsophalangeal joint
- 2 Tarsometatarsal joint
- 3 Medial cuneiform
- 4 Middle cuneiform
- 5 Lateral cuneiform
- 6 Cuneonavicular joint
- 7 Navicular
- 8 Talocalcaneonavicular joint
- 9 Tibia
- 10 Ankle
- 11 Fibula
- 12 Talus
- 13 Posterior process of the talus
- 14 Distal phalanx
- 15 Middle phalanx
- 16 Proximal phalanx
- 17 Sesamoid
- 18 Metatarsal
- 19 Base of fifth metatarsal
- 20 Cuboid
- 21 Calcaneocuboid joint
- 22 Calcaneus
- 23 Posterior tuberosity of the calcaneus

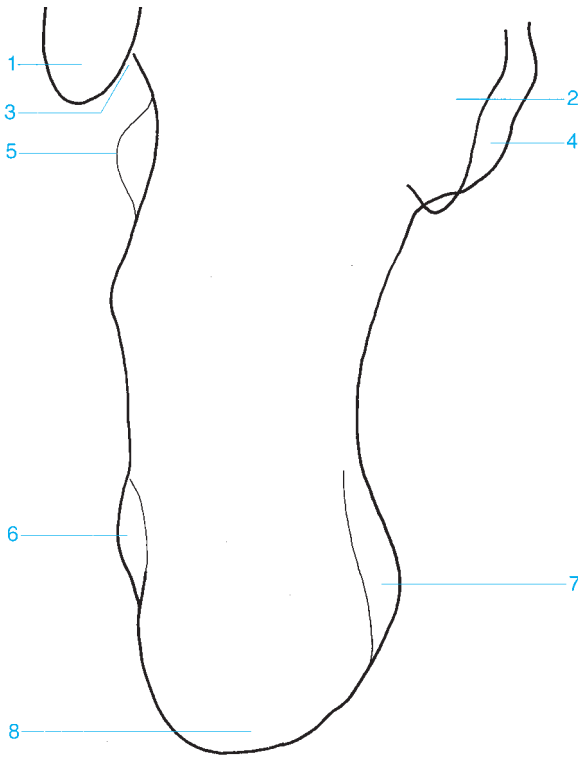






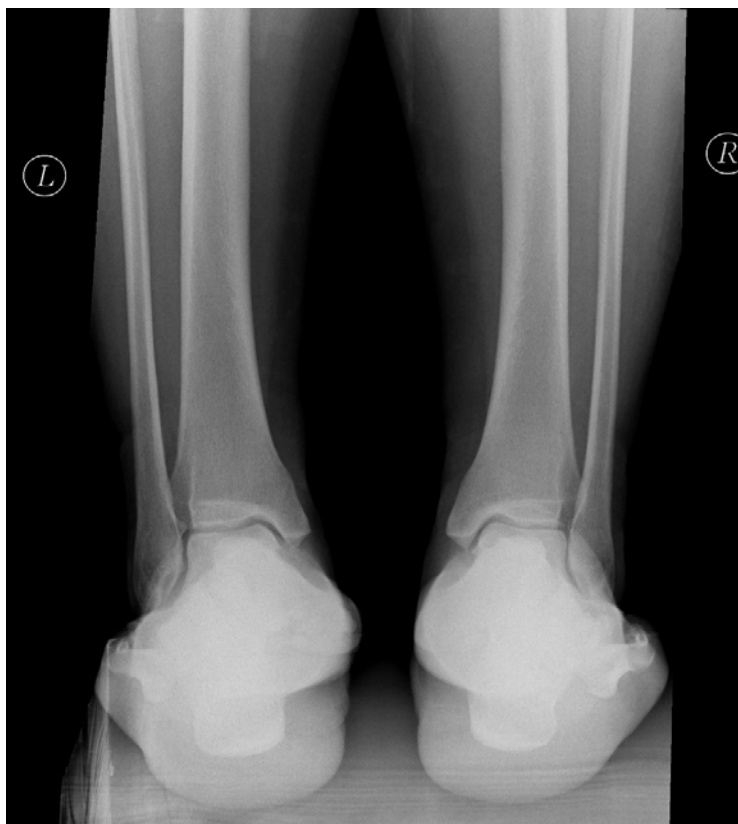- | | |
|---|---|
| 1 Talus | 9 Navicular |
| 2 Lateral malleolus | 10 Achilles tendon |
| 3 Lateral process of the talus | 11 Calcaneus |
| 4 Os trigonum | 12 Cuboid |
| 5 Subtalar joint | 13 Base of fifth metatarsal |
| 6 Posterior process of the talus | 14 Posterior tuberosity of the calcaneus |
| 7 Sinus tarsi | 15 Plantar aponeurosis |
| 8 Sustentaculum tali | |

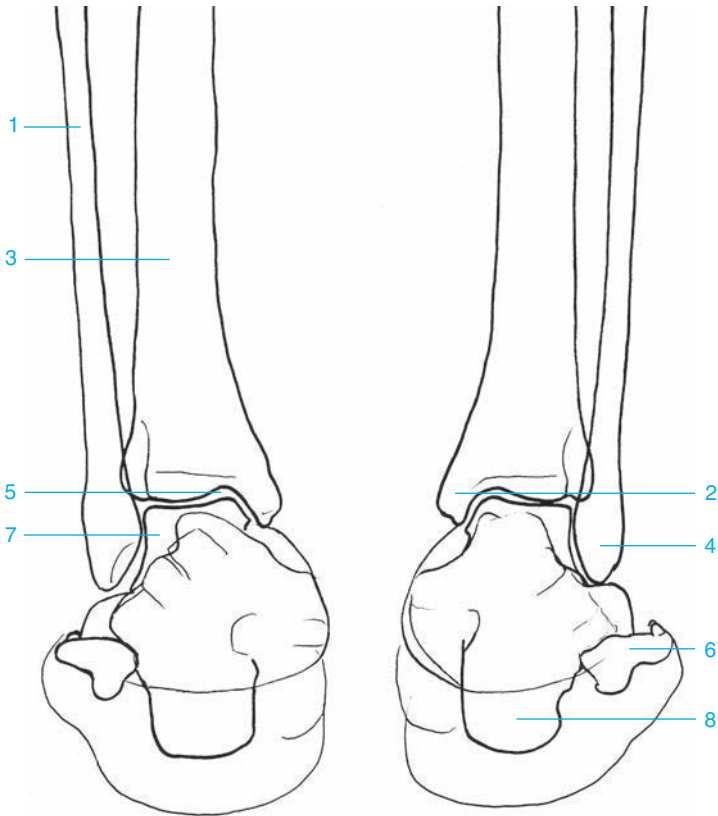




- 1 Lateral malleolus
- 2 Talus
- 3 Groove for the peroneus longus tendon
- 4 Sustentaculum tali
- 5 Peroneal trochlea

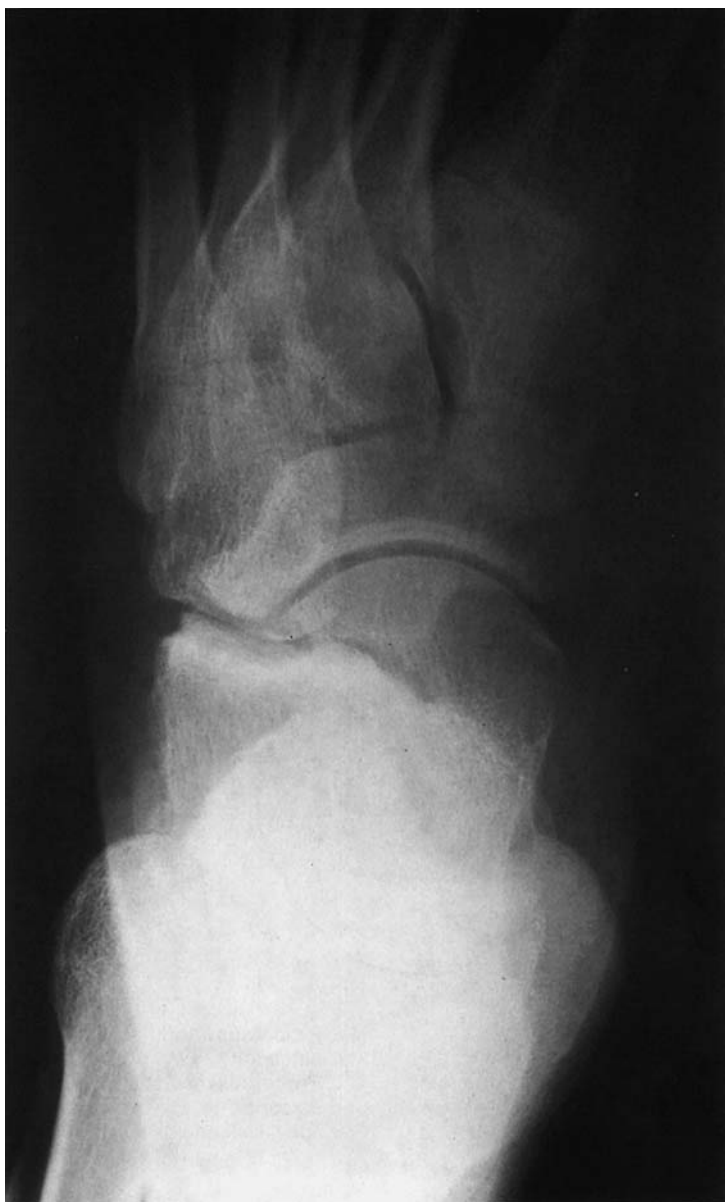- 6 Lateral process of the posterior tuberosity of the calcaneus
- 7 Medial process of the posterior tuberosity of the calcaneus
- 8 Posterior tuberosity of the calcaneus

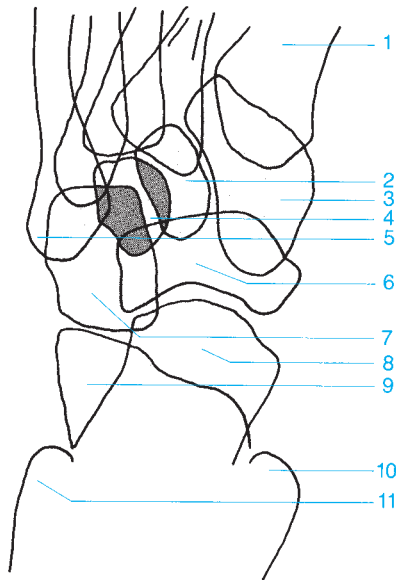




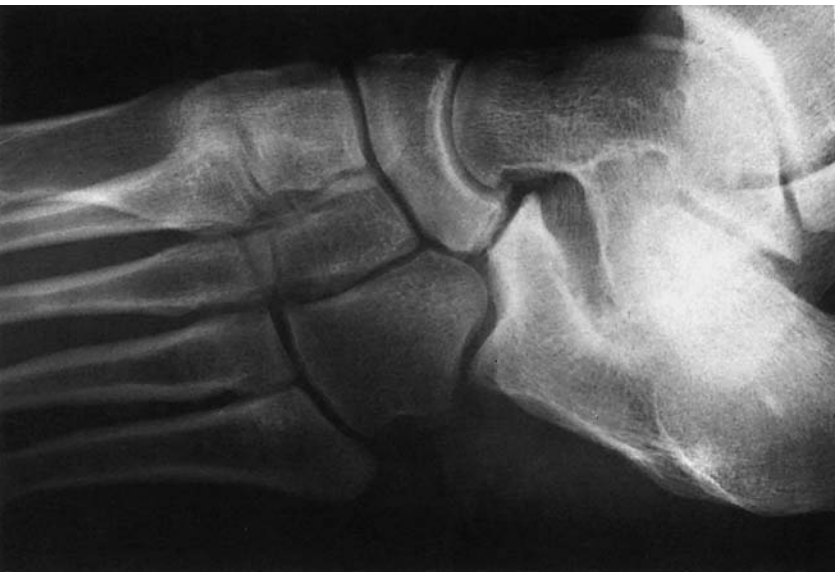- 1 Fibula
- 2 Medial malleolus
- 3 Tibia
- 4 Lateral malleolus

- 5 Ankle joint space (talocrural joint)
- 6 Fifth metatarsal
- 7 Talus
- 8 Calcaneus

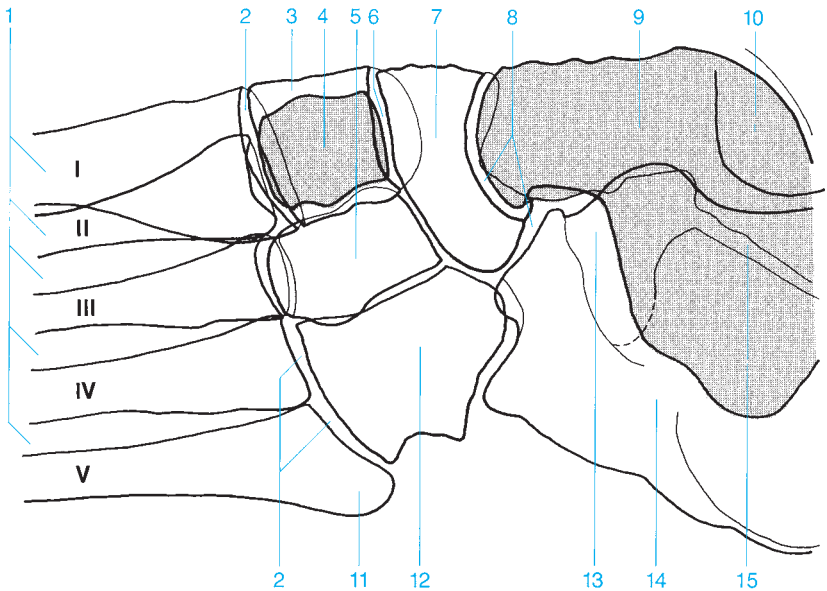


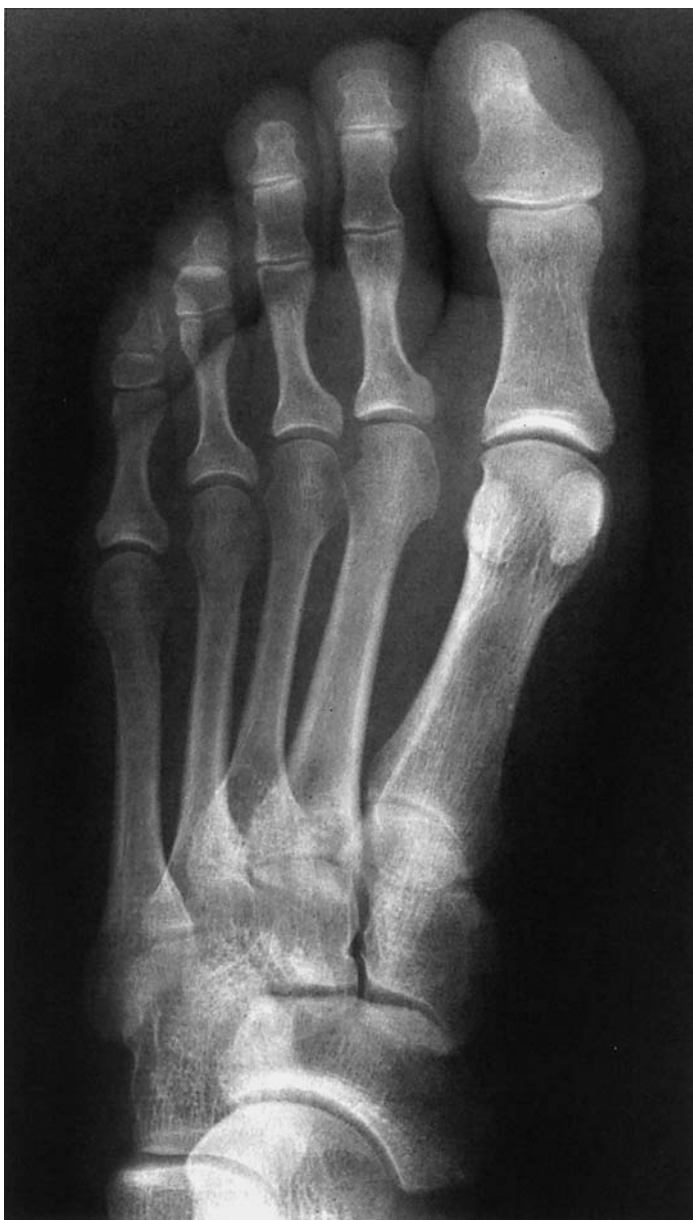

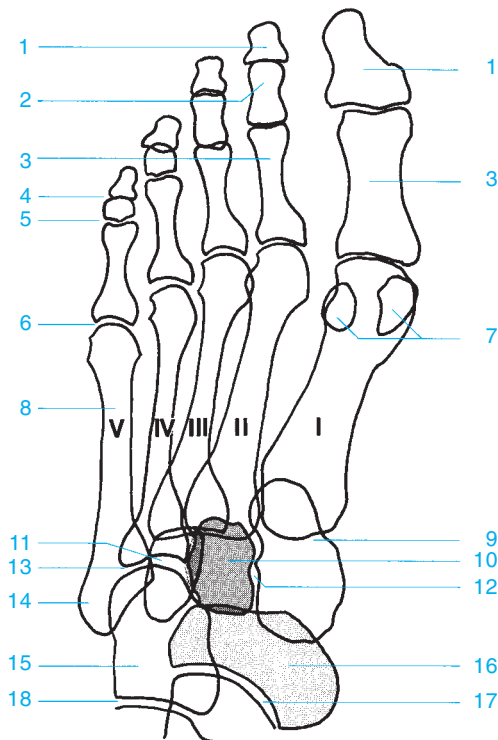
- | | |
|---------------------------------------|-----------------------------|
| 1 Metatarsal | 7 Cuboid |
| 2 Middle cuneiform | 8 Head of the talus |
| 3 Medial cuneiform | 9 Calcaneus |
| 4 Lateral cuneiform | 10 Medial malleolus |
| 5 Base of the fifth metatarsal | 11 Lateral malleolus |
| 6 Navicular | |



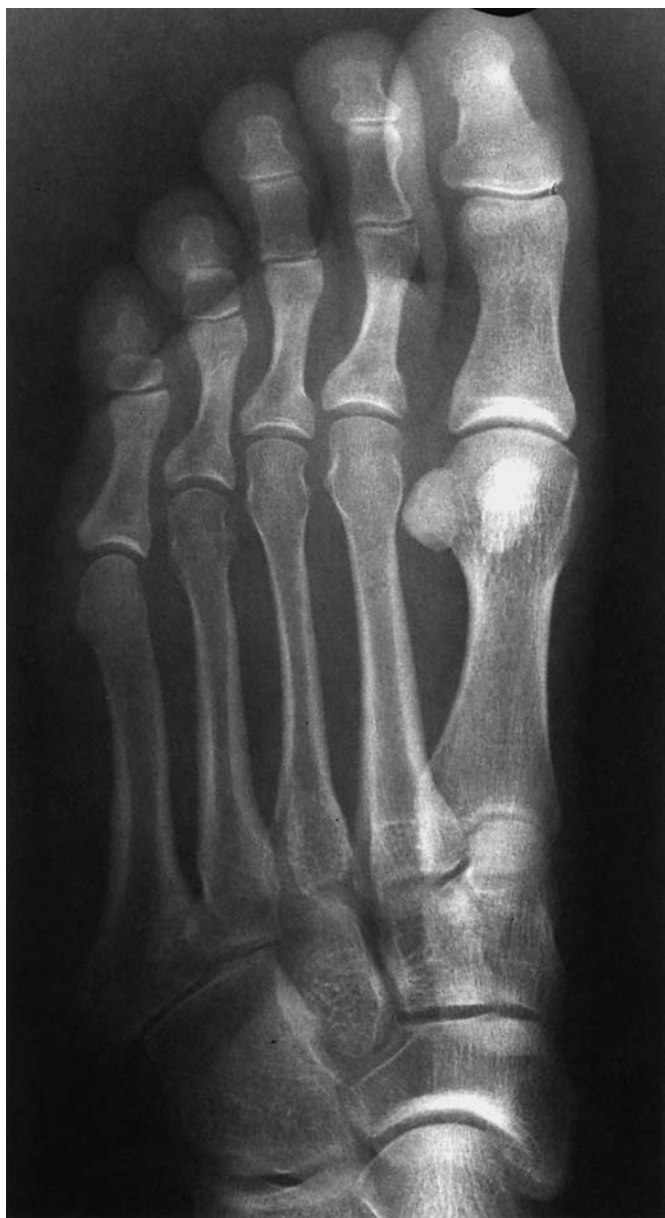- 1 Metatarsals
- 2 Tarsometatarsal joint
- 3 Medial cuneiform
- 4 Middle cuneiform
- 5 Lateral cuneiform
- 6 Cuneonavicular joint
- 7 Navicular
- 8 Talocalcaneonavicular joint
- 9 Talus
- 10 Malleolus
- 11 Base of the fifth metatarsal
- 12 Cuboid
- 13 Sinus tarsi
- 14 Calcaneus
- 15 Subtalar joint (and talocalcaneonavicular joint)

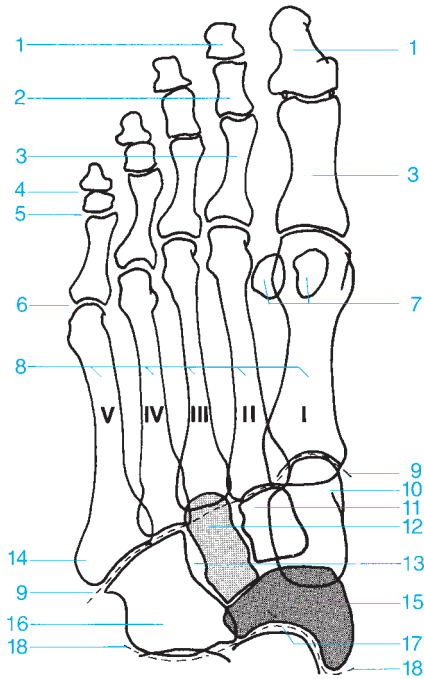




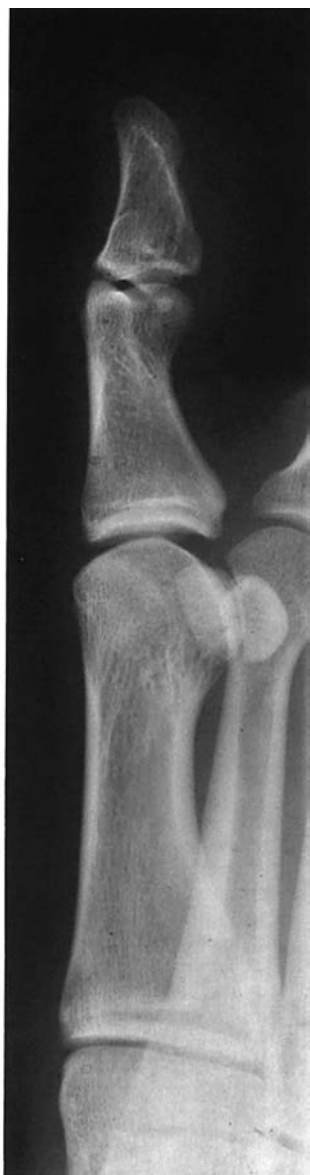
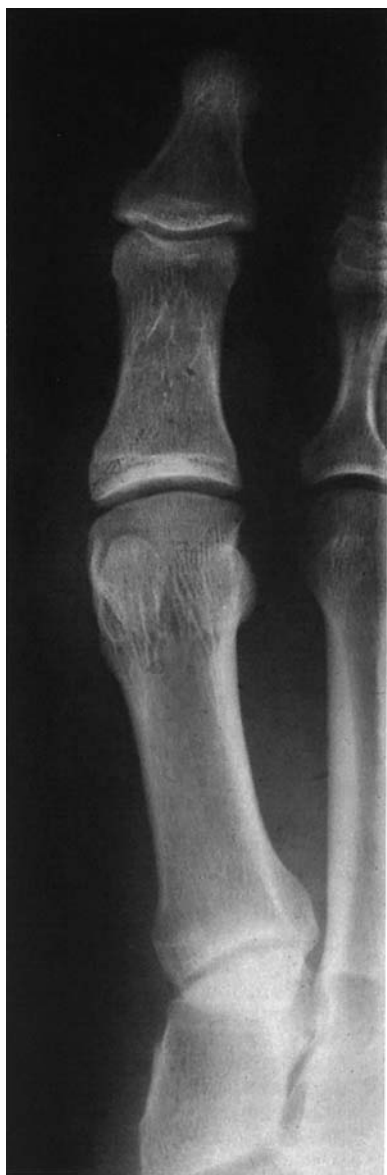
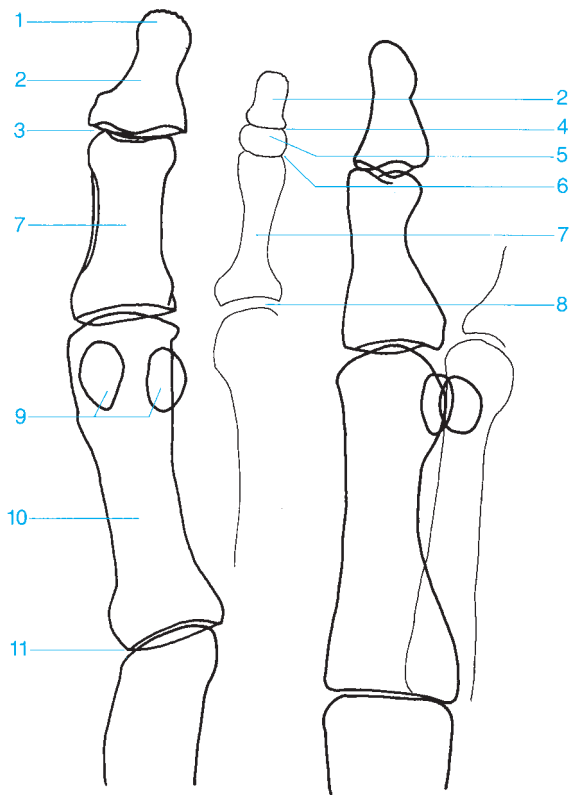
- | | |
|----------------------------------|---------------------------------|
| 1 Distal phalanx | 10 Middle cuneiform |
| 2 Middle phalanx | 11 Lateral cuneiform |
| 3 Proximal phalanx | 12 Intertarsal joint |
| 4 Distal interphalangeal joint | 13 Metatarsophalangeal joint |
| 5 Proximal interphalangeal joint | 14 Base of the fifth metatarsal |
| 6 Metatarsophalangeal joint | 15 Cuboid |
| 7 Sesamoids | 16 Navicular |
| 8 Metatarsals | 17 Talocalcaneonavicular joint |
| 9 Medial cuneiform | 18 Calcaneocuboid joint |





- | | |
|--|--|
| 1 Distal phalanx | 11 Middle cuneiform |
| 2 Middle phalanx | 12 Lateral cuneiform |
| 3 Proximal phalanx | 13 Intertarsal joint |
| 4 Distal interphalangeal joint | 14 Base of the fifth metatarsal |
| 5 Proximal interphalangeal joint | 15 Navicular |
| 6 Metatarsophalangeal joint | 16 Cuboid |
| 7 Sesamoids | 17 Talocalcaneonavicular joint |
| 8 Metatarsals | 18 Transverse tarsal joint (Chopart's joint between the talus, calcaneus, navicular, and cuboid) |
| 9 Tarsometatarsal joint (Lisfranc's joint) | |
| 10 Medial cuneiform | |





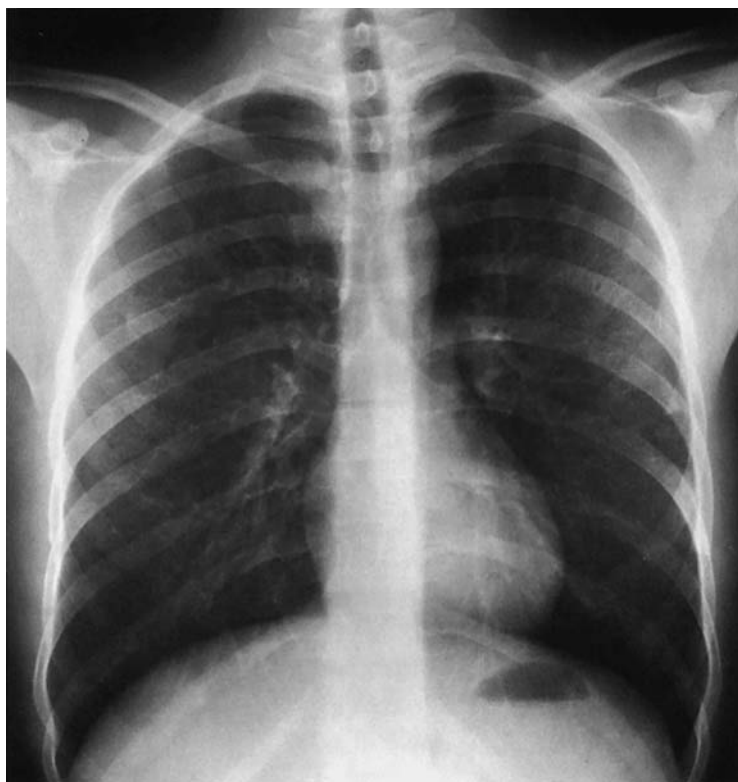- 1 Distal phalanx (tuft)
- 2 Distal phalanx
- 3 Interphalangeal joint of the great toe
- 4 Distal interphalangeal joint
- 5 Middle phalanx

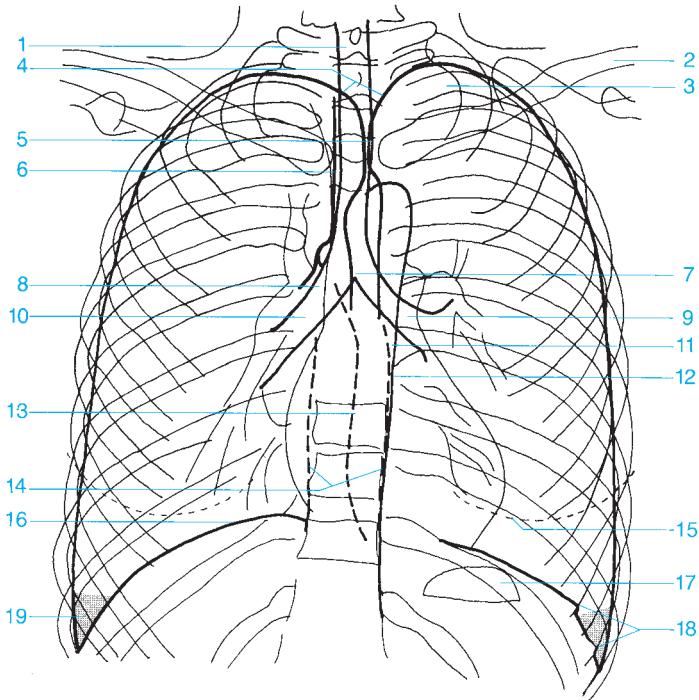
- 6 Proximal interphalangeal joint
- 7 Proximal phalanx
- 8 Metatarsophalangeal joint
- 9 Sesamoids
- 10 First metatarsal
- 11 Tarsometatarsal joint

This page intentionally left blank.

**Anatomy of Miscellaneous
Plain Films**

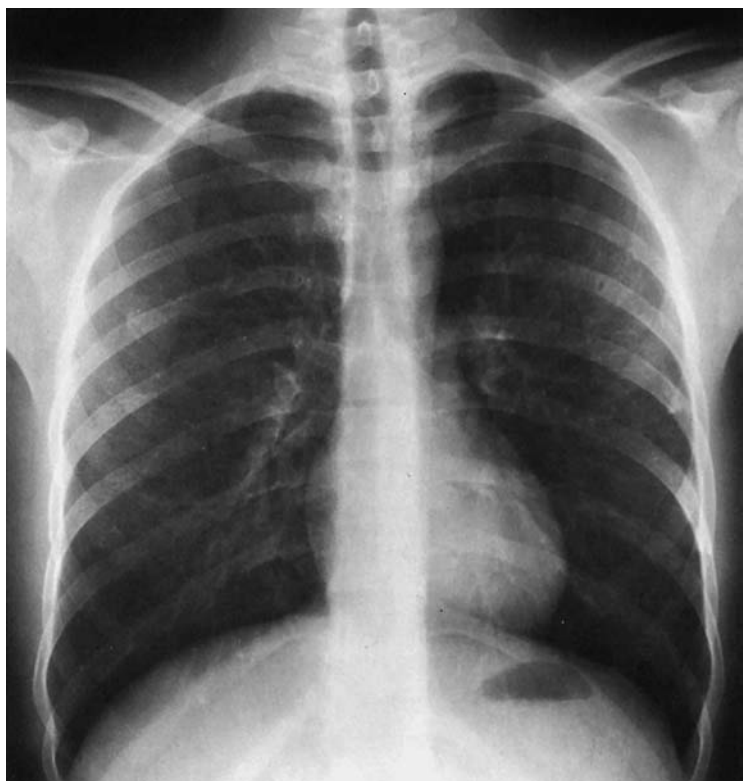
Routine Radiographs..... 208
Spot Images 224
Tomography..... 232

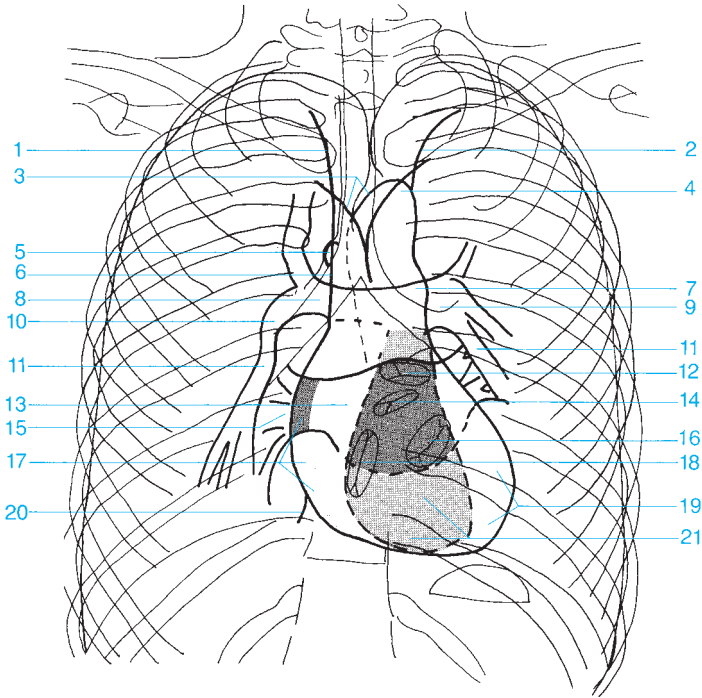




- 1 Trachea
- 2 Clavicle
- 3 Apex of the lung
- 4 Curve of the apex of the lung
- 5 Posterior border between the right and left lungs
- 6 Right paratracheal stripe
- 7 Carina of the trachea
- 8 Right main bronchus
- 9 Left main bronchus
- 10 Intermediate bronchus

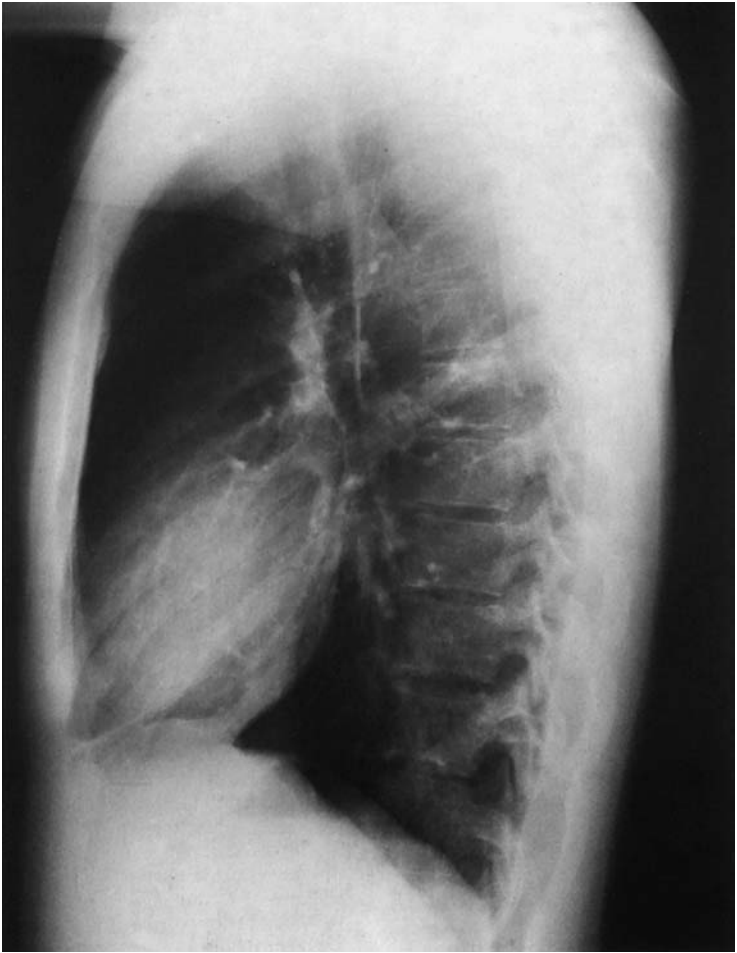
- 11 Paraortic stripe
- 12 Descending aorta
- 13 Azygoesophageal stripe
- 14 Paraspinal stripe
- 15 Shadow of the breast
- 16 Diaphragm
- 17 Gastric bubble
- 18 Insertions of the diaphragm
- 19 Costodiaphragmatic recess (costophrenic angle)



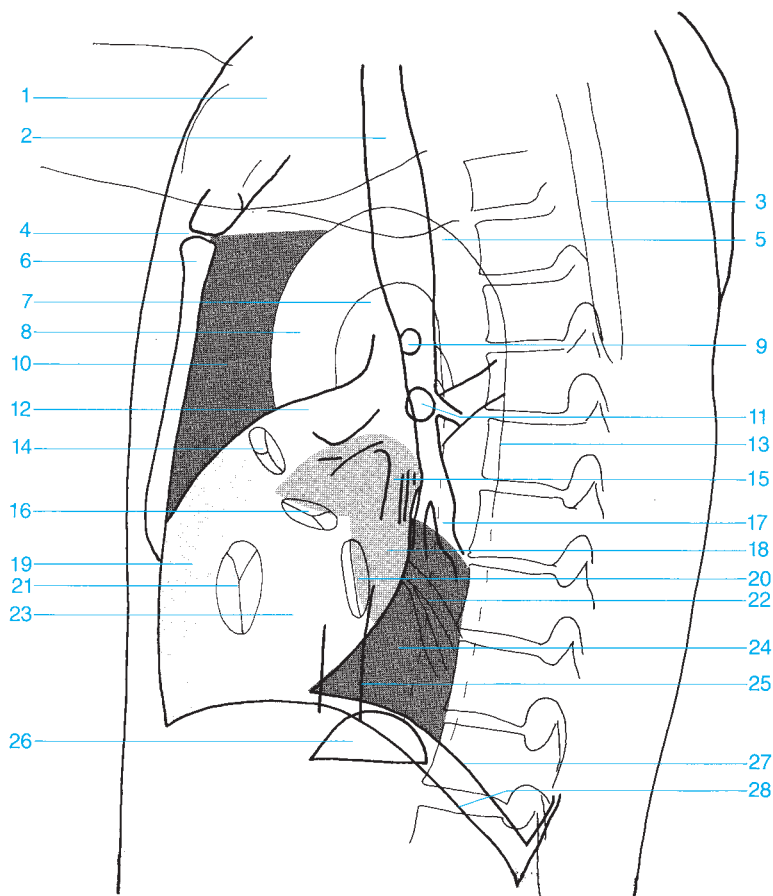


- 1 Contour of the right brachiocephalic vein
- 2 Contour of the subclavian artery
- 3 Subclavian and aortic arches
- 4 Aortic arch
- 5 Azygos vein
- 6 Superior vena cava
- 7 Main pulmonary artery
- 8 Right pulmonary artery
- 9 Left pulmonary artery
- 10 Intermediate part of the right pulmonary artery

- 11 Inferior lobar branch of the pulmonary artery
- 12 Pulmonary valve
- 13 Left atrium
- 14 Aortic valve
- 15 Venous confluence
- 16 Mitral valve
- 17 Right atrium
- 18 Tricuspid valve
- 19 Left ventricle
- 20 Inferior vena cava
- 21 Right ventricle

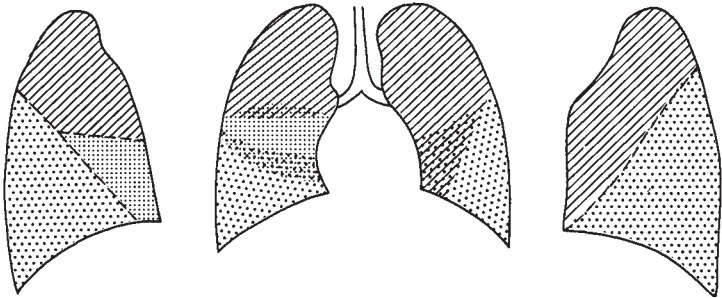
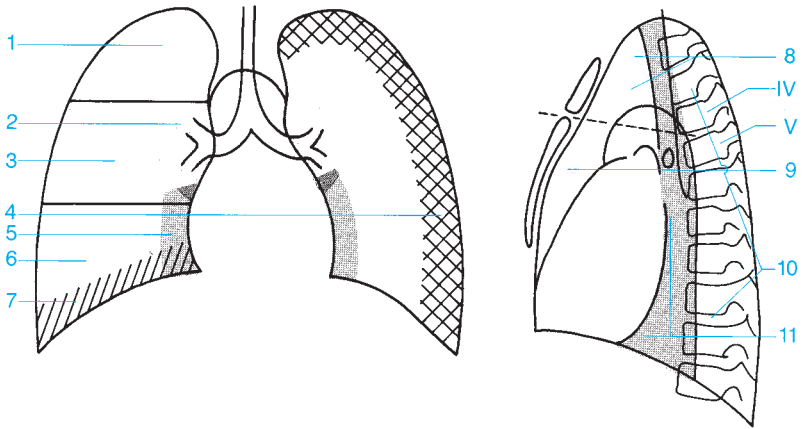


- | | |
|--------------------------------|-----------------------------|
| 1 Soft tissues of the shoulder | 9 Right upper lobe bronchus |
| 2 Trachea | 10 Retrosternal space |
| 3 Scapula | 11 Left upper lobe bronchus |
| 4 Sternal angle | 12 Main pulmonary artery |
| 5 Aortic arch | 13 Descending aorta |
| 6 Body of the sternum | 14 Pulmonary valve |
| 7 Aortopulmonary window | 15 Pulmonary veins |
| 8 Ascending aorta | 16 Aortic valve |



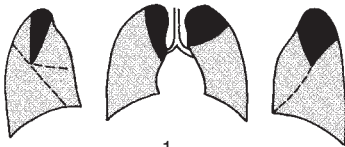
17 Lower lobe bronchus
18 Left atrium
19 Right ventricle
20 Mitral valve
21 Tricuspid valve
22 Pulmonary veins
23 Left ventricle

24 Retrocardiac space
25 Inferior vena cava
26 Gastric bubble
27 Left hemidiaphragm (tangent to the gastric bubble and ending in the shadow of the heart)
28 Right hemidiaphragm



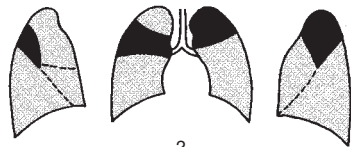
- 1 Upper region of the lung
- 2 Perihilar region
- 3 Middle region of the lung
- 4 Chest wall
- 5 Pericardial region
- 6 Lower region of the lung

- 7 Supradiaphragmatic region
- 8 Superior anterior mediastinum
- 9 Inferior anterior mediastinum
- 10 Posterior mediastinum
- 11 Middle mediastinum (fourth and fifth thoracic vertebrae)



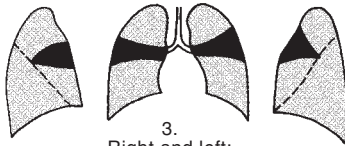
1.

Right: apical segment of the upper lobe
Left: apical posterior segment of the upper lobe



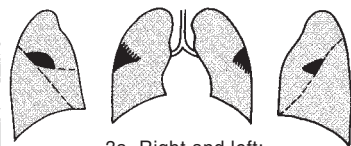
2.

Right: posterior segment of the upper lobe
Left: apical posterior segment of the upper lobe

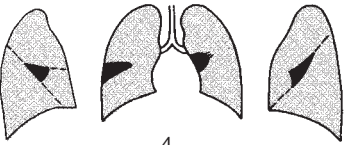


3.

Right and left:
anterior segment of the upper lobe

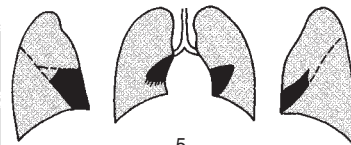


3a. Right and left:
axillary subsegment



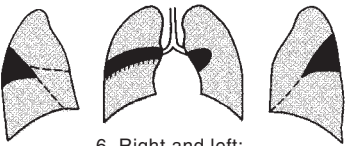
4.

Right: lateral segment of the middle lobe
Left: superior lingular segment



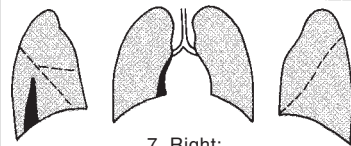
5.

Right medial segment of the middle lobe
Left: inferior lingular segment



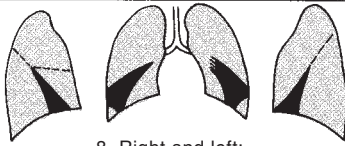
6. Right and left:

superior segment of the lower lobe



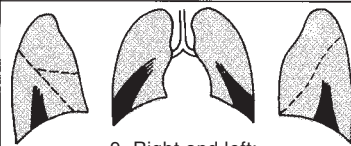
7. Right:

medial segment of the lower lobe



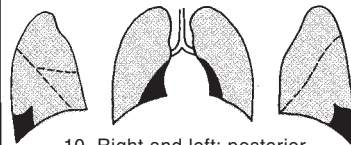8. Right and left:

anterior basal segment of the lower lobe



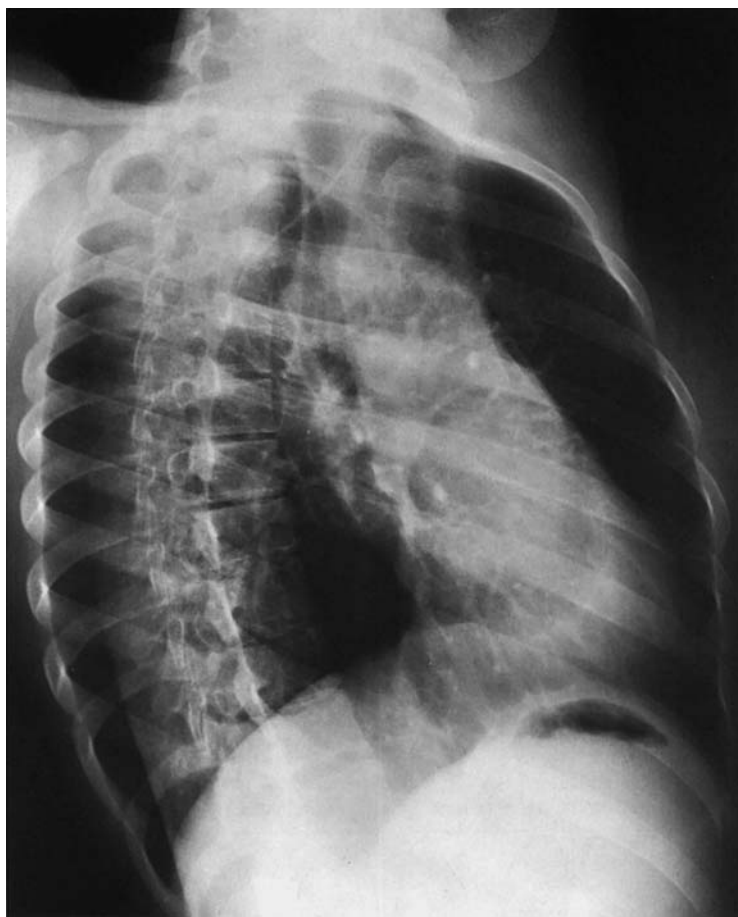9. Right and left:

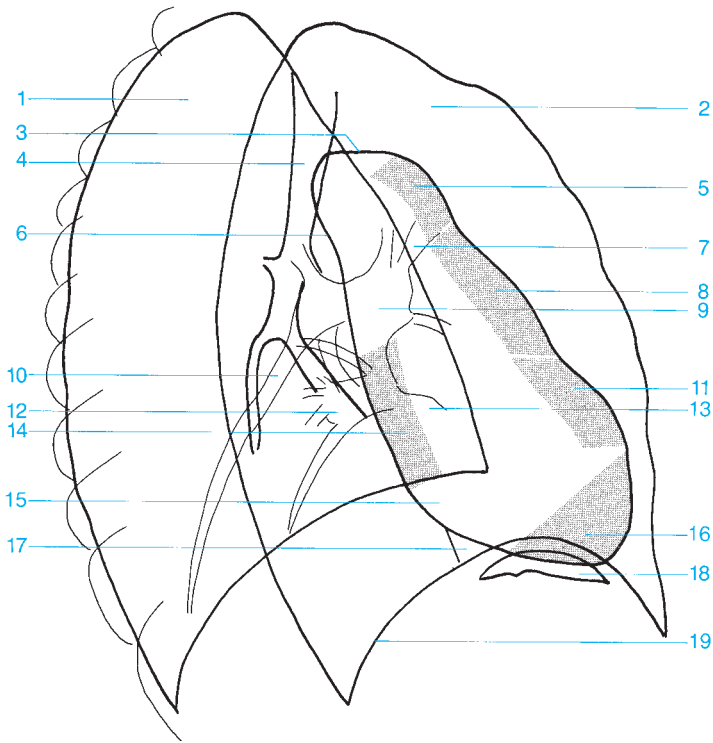
lateral basal segment of the lower lobe



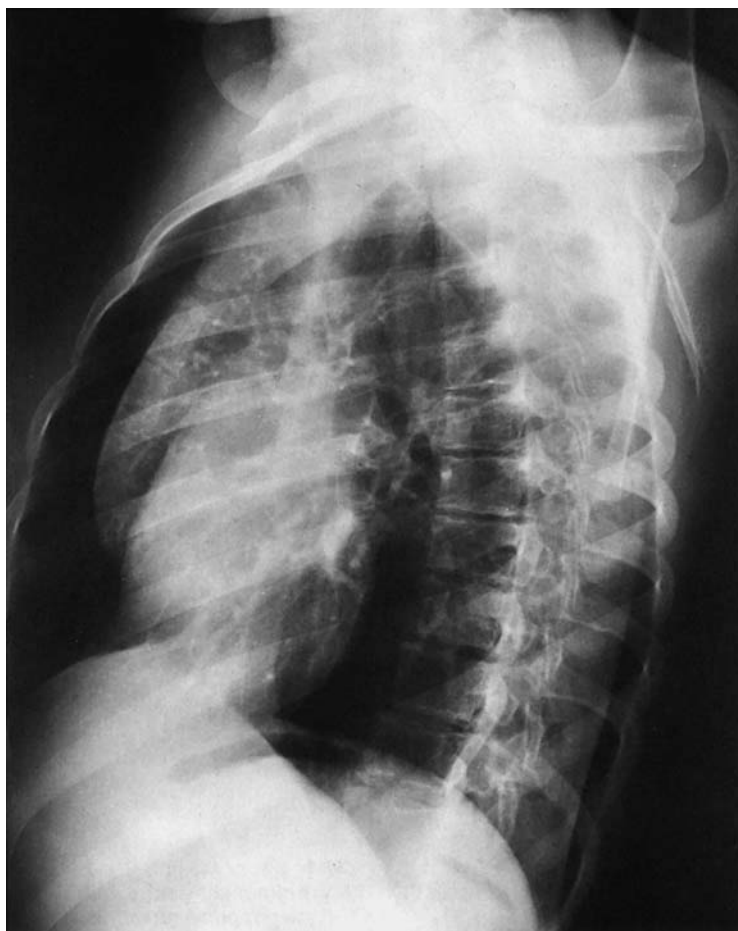10. Right and left: posterior basal segment of the lower lobe

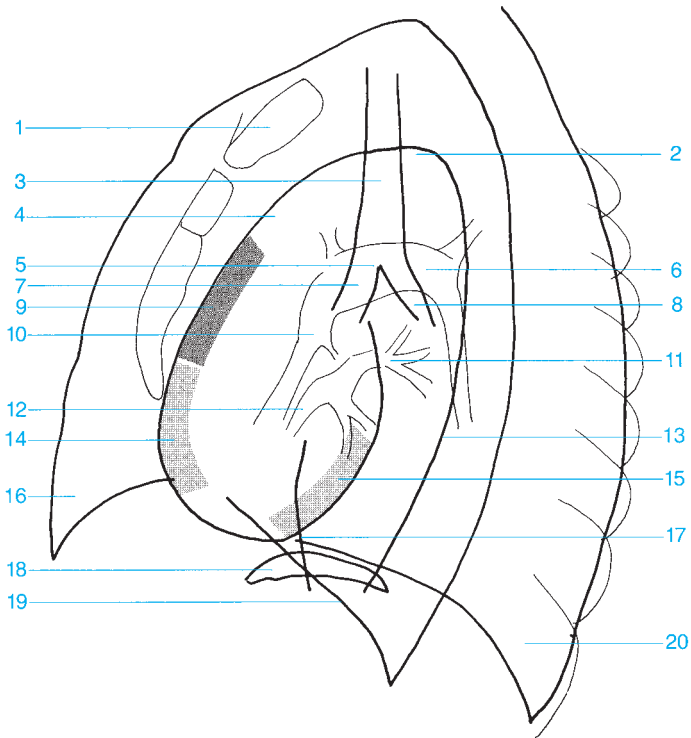
Segments of the lung



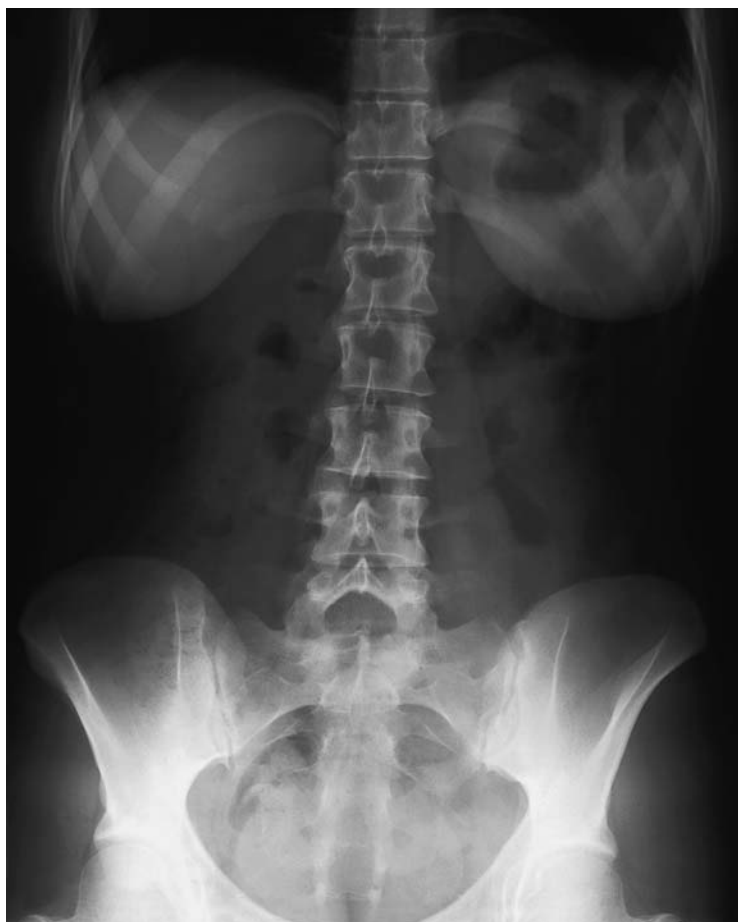

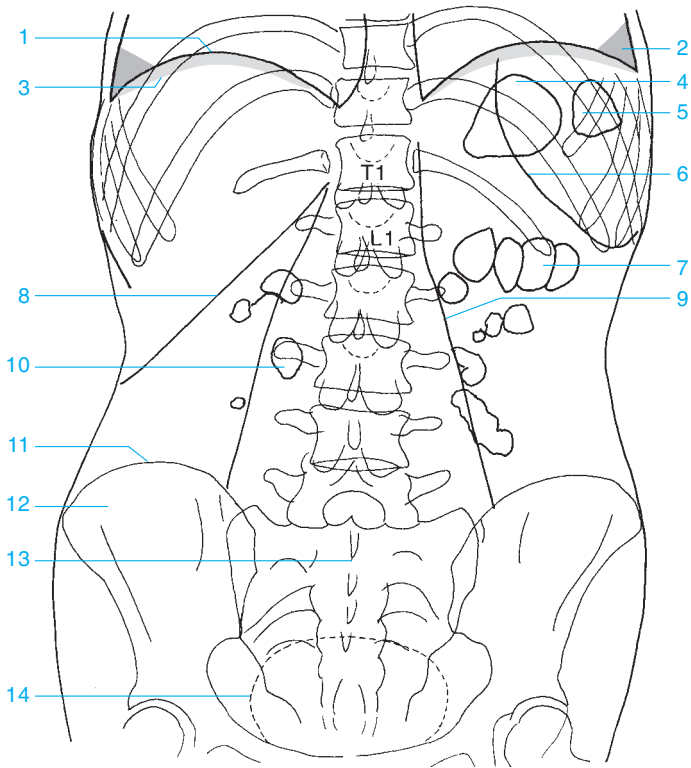
- | | |
|--|----------------------------------|
| 1 Right lung | 11 Infundibulum |
| 2 Left lung | 12 Inferior right pulmonary vein |
| 3 Aortic arch | 13 Inferior left pulmonary vein |
| 4 Trachea | 14 Left atrium |
| 5 Ascending aorta | 15 Right atrium |
| 6 Descending aorta | 16 Left ventricle |
| 7 Left upper lobe pulmonary vein, artery, and bronchus | 17 Inferior vena cava |
| 8 Main pulmonary artery | 18 Gastric bubble |
| 9 Left pulmonary artery | 19 Diaphragm |
| 10 Right inferior lobar branch of the pulmonary artery | |



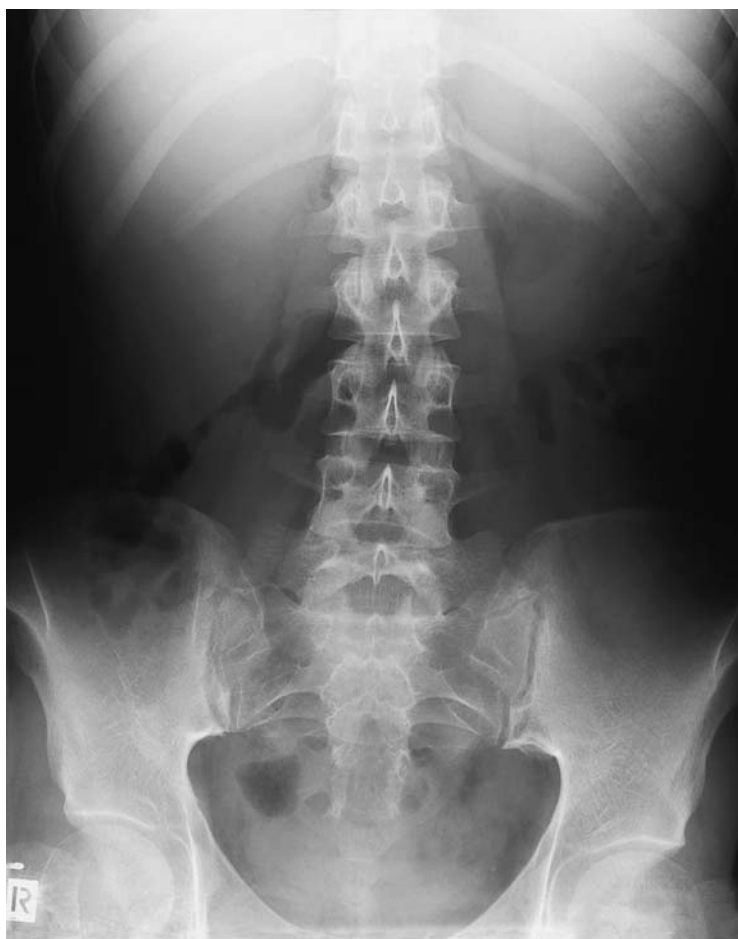

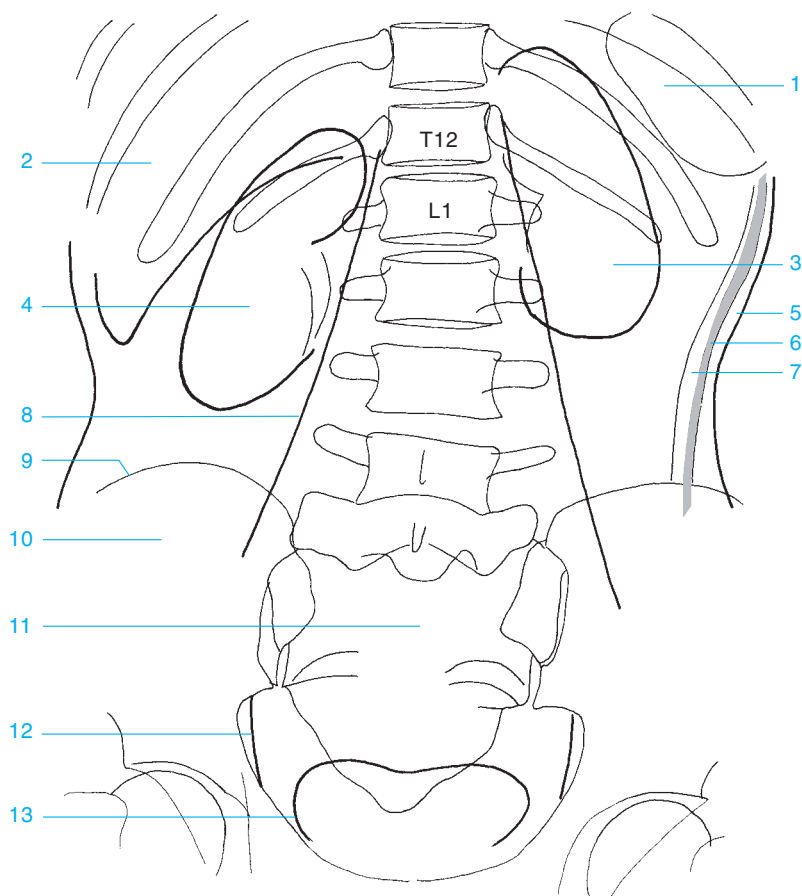
- | | |
|----------------------------------|--|
| 1 Sternum | 12 Right pulmonary vein |
| 2 Aortic arch | 13 Descending aorta |
| 3 Trachea | 14 Right ventricle |
| 4 Ascending aorta | 15 Left ventricle |
| 5 Carina of the trachea | 16 Right lung |
| 6 Left pulmonary artery | 17 Inferior vena cava |
| 7 Right main bronchus | 18 Gastric bubble (left hemidia-
phragm) |
| 8 Left main bronchus | 19 Right hemidiaphragm |
| 9 Right atrium | 20 Left lung |
| 10 Right pulmonary artery | |
| 11 Left pulmonary vein | |





- | | |
|---|--------------------------------|
| 1 Diaphragm | 7 Gas in the transverse colon |
| 2 Costodiaphragmatic recess
(costophrenic angle) | 8 Inferior margin of the liver |
| 3 Subphrenic space | 9 Margin of the psoas |
| 4 Gastric bubble | 10 Gas in the small bowel |
| 5 Gas in the splenic flexure of the
colon | 11 Iliac crest |
| 6 Lower margin of the spleen | 12 Ilium |
| | 13 Sacrum |
| | 14 Urinary bladder |





1 Spleen

2 Liver

3 Left kidney

4 Right kidney

5 Subcutaneous fat

6 Abdominal muscles

7 Preperitoneal fat

8 Psoas

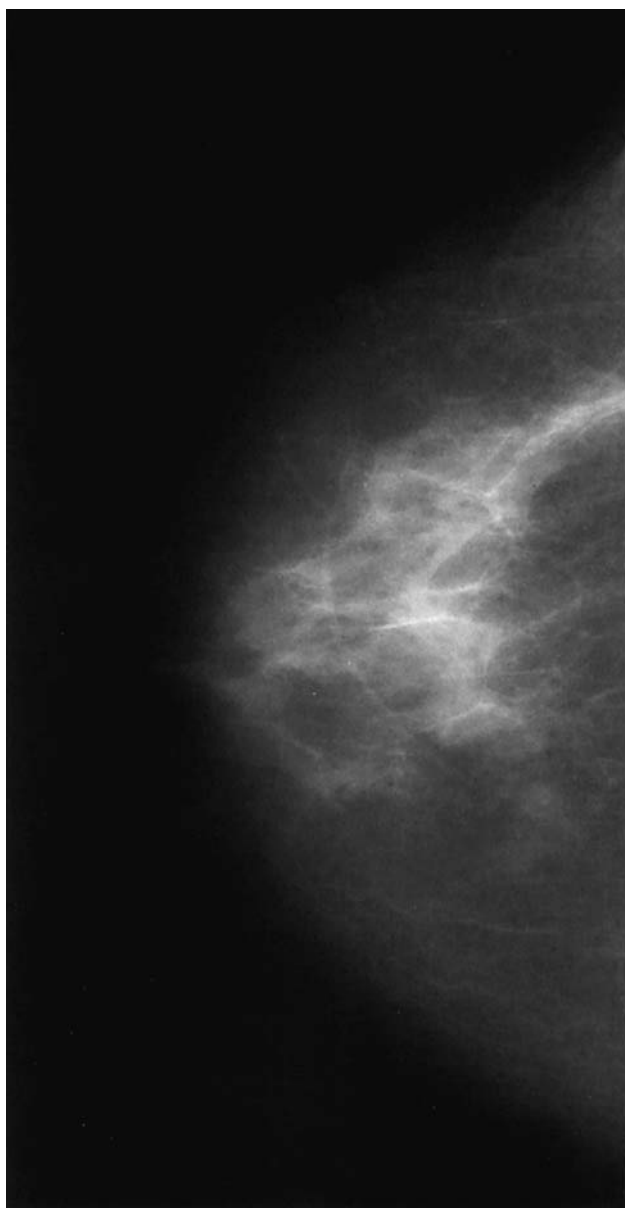
9 Iliac crest

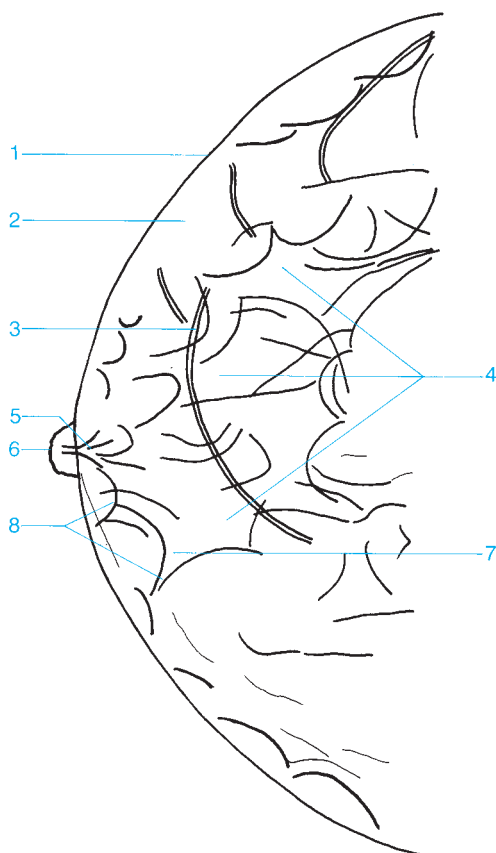
10 Ilium

11 Sacrum

12 Obturator internus

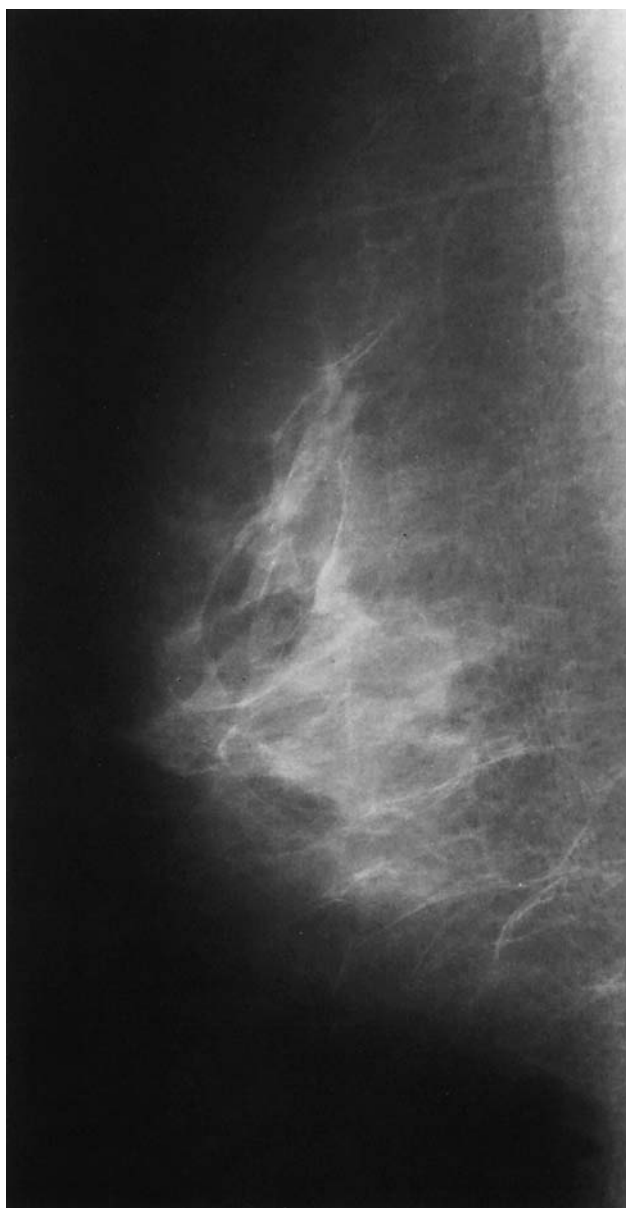
13 Urinary bladder

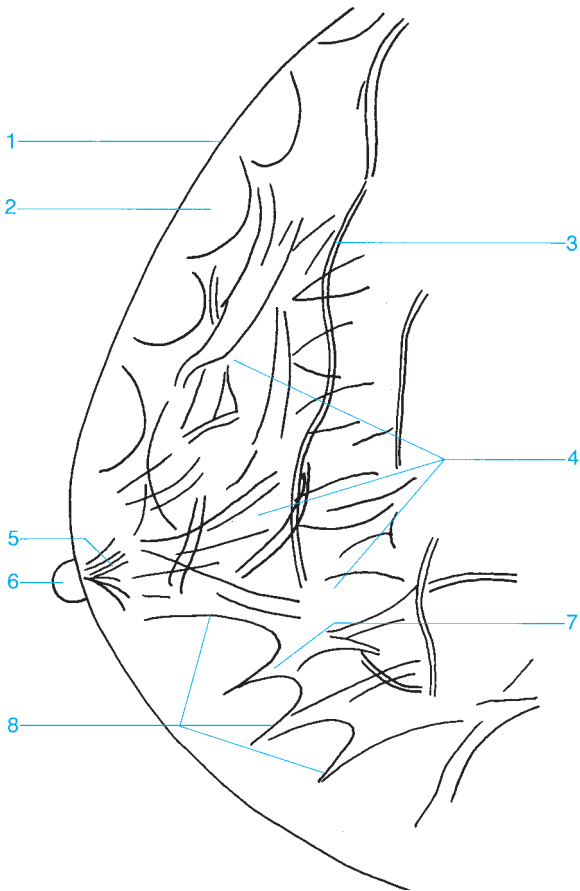




- 1 Skin
- 2 Subcutaneous fat
- 3 Veins
- 4 Glandular tissue
- 5 Lactiferous duct posterior to the nipple

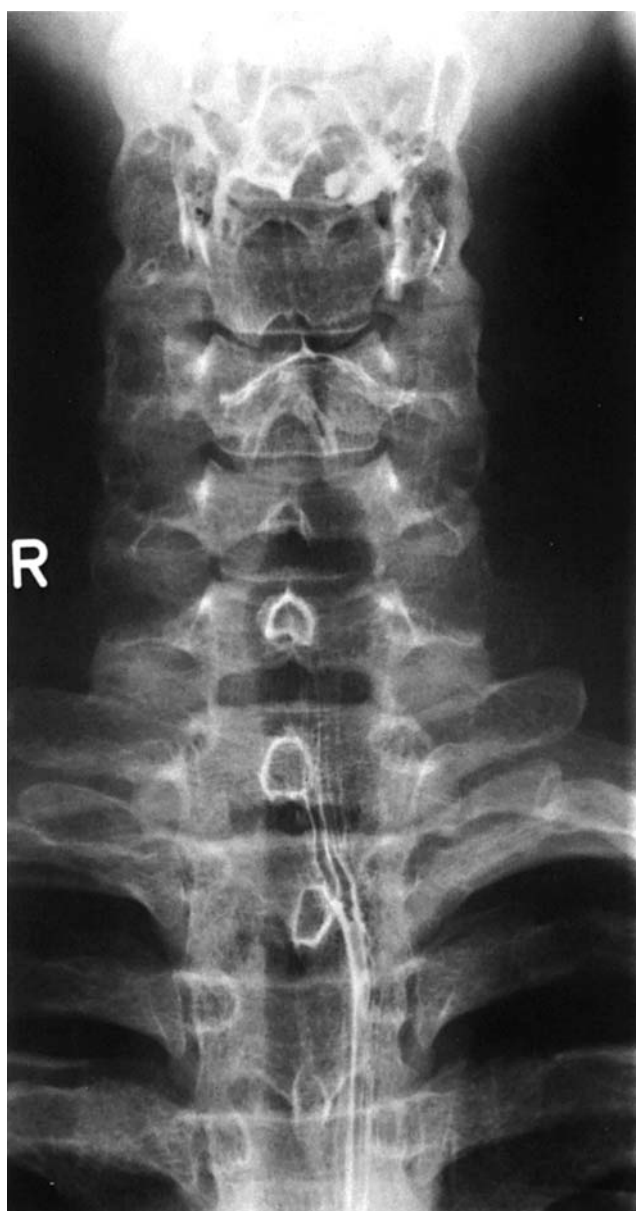- 6 Nipple
- 7 Contour of a lobule
- 8 Cooper's ligaments

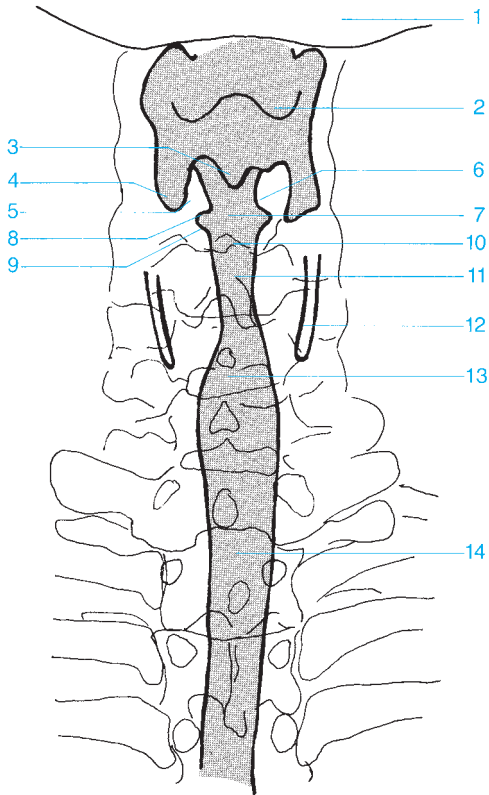




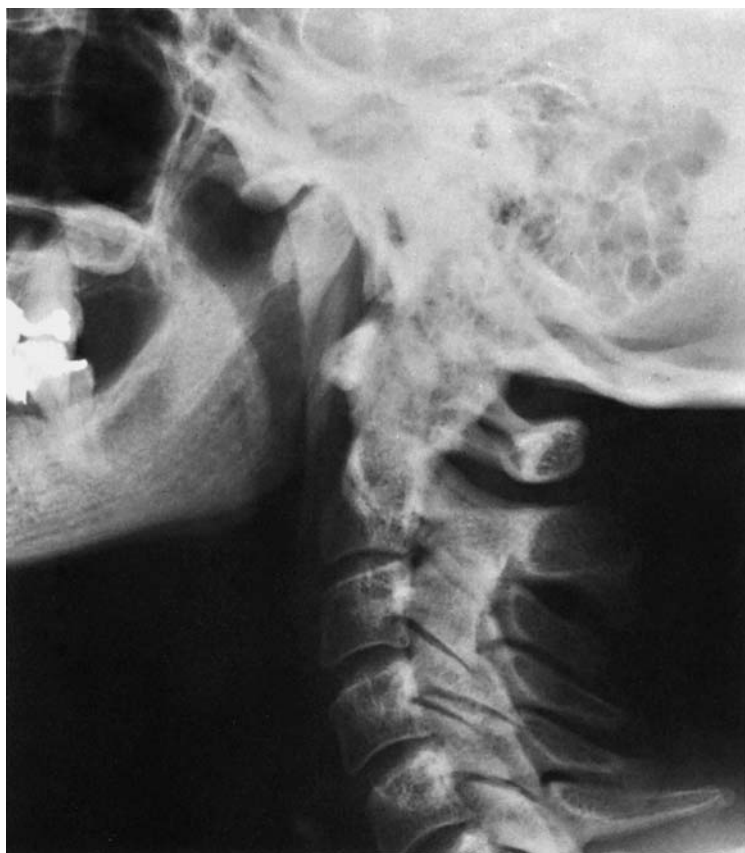- 1 Skin
- 2 Subcutaneous fat
- 3 Veins
- 4 Glandular tissue

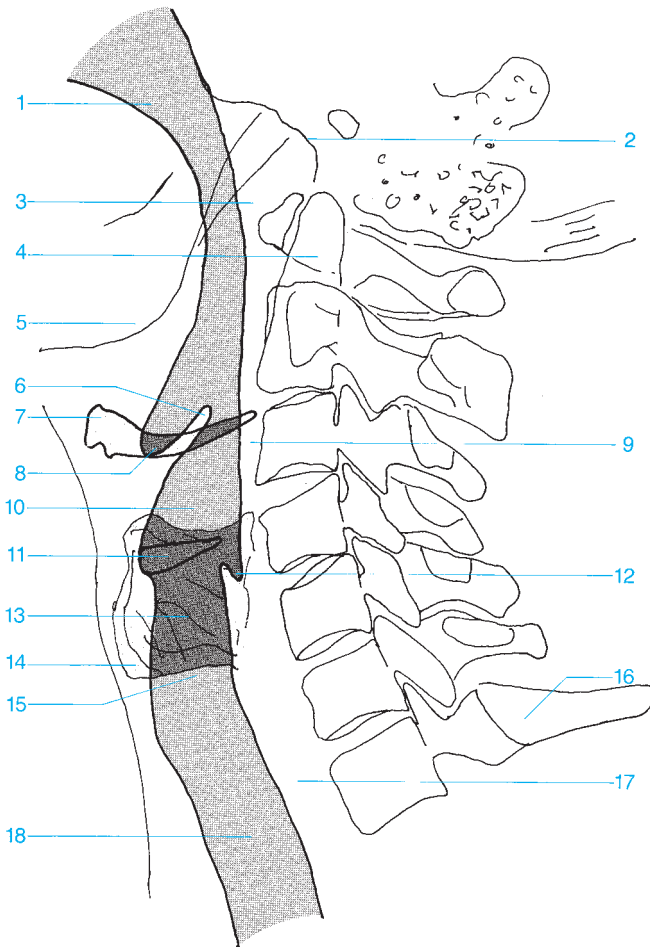
- 5 Lactiferous duct posterior to the nipple
- 6 Nipple
- 7 Contour of a lobule
- 8 Cooper's ligaments





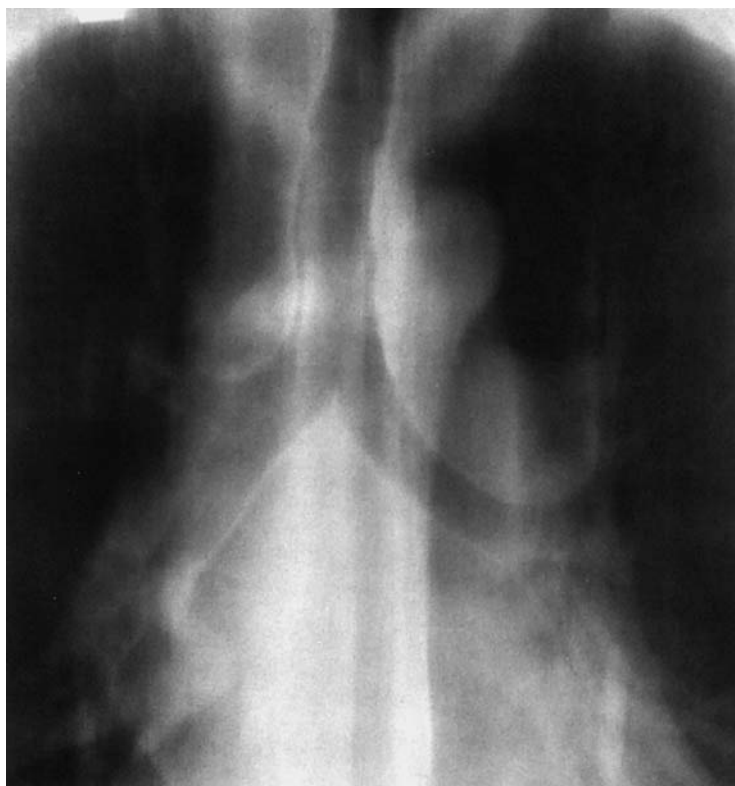
- | | |
|--------------------------------------|--------------------------------|
| 1 Mandible | 8 Ventricle of the larynx |
| 2 Floor of the vallecula | 9 Vocal fold (true vocal cord) |
| 3 Interarytenoid notch | 10 Rima glottidis |
| 4 Piriform recess | 11 Subglottic space |
| 5 Arytenoid cartilages | 12 Thyroid cartilage |
| 6 Vestibular fold (false vocal cord) | 13 Proximal trachea |
| 7 Vestibule of the larynx | 14 Distal trachea |

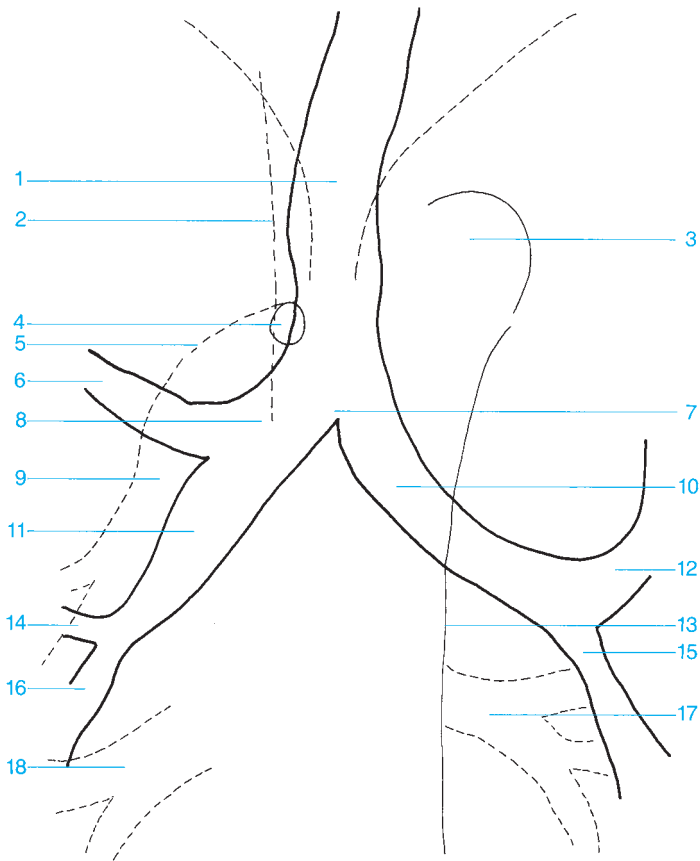




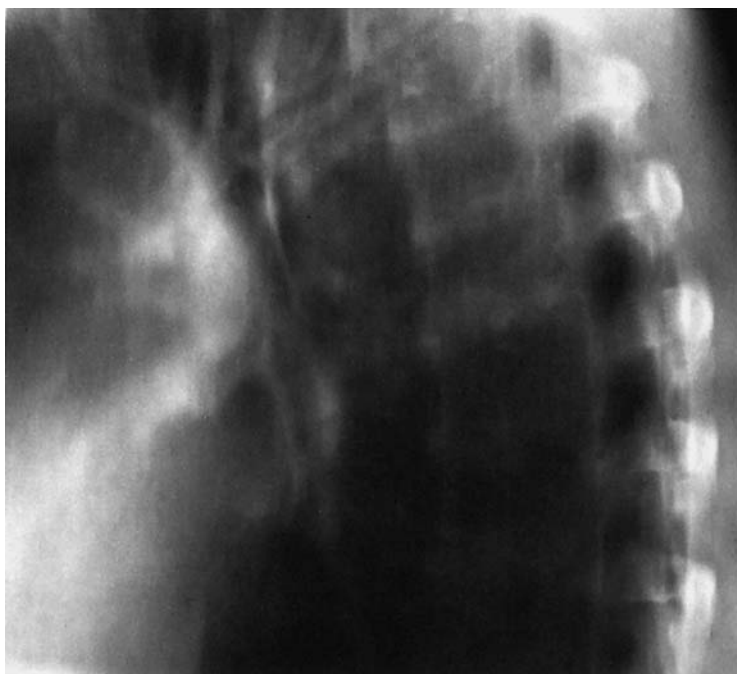- 1 Oral cavity
- 2 Base of the skull
- 3 Posterior nasopharynx
- 4 Dens of the axis
- 5 Mandible
- 6 Epiglottis
- 7 Hyoid bone
- 8 Floor of the vallecula
- 9 Retropharyngeal space
- 10 Vestibule of the larynx

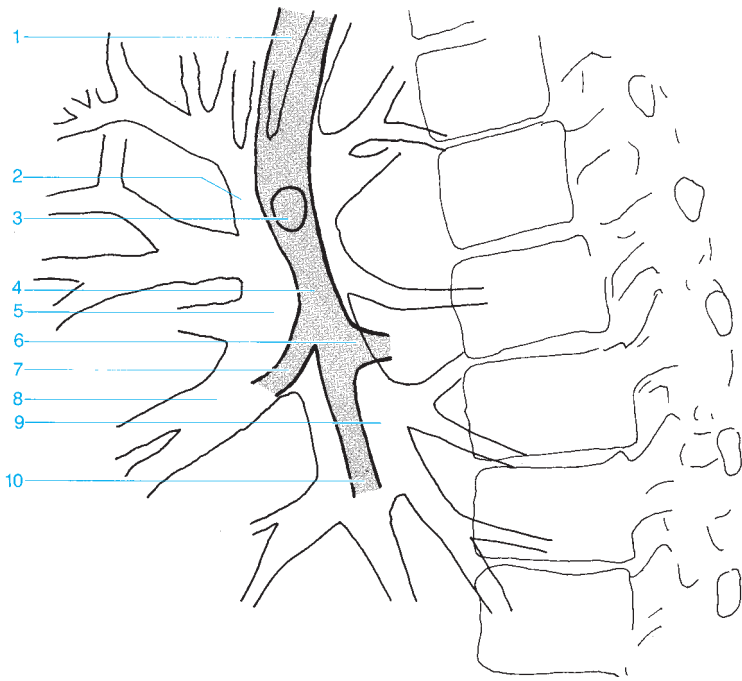
- 11 Ventricle of the larynx
- 12 Inferior posterior margin of the piriform recess
- 13 Subglottic space
- 14 Thyroid cartilage
- 15 Proximal trachea
- 16 Vertebra C7
- 17 Esophagus
- 18 Distal trachea



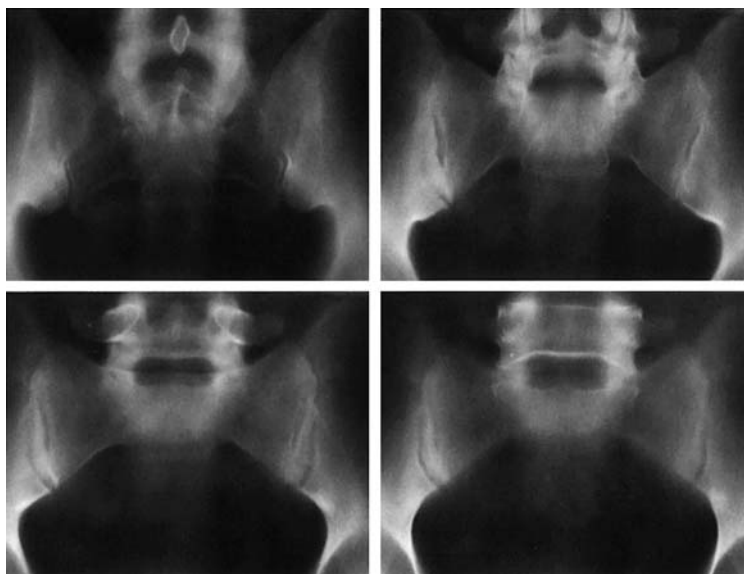


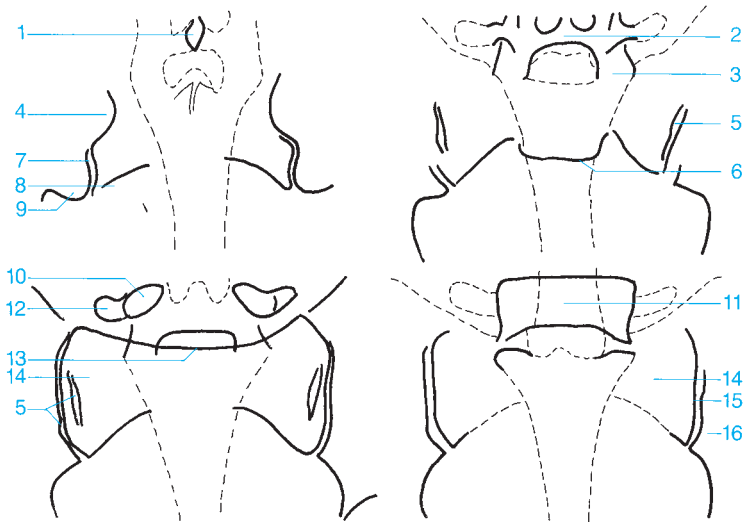
- | | |
|--|-------------------------------------|
| 1 Trachea | 10 Left main bronchus |
| 2 Superior vena cava | 11 Intermediate bronchus |
| 3 Aortic arch | 12 Left upper lobe bronchus |
| 4 Azygos vein | 13 Descending aorta |
| 5 Right pulmonary artery | 14 Middle lobe bronchus |
| 6 Right upper lobe bronchus | 15 Left lower lobe bronchus |
| 7 Bifurcation of the trachea | 16 Right lower lobe bronchus |
| 8 Right main bronchus | 17 Pulmonary veins |
| 9 Inferior lobar branch of the pulmonary artery | 18 Venous confluence |





- 1 Trachea
- 2 Superior lobar branch of the pulmonary artery
- 3 Origin of the upper lobe bronchus
- 4 Intermediate bronchus
- 5 Right pulmonary artery
- 6 Segmental bronchus of the lower lobe
- 7 Middle lobe bronchus
- 8 Middle lobar branch of the pulmonary artery
- 9 Inferior lobar branch of the pulmonary artery
- 10 Lower lobe bronchus



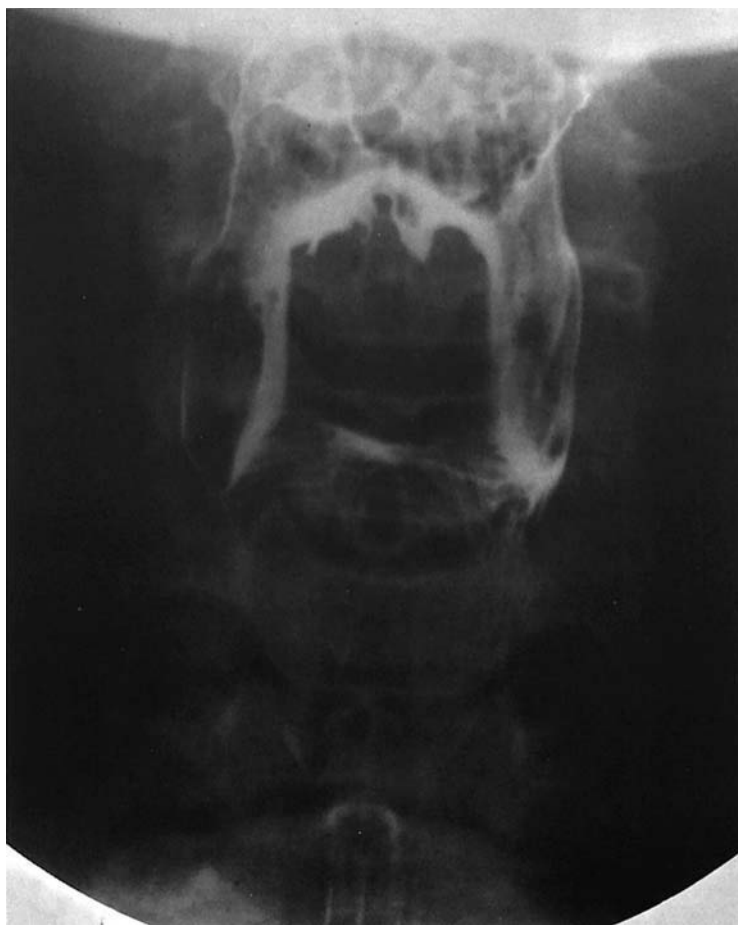

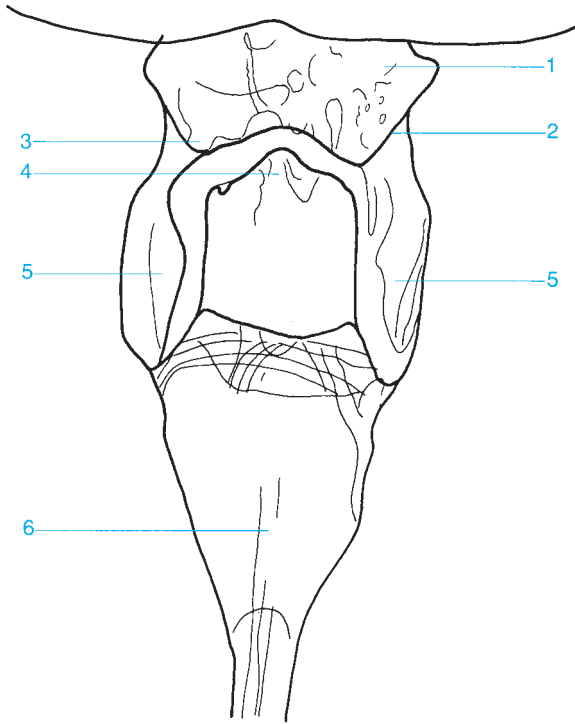
- | | |
|--|---|
| 1 Spinous process | 9 Posterior inferior iliac spine |
| 2 Lamina | 10 Pedicle |
| 3 Inferior articular process | 11 L5 |
| 4 Posterior superior iliac spine | 12 Transverse process |
| 5 Middle portion of the sacroiliac joint | 13 Promontory |
| 6 Anterior aspect of the sacrum | 14 Sacral ala |
| 7 Posterior inferior aspect of the sacroiliac joint | 15 Anterior aspect of the sacroiliac joint |
| 8 Sacral foramina | 16 Ilium (ilic wing) |

This page intentionally left blank.

Contrast Studies

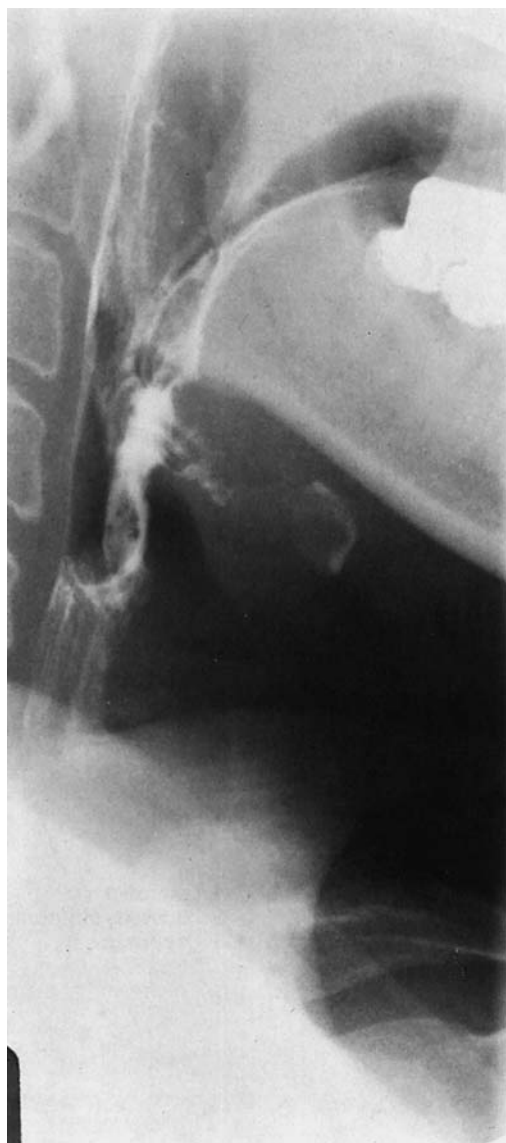- Gastrointestinal System..... 240
- Intravenous Contrast Studies 264
- Arthrography 268
- Arteriography..... 280
- Venography..... 326

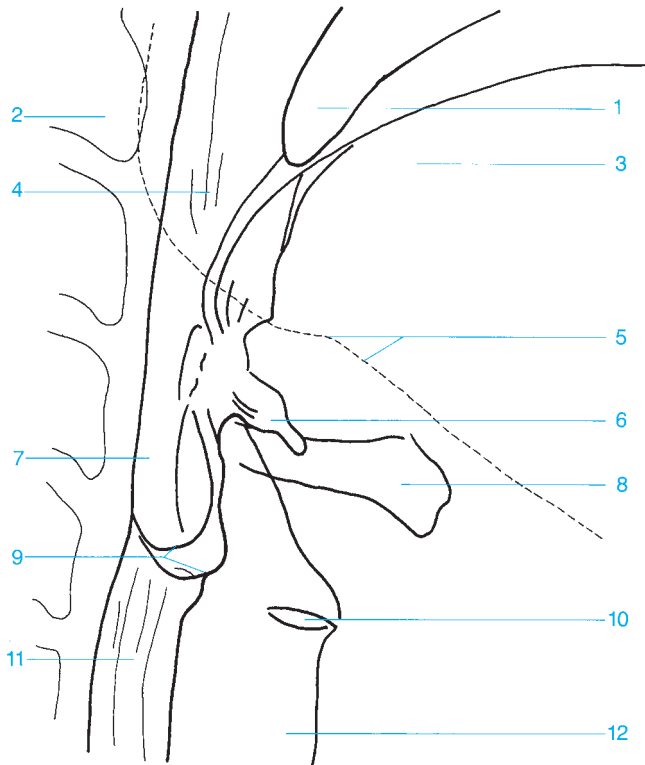




- 1 Pharynx
- 2 Lateral glossoepiglottic fold
- 3 Vallecula

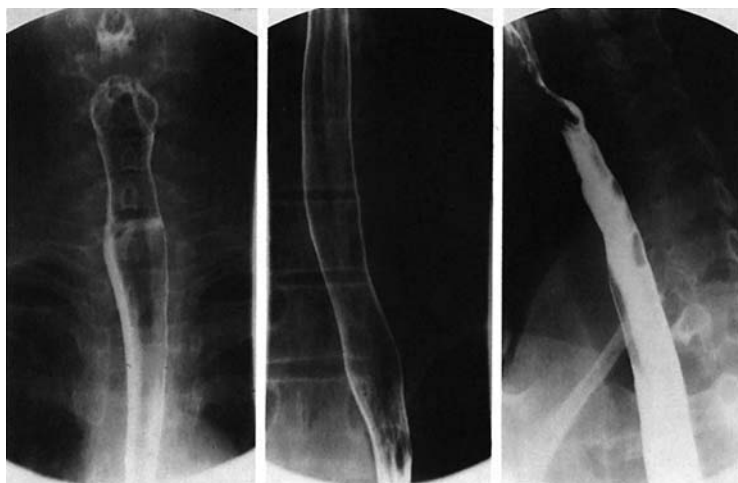- 4 Epiglottis
- 5 Piriform recess
- 6 Esophagus

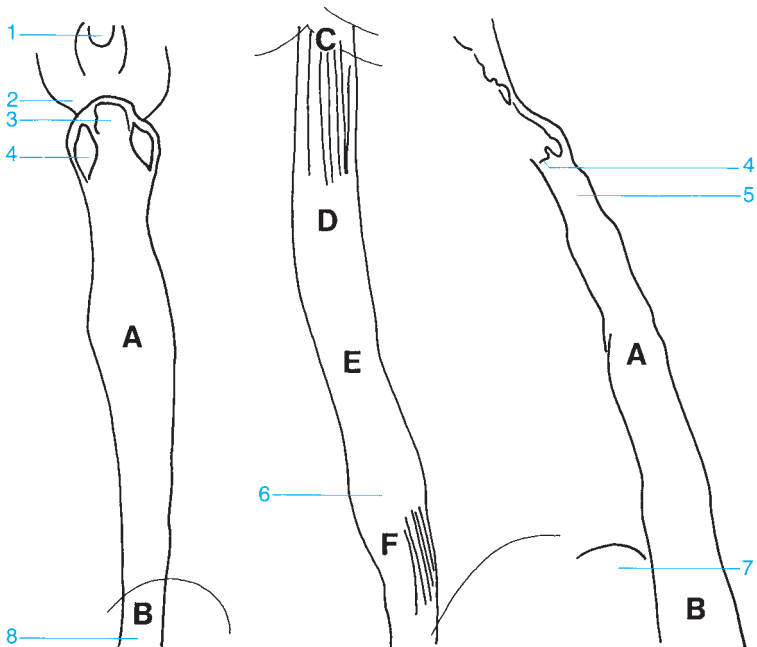




- 1 Uvula
- 2 Cervical spine (axis)
- 3 Tongue
- 4 Oropharynx
- 5 Mandible
- 6 Vallecula

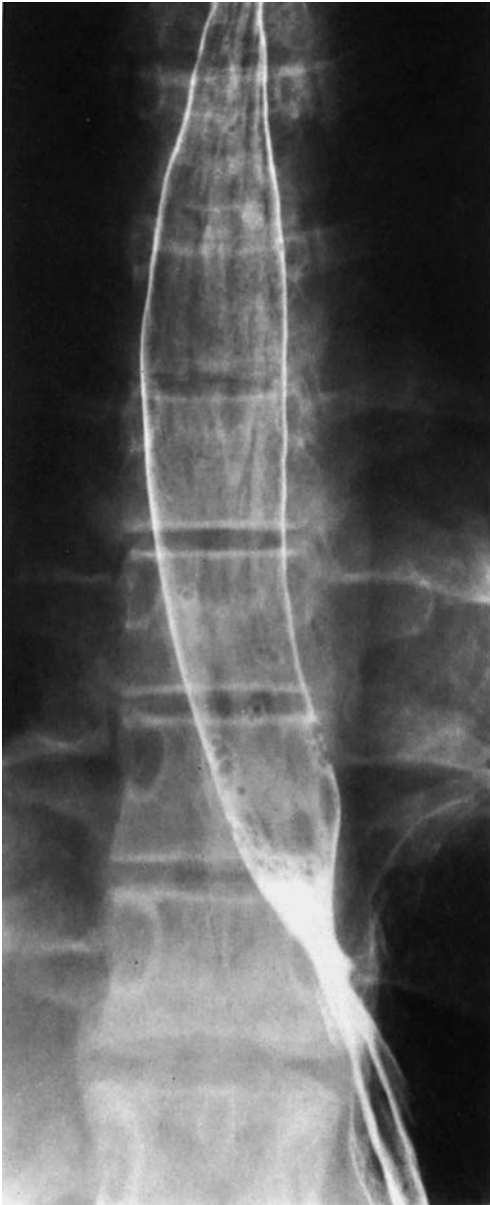- 7 Larynx
- 8 Hyoid bone
- 9 Piriform recess
- 10 Ventricle of the larynx
- 11 Esophagus
- 12 Trachea

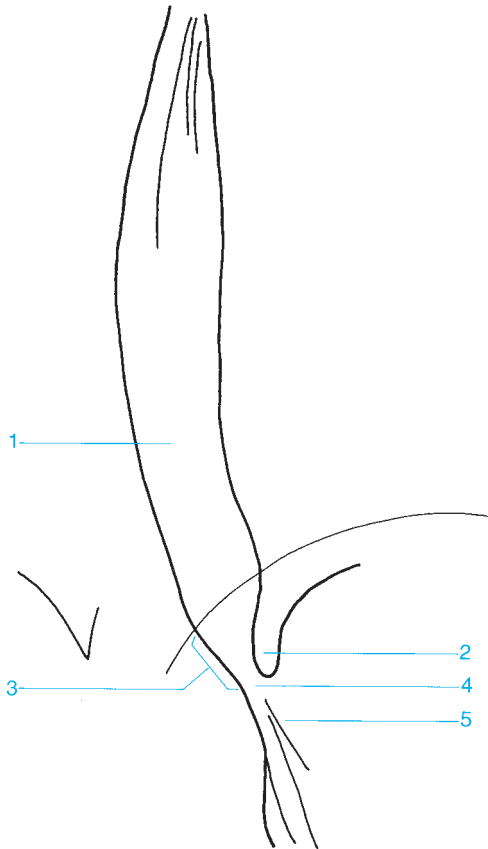




- 1 Uvula
- 2 Lateral glossoepiglottic fold
- 3 Epiglottis
- 4 Piriform recess
- 5 Upper esophageal sphincter
- 6 Body of the esophagus
- 7 Aortic arch
- 8 Bronchial and aortic segment

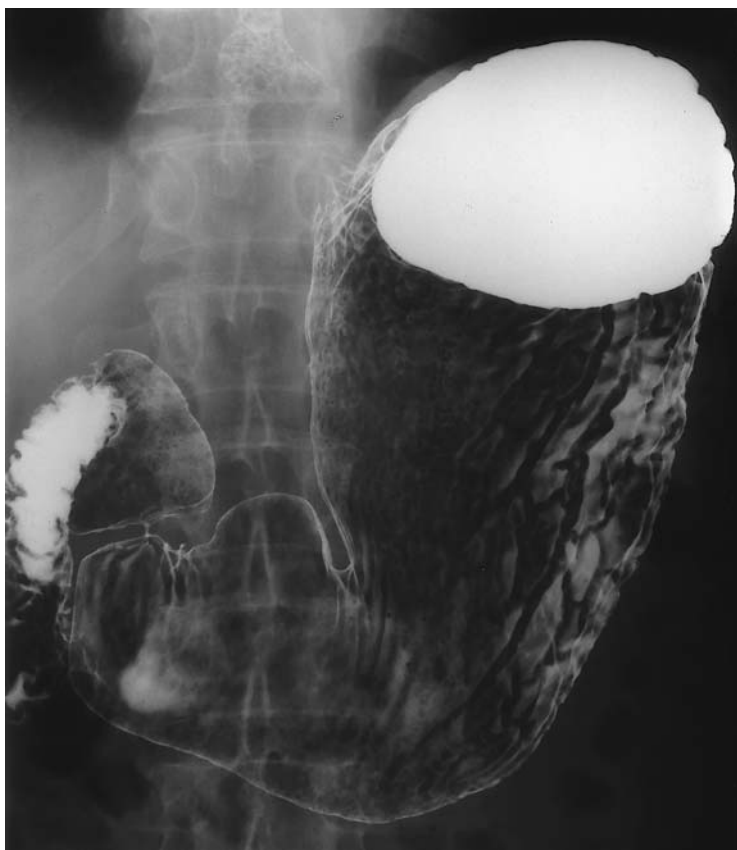- A Paratracheal segment
- B Aortic segment
- C Bronchial segment
- D Interbronchial segment
- E Retrocardiac segment
- F Epiphrenic segment

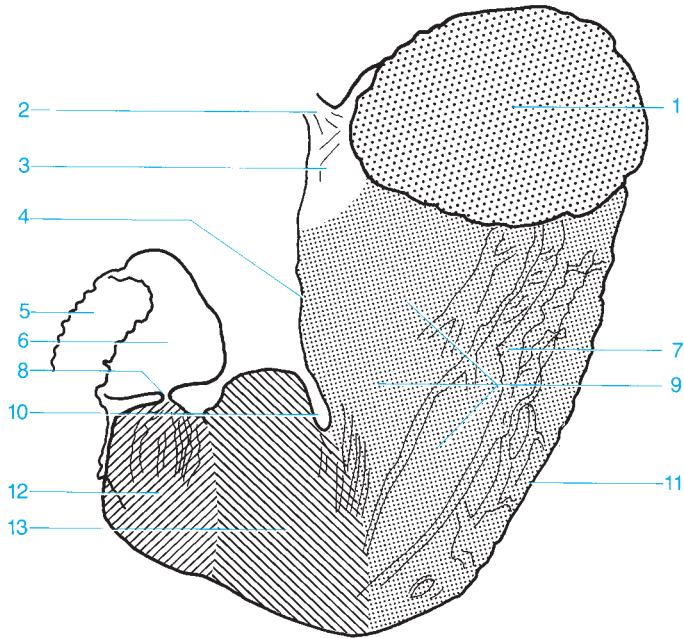




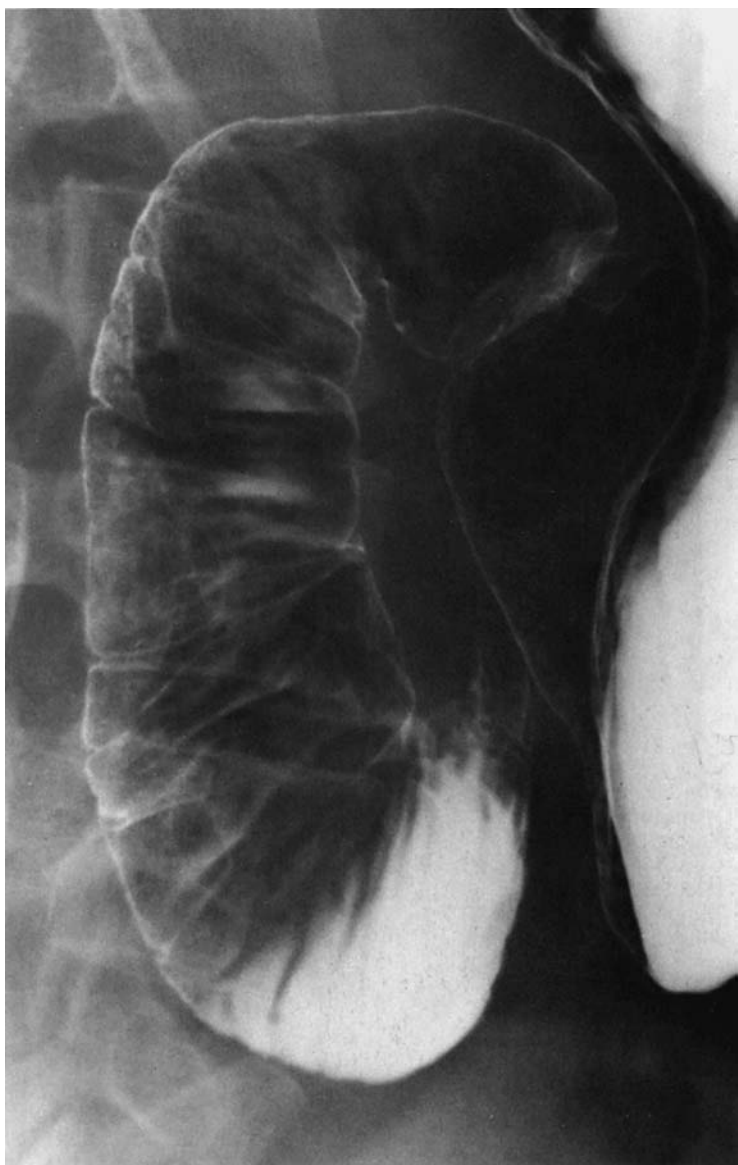
- 1 Distal esophagus
- 2 Gastroesophageal angle
- 3 Abdominal esophagus

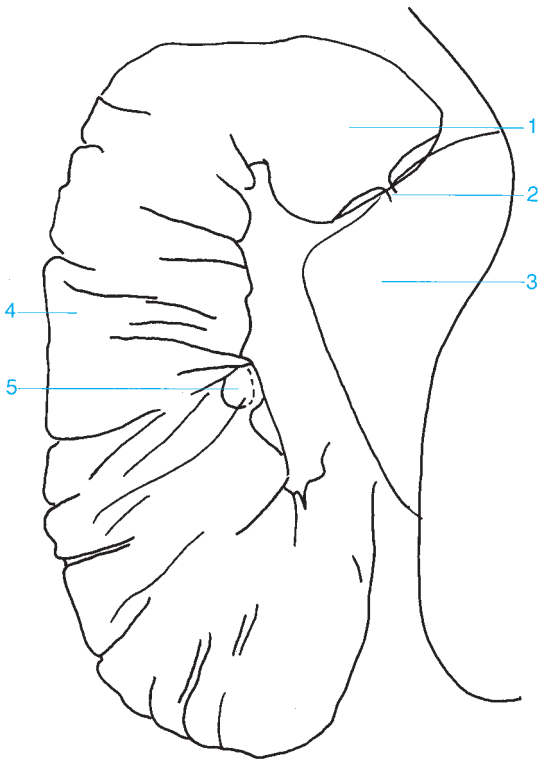
- 4 Esophageal hiatus
- 5 Cardia





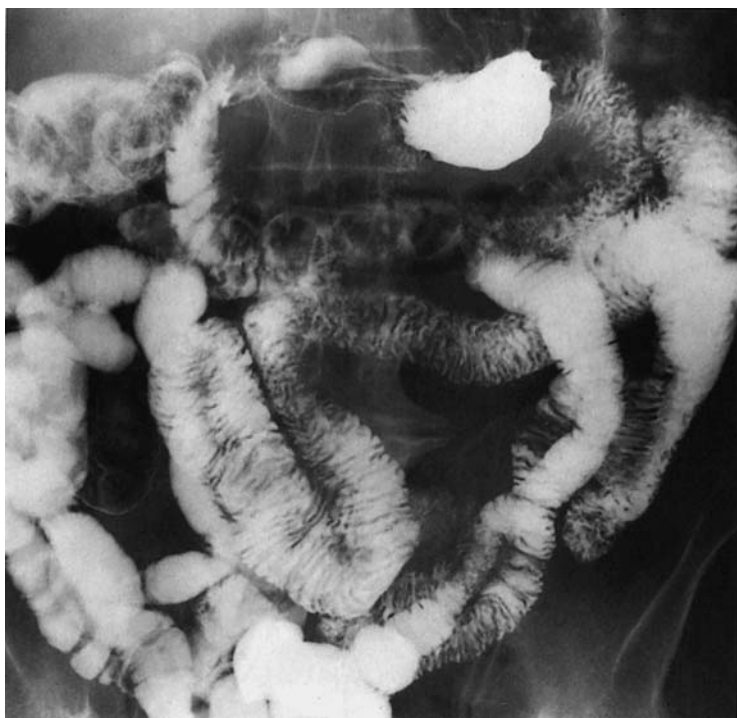- | | |
|----------------------------------|-----------------------|
| 1 Fundus | 8 Pylorus |
| 2 Abdominal esophagus | 9 Body of the stomach |
| 3 Cardia | 10 Angular notch |
| 4 Lesser curvature | 11 Greater curvature |
| 5 Duodenum | 12 Pyloric antrum |
| 6 Ampulla of Vater | 12 + 13 Antrum |
| 7 Gastric folds (posterior wall) | |

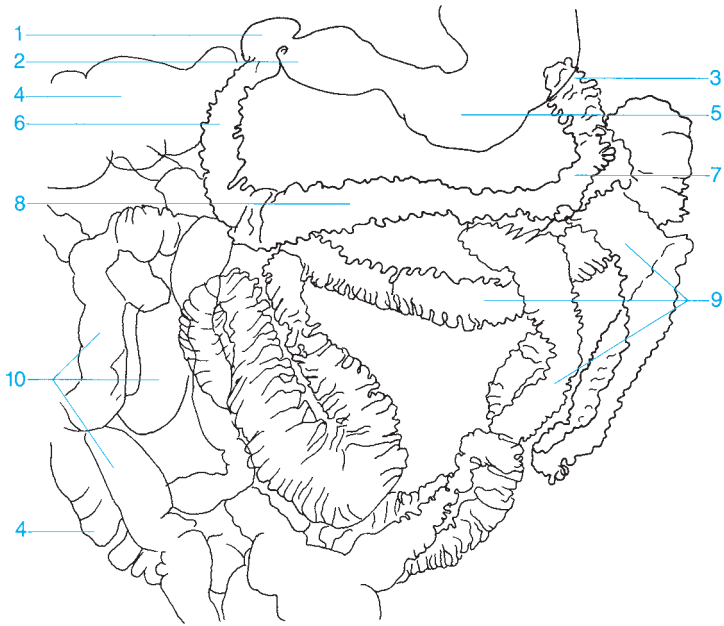




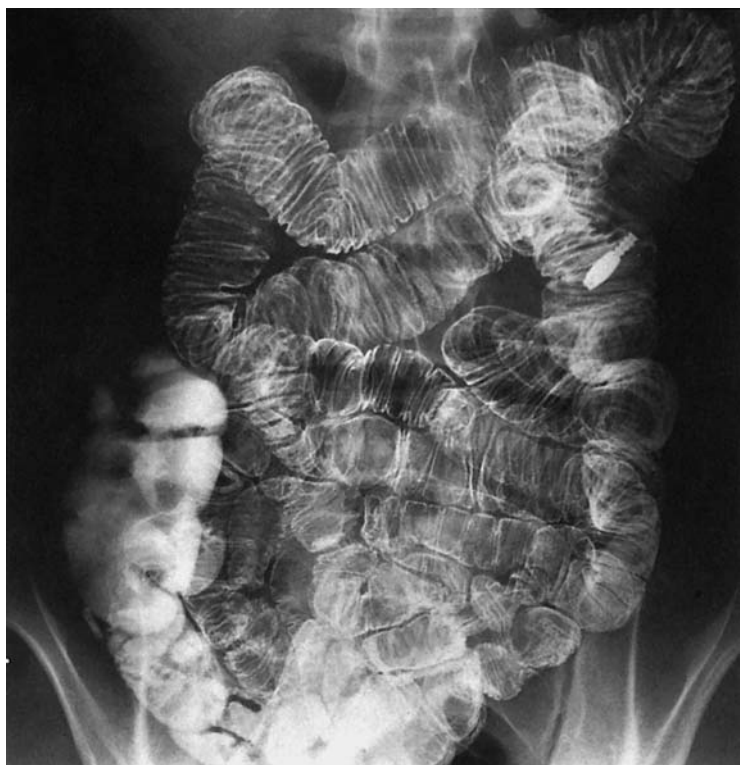- 1 Ampulla of Vater
- 2 Pylorus
- 3 Pyloric antrum

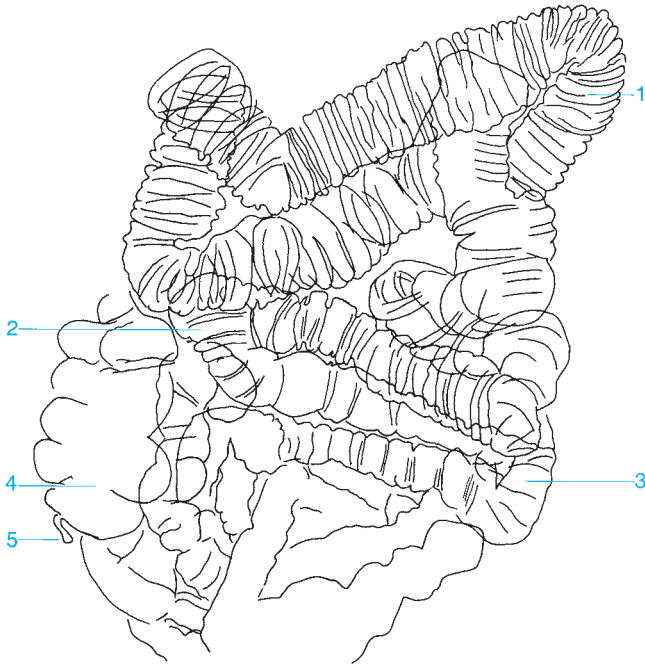
- 4 Descending duodenum
- 5 Papilla of Vater





- | | |
|--------------------------|-------------------------------|
| 1 Ampulla of Vater | 6 Descending duodenum |
| 2 Pyloric antrum | 7 Ascending duodenum |
| 3 Duodenojejunal flexure | 8 Horizontal part of duodenum |
| 4 Colon | 9 Jejunum |
| 5 Body of the stomach | 10 Ileum |





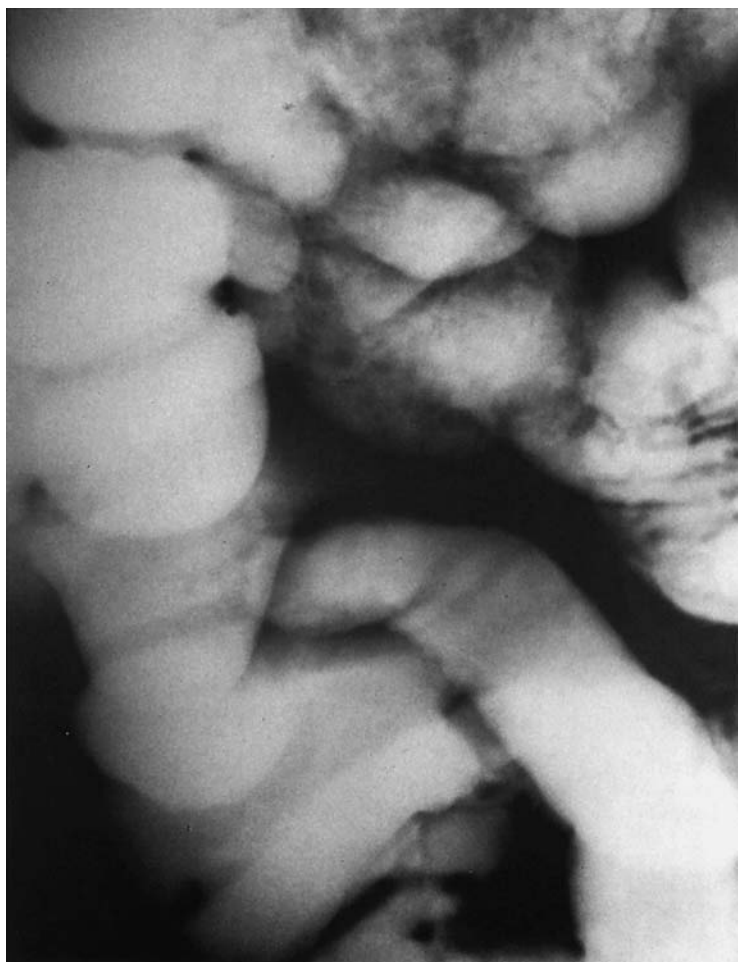1 Jejunum

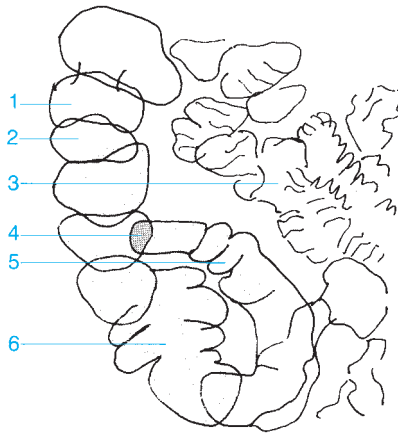
2 Junction of the ileum and jejunum

3 Ileum

4 Cecum

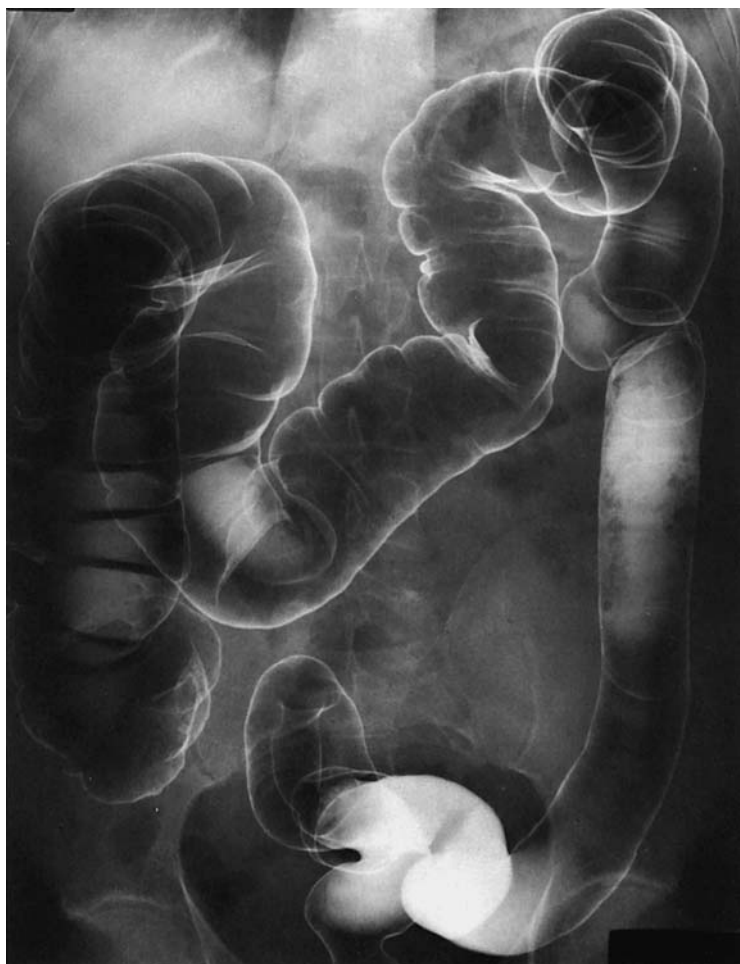5 Appendix

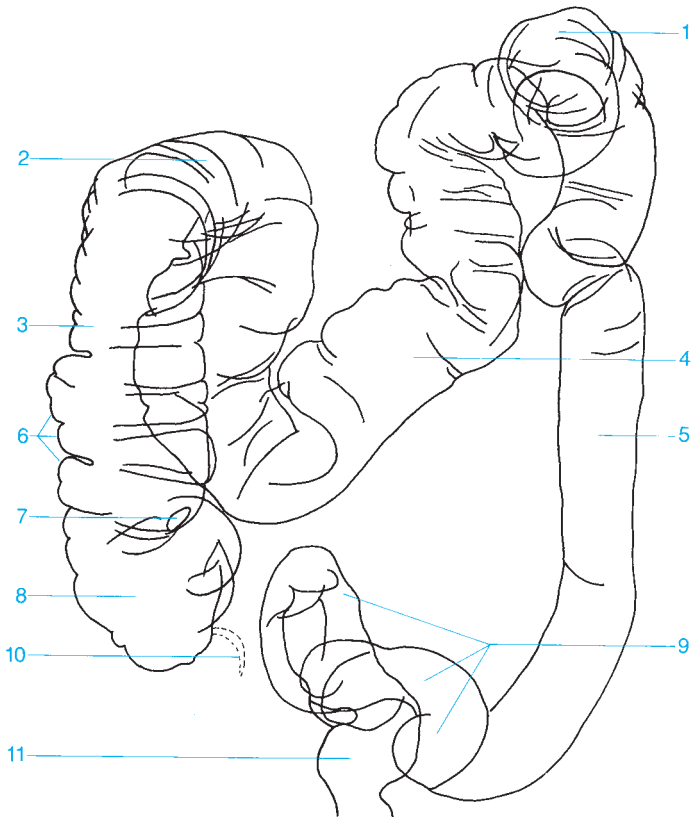




- 1 Haustra of the colon
- 2 Ascending colon
- 3 Ileum

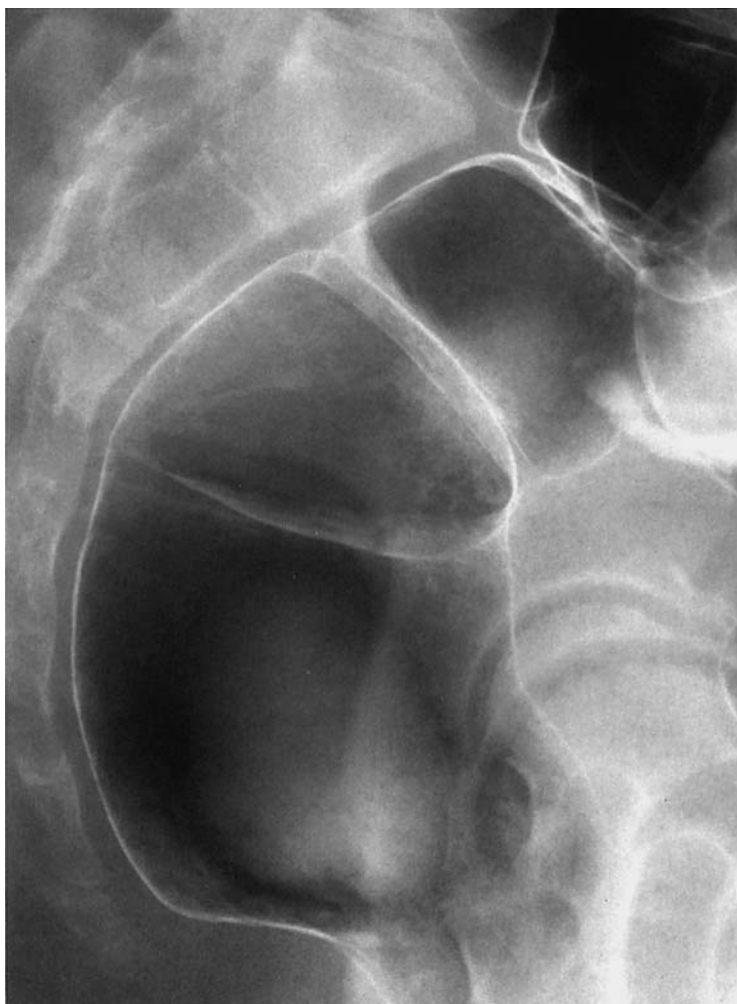- 4 ileocecal valve
- 5 Terminal ileum
- 6 Cecum

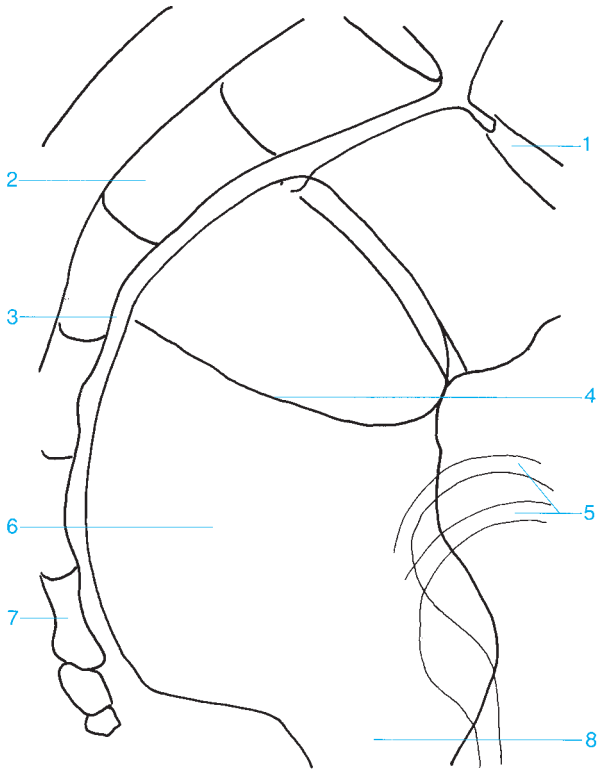




- 1 Splenic flexure of the colon
- 2 Hepatic flexure of the colon
- 3 Ascending colon
- 4 Transverse colon
- 5 Descending colon
- 6 Haustra

- 7 Ileocecal valve
- 8 Cecum
- 9 Sigmoid colon
- 10 Appendix
- 11 Rectum





1 Rectosigmoid junction

2 Sacrum

3 Retrorectal space

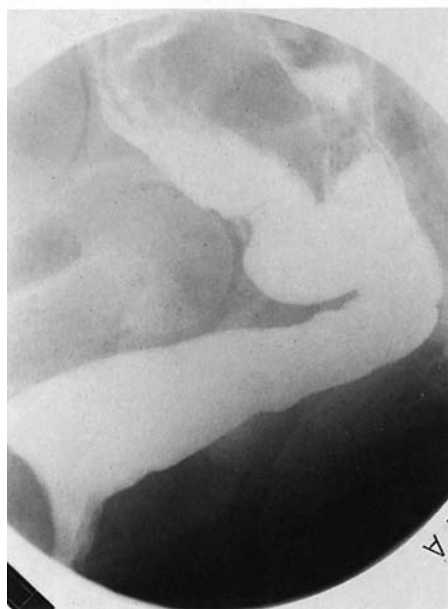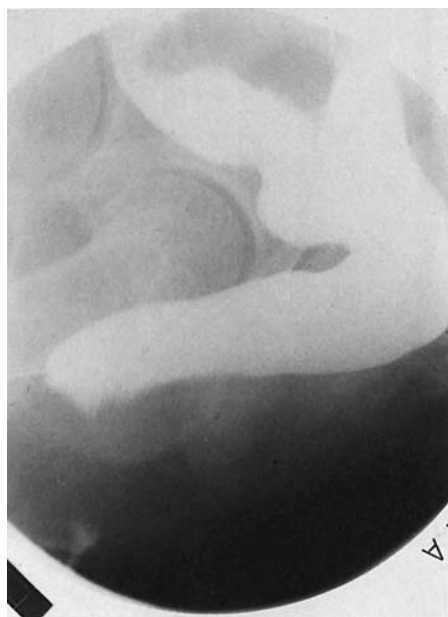4 Transverse rectal fold

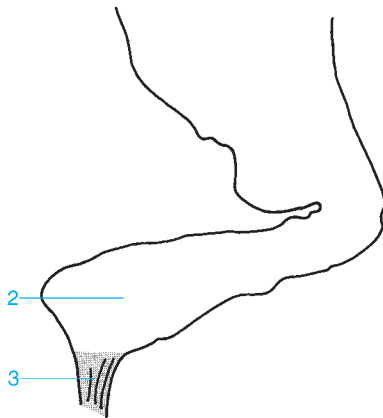
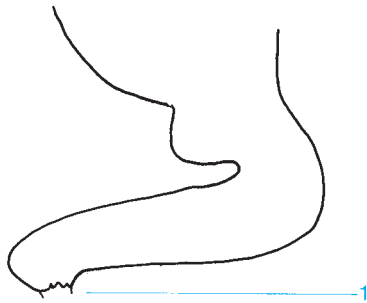5 Femoral head

6 Rectal ampulla

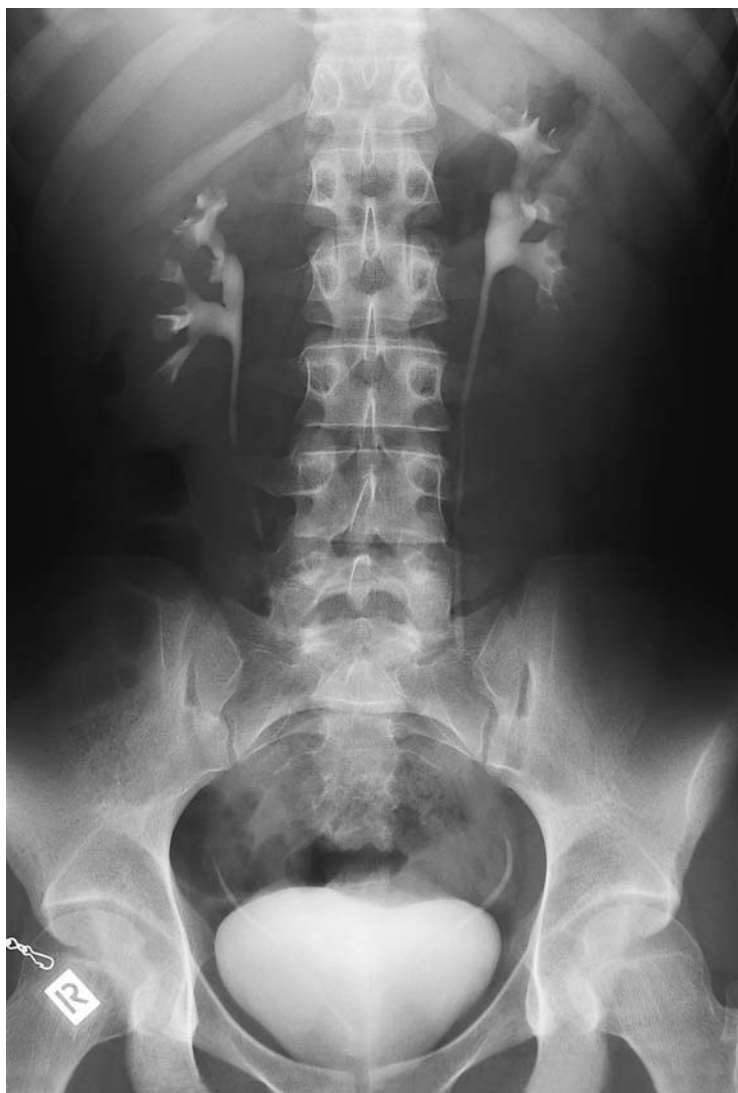7 Coccyx

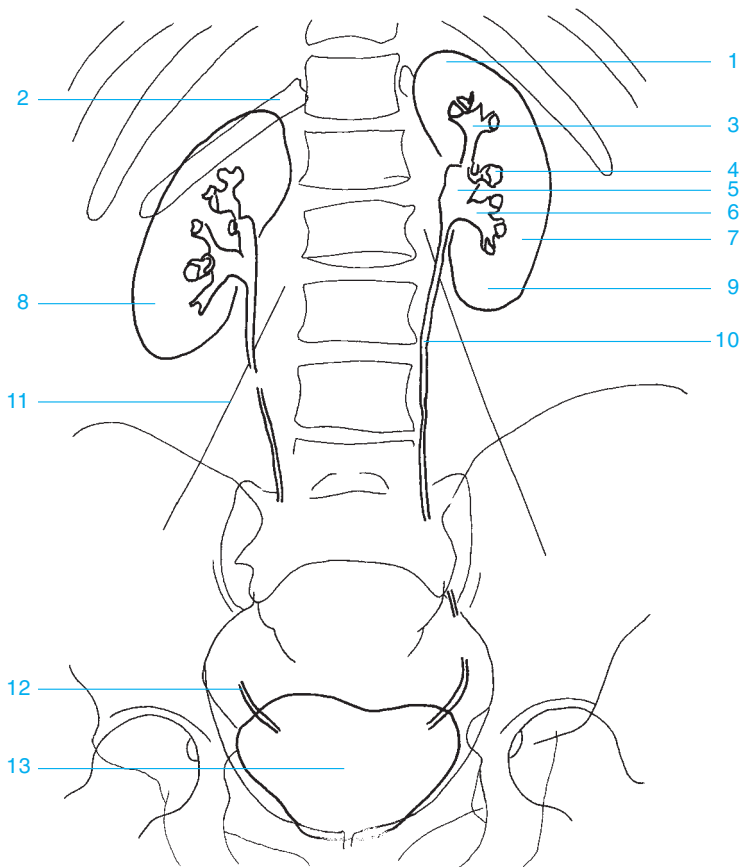
8 Anorectal junction





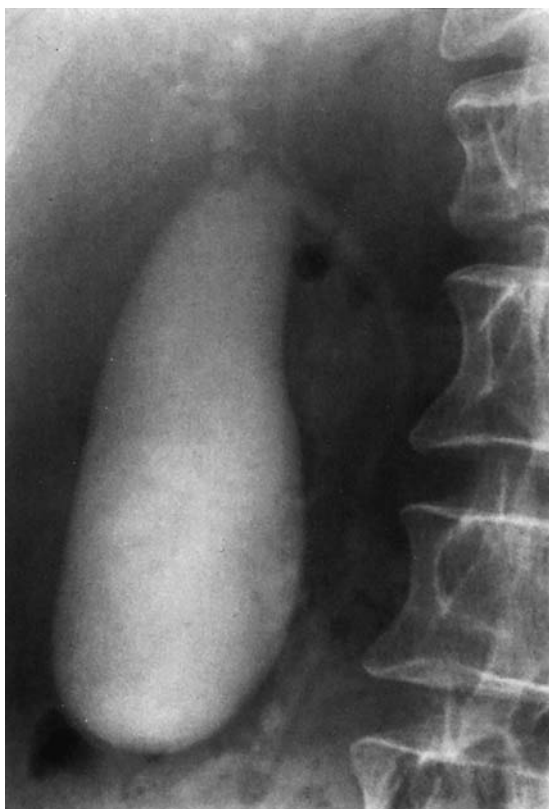- 1 Puborectalis
- 2 Rectal ampulla
- 3 Anal canal

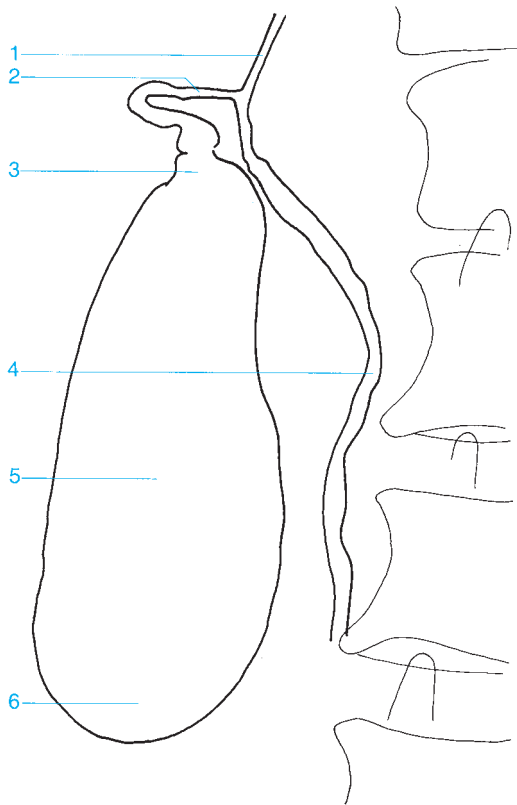




- 1 Superior pole of the kidney
- 2 Twelfth rib
- 3 Superior calyces
- 4 Middle calyces
- 5 Renal pelvis
- 6 Inferior calyces
- 7 Left kidney

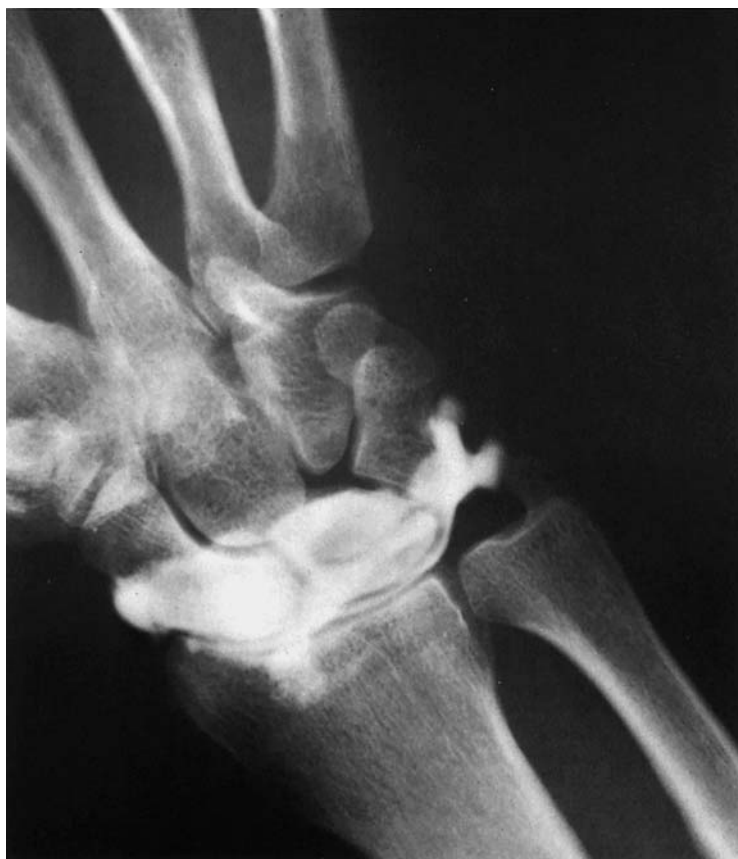- 8 Right kidney
- 9 Inferior pole of the kidney
- 10 Ureter
- 11 Margin of the psoas
- 12 Distal ureter
- 13 Urinary bladder

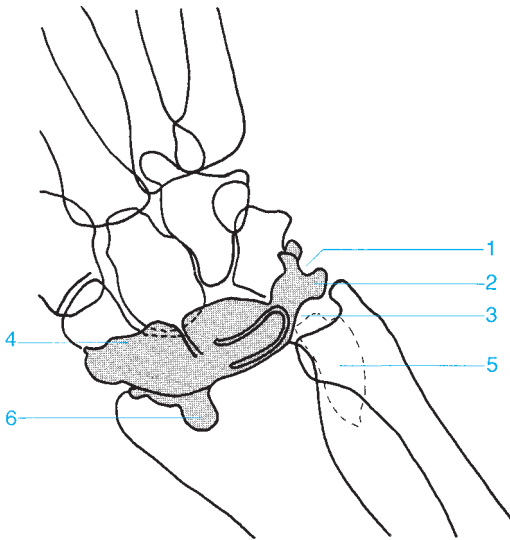




- 1 Common hepatic duct
- 2 Cystic duct
- 3 Neck of the gallbladder

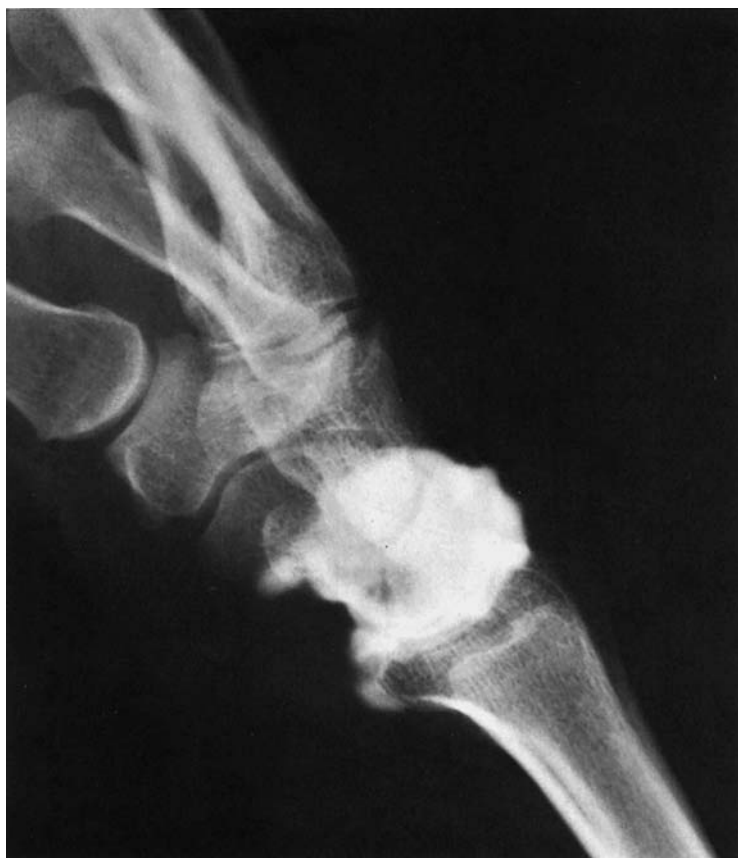- 4 Common bile duct
- 5 Body of the gallbladder
- 6 Fundus of the gallbladder

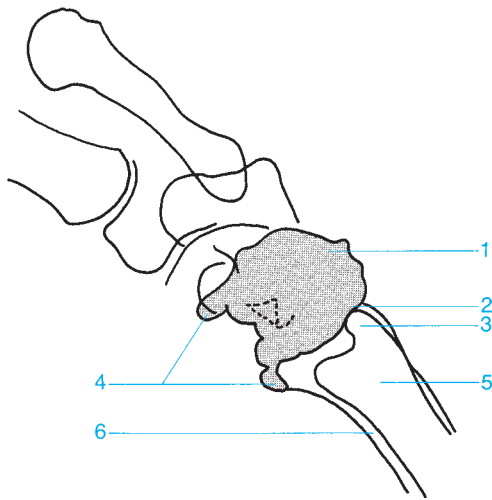




- 1 Meniscus
- 2 Ulnar recess
- 3 Triangular fibrocartilage

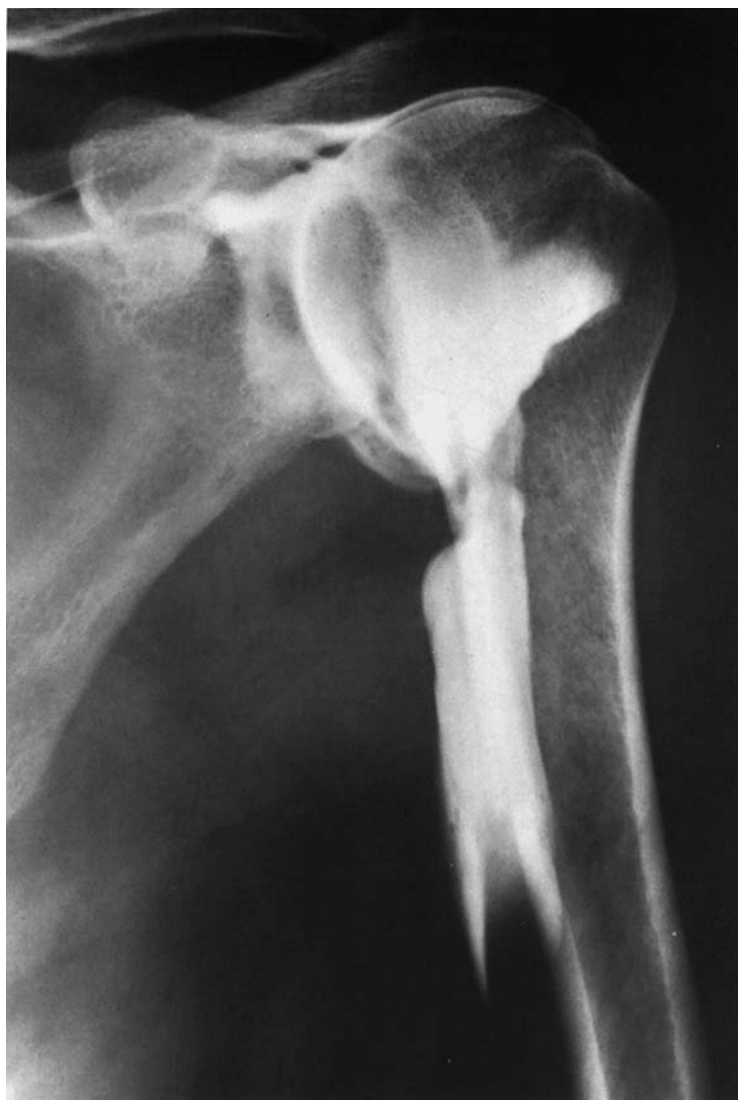- 4 Extensor recess
- 5 Sacciform recess
- 6 Flexor recess

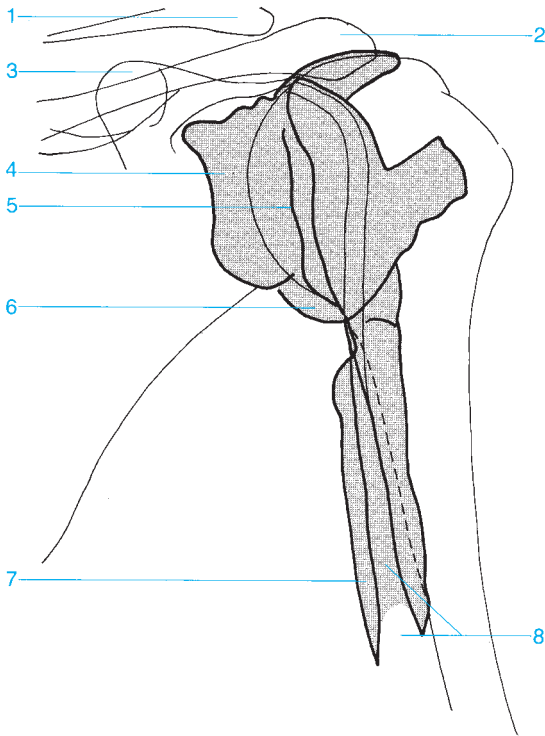




- 1 Extensor recess
- 2 Ulnar recess
- 3 Ulnar styloid

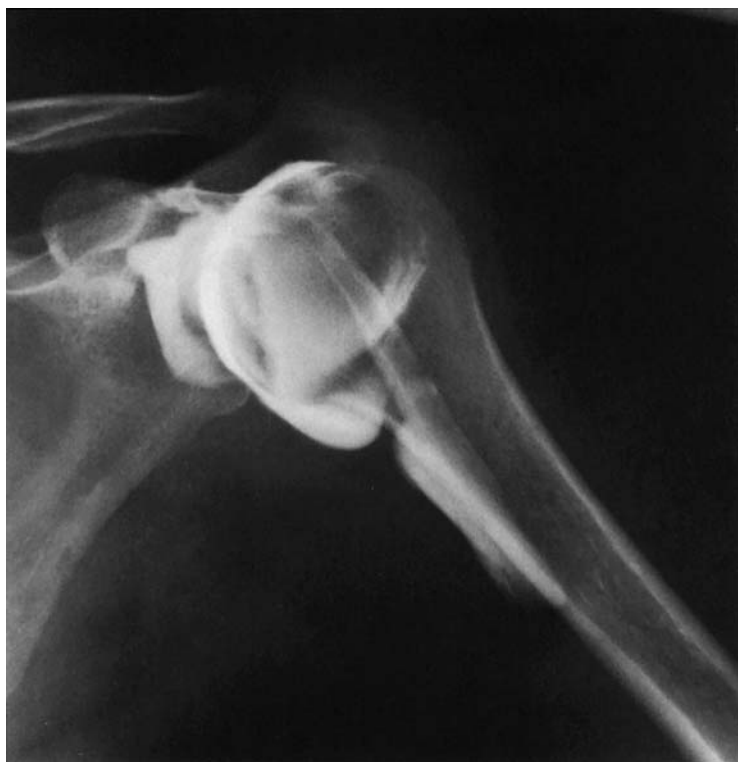- 4 Flexor recess
- 5 Ulna
- 6 Radius

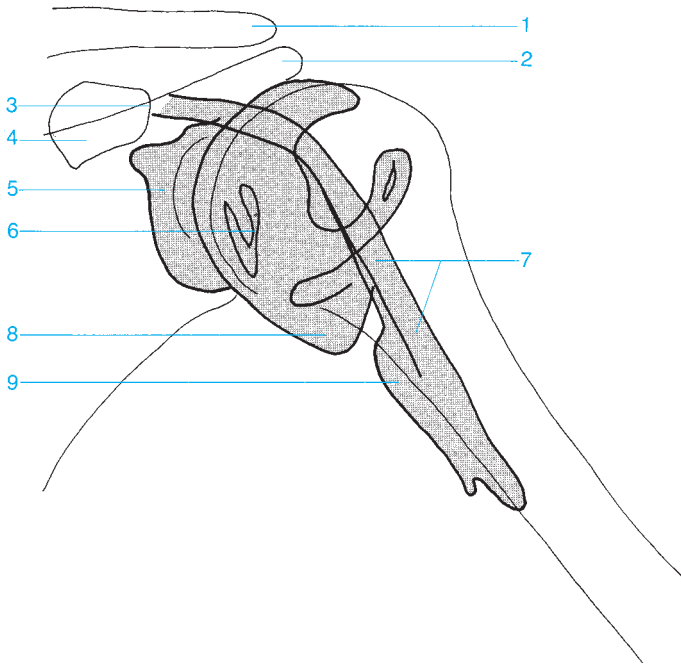




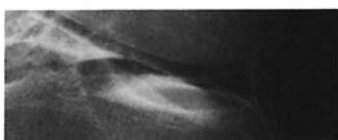
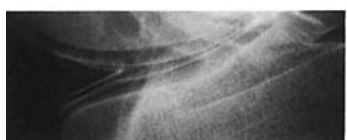
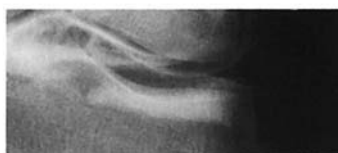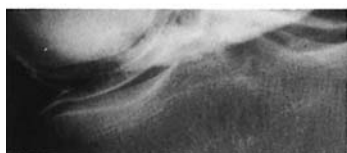
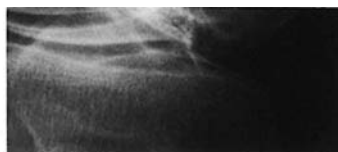
- 1 Clavicle
- 2 Acromion
- 3 Coracoid process
- 4 Subscapular bursa
- 5 Glenoid labrum

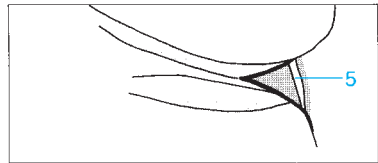
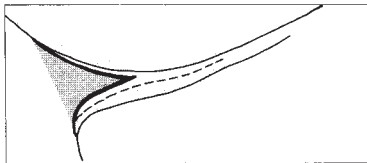
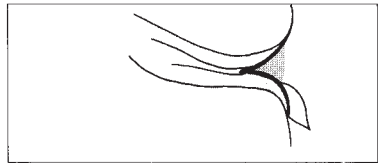
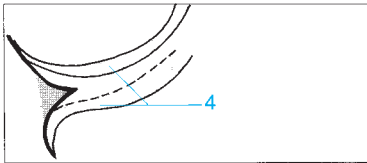

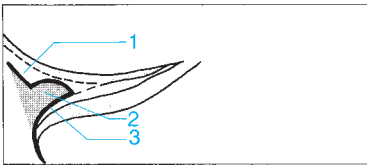
- 6 Axillary recess
- 7 Intertubercular sheath
- 8 Tendon sheath of the long head of the biceps





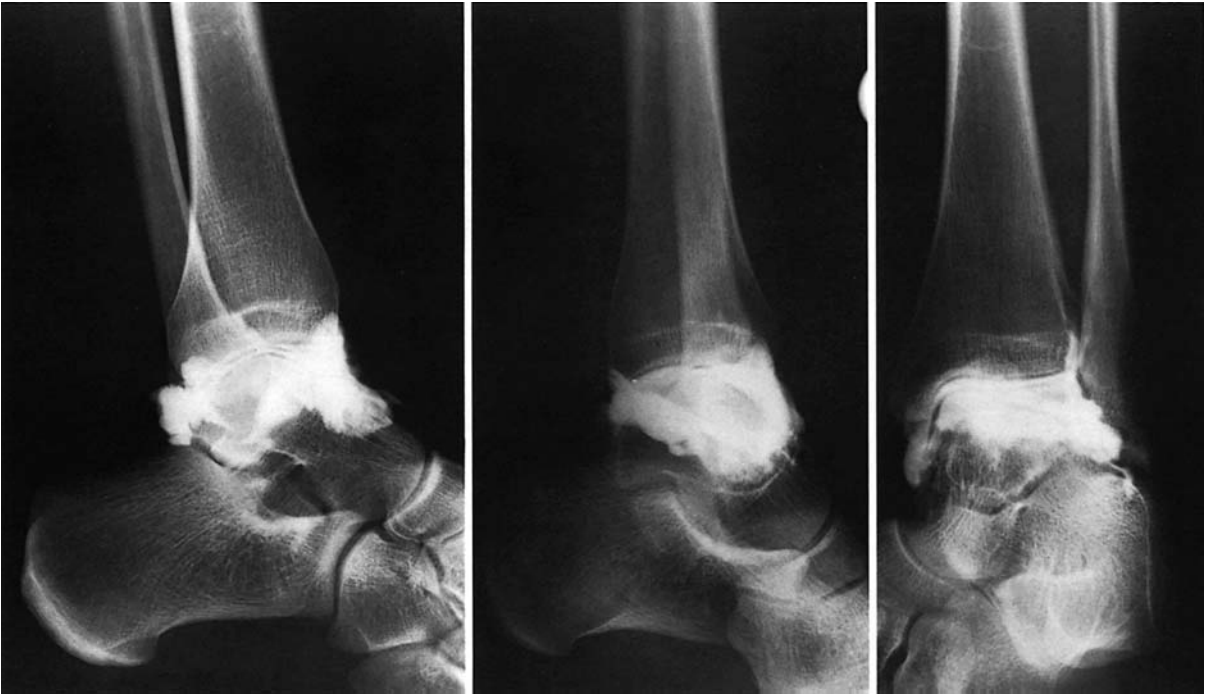- | | |
|----------------------------------|--|
| 1 Clavicle | 6 Glenoid labrum |
| 2 Acromion | 7 Tendon sheath of the long head of the biceps |
| 3 Insertion of the biceps tendon | 8 Axillary recess |
| 4 Coracoid process | 9 Intertubercular sheath |
| 5 Subscapular bursa | |





- 1 Superior capsular recess
- 2 Meniscus
- 3 Inferior capsular recess

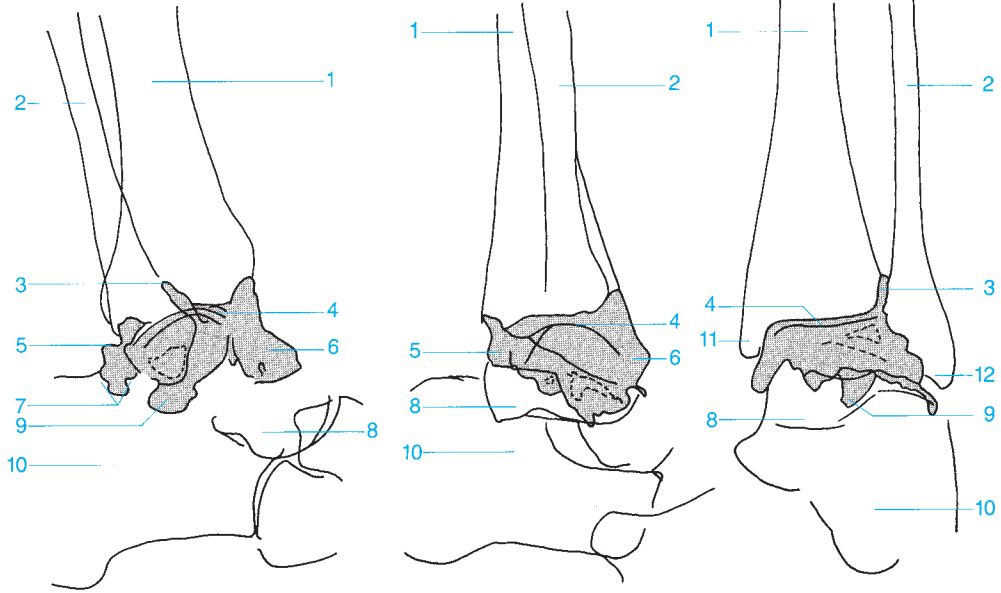
- 4 Cartilage
- 5 Popliteal bursa

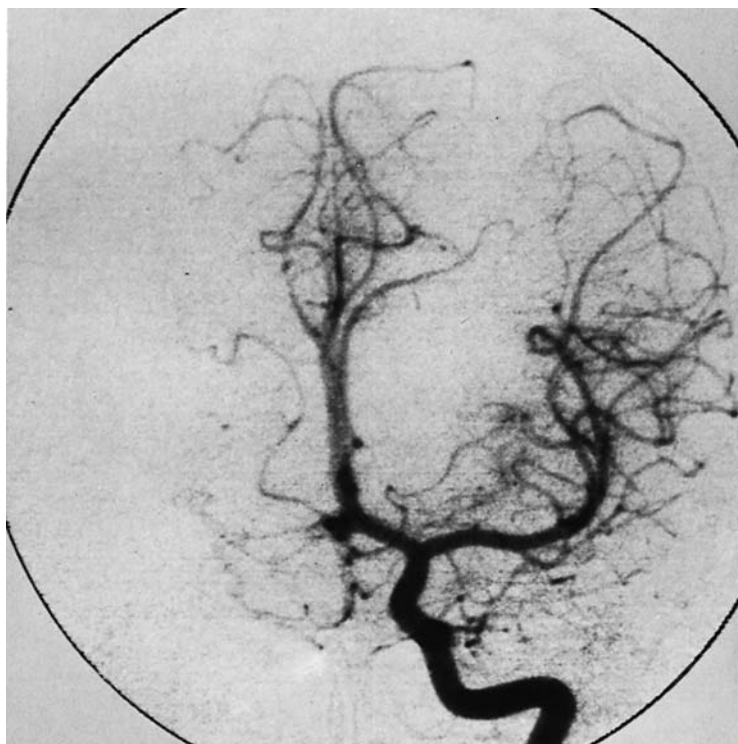


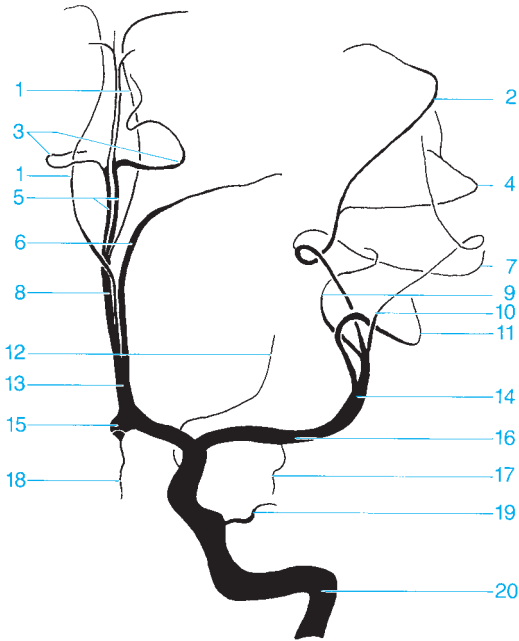
- 1 Tibia
- 2 Fibula
- 3 Tibiofibular joint
- 4 joint space

- 5 Posterior recess
- 6 Anterior recess
- 7 Tendon recesses (anatomy varies)
- 8 Talus

- 9 Supracalcaneal recess
- 10 Calcaneus
- 11 Medial malleolus
- 12 Lateral malleolus

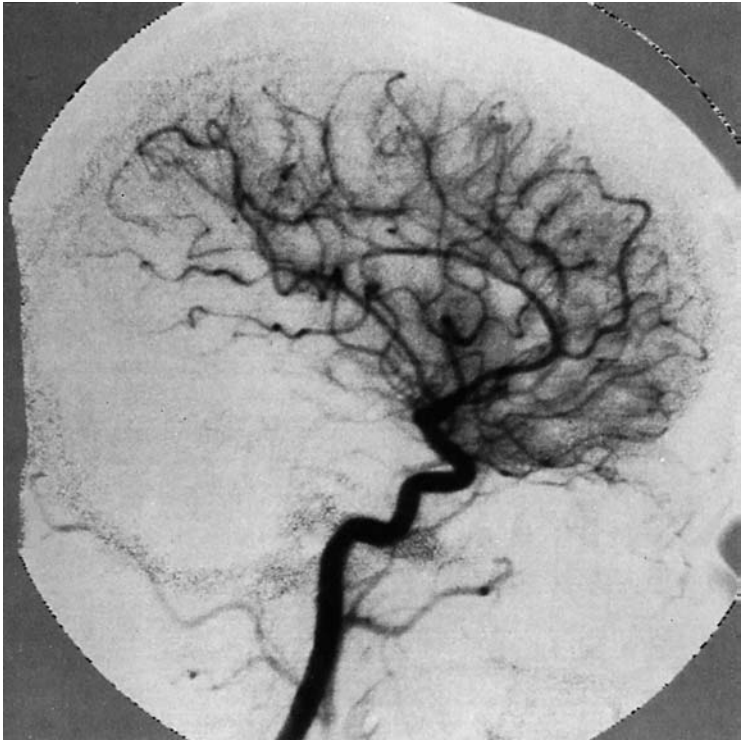






- 1 Callosomarginal artery
- 2 Anterior parietal artery
- 3 Pericallosal artery
- 4 Posterior parietal artery
- 5 Pericallosal artery (fourth segment of the anterior cerebral artery, superior to the corpus callosum)
- 6 Frontal polar artery
- 7 Precentral sulcal artery
- 8 Third segment of the anterior cerebral artery or pericallosal artery
- 9 Artery of the angular gyrus
- 10 Posterior temporal artery
- 11 Prefrontal arteries
- 12 Anterior choroidal artery

- 13 Second segment of the anterior cerebral artery (from here on referred to as the pericallosal artery)
- 14 Second segment of the middle cerebral artery
- 15 Anterior communicating artery of the cerebrum (obscured by a vascular arch)
- 16 First segment of the middle cerebral artery (sphenoid part)
- 17 Temporal polar artery
- 18 Frontal orbital artery
- 19 Ophthalmic artery
- 20 Internal carotid artery

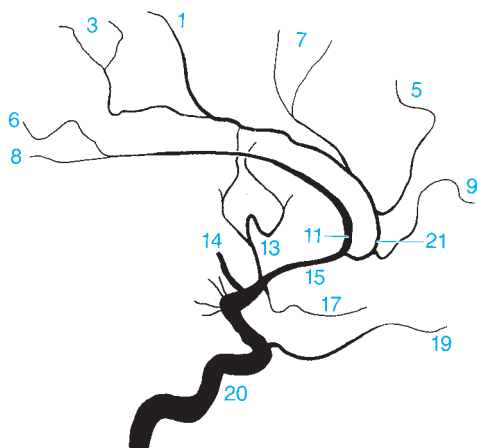


- 1 Posterior internal frontal artery
- 2 Anterior parietal artery
- 3 Paracentral artery
- 4 Posterior parietal artery
- 5 Anterior internal frontal artery
- 6 Superior internal parietal artery

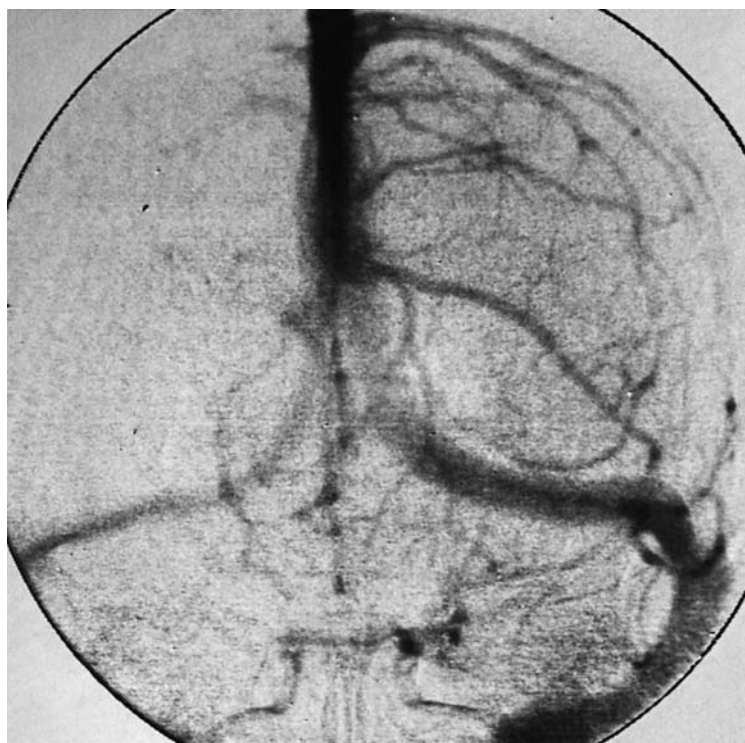
- 7 Medial internal frontal artery
- 8 Inferior internal parietal artery
- 9 Frontal polar artery
- 10 Artery of the angular gyrus
- 11 Pericallosal artery
- 12 Posterior temporal artery

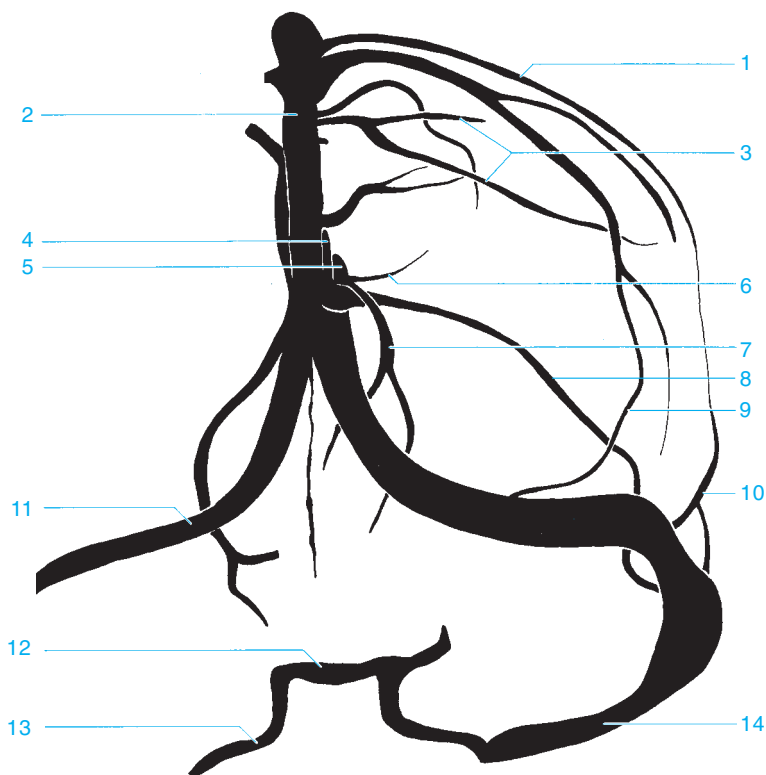


Variant (40 %)

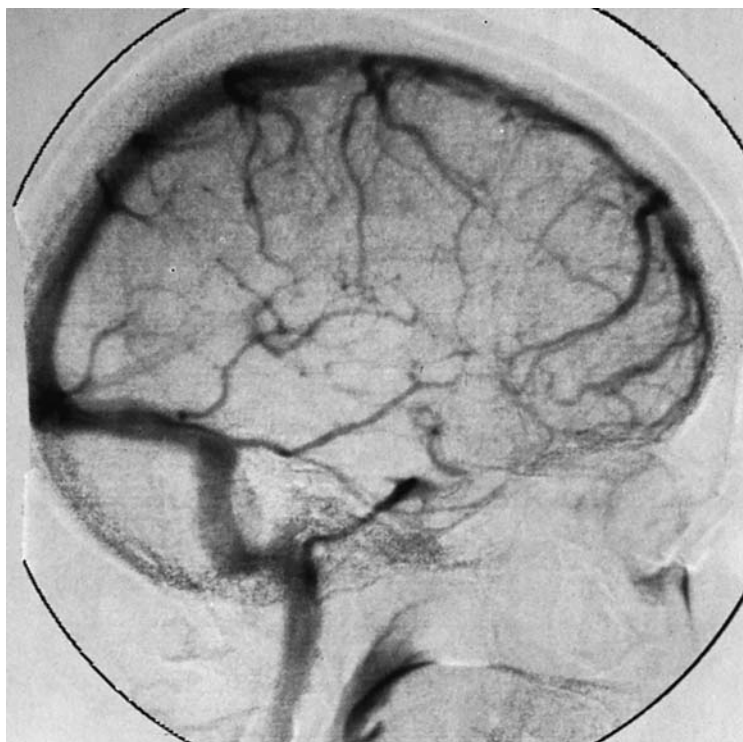


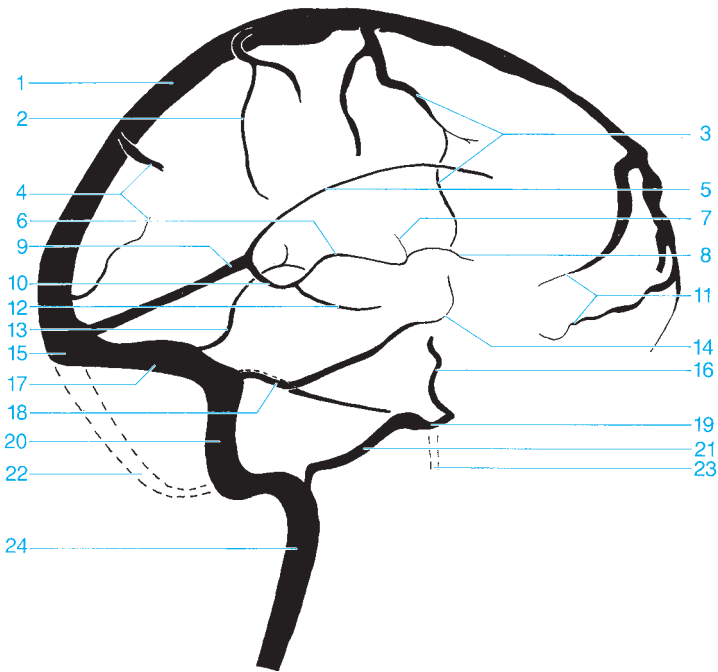
- | | |
|--|--|
| 13 Prefrontal arteries | 17 Frontal orbital artery |
| 14 Second segment of the middle cerebral artery | 18 Posterior communicating artery |
| 15 Second segment of the anterior cerebral artery | 19 Ophthalmic artery |
| 16 Anterior choroidal artery | 20 Internal carotid artery |
| | 21 Callosomarginal artery |





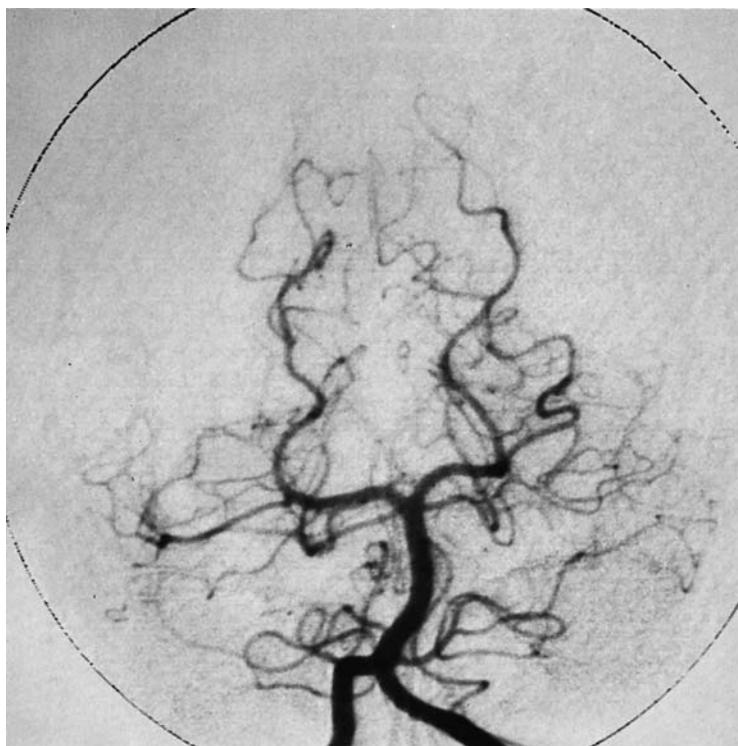
- | | |
|---|---------------------------------|
| 1 Parietal vein | 8 Frontal veins |
| 2 Superior sagittal sinus | 9 Veins of the fossa of Sylvius |
| 3 Superior anastomotic vein (vein of Trolard) | 10 Sphenoparietal sinus |
| 4 Great cerebral vein of Galen | 11 Transverse sinus |
| 5 Internal cerebral vein | 12 Intercavernous sinus |
| 6 Superior thalamostriate vein | 13 Inferior petrosal sinus |
| 7 Basal vein of Rosenthal | 14 Sigmoid sinus |

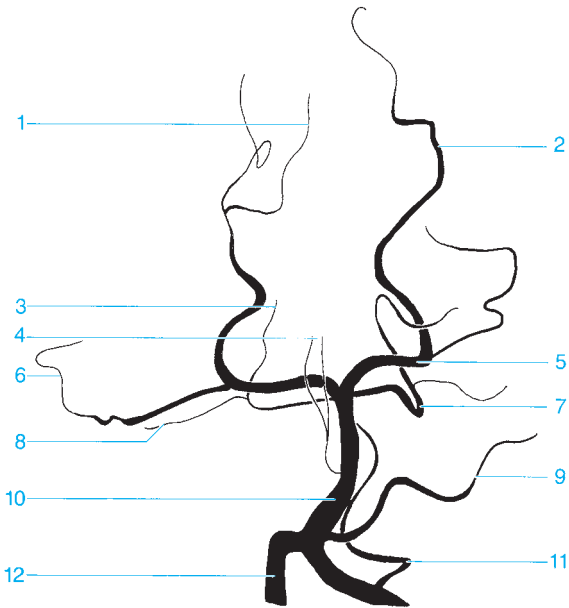




- 1 Superior sagittal sinus
- 2 Parietal vein
- 3 Superior anastomotic vein (vein of Trolard)
- 4 Occipital veins
- 5 Inferior sagittal sinus
- 6 Internal cerebral vein
- 7 Superior thalamostriate veins
- 8 Vein of the septum pellucidum
- 9 Straight sinus
- 10 Great cerebral vein of Galen
- 11 Ascending frontal veins
- 12 Basal vein of Rosenthal
- 13 Inferior anastomotic vein (vein of Labbé)

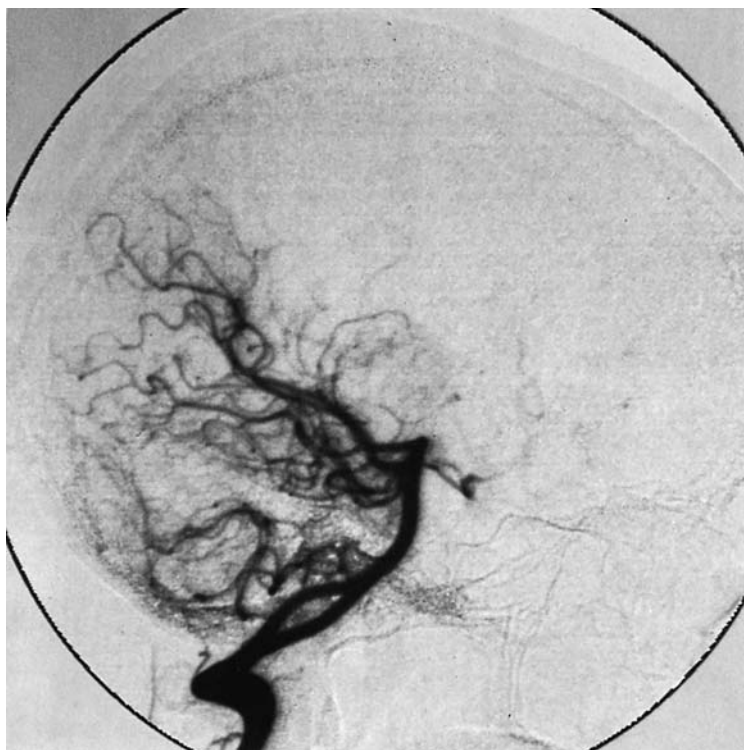- 14 Veins of the fossa of Sylvius
- 15 Confluence of sinuses
- 16 Cavernous sinus (anterior drainage)
- 17 Transverse sinus
- 18 Superior petrosal sinus
- 19 Cavernous sinus (posterior drainage)
- 20 Sigmoid sinus
- 21 Inferior petrosal sinus
- 22 Occipital sinus
- 23 Pterygoid plexus
- 24 Internal jugular vein

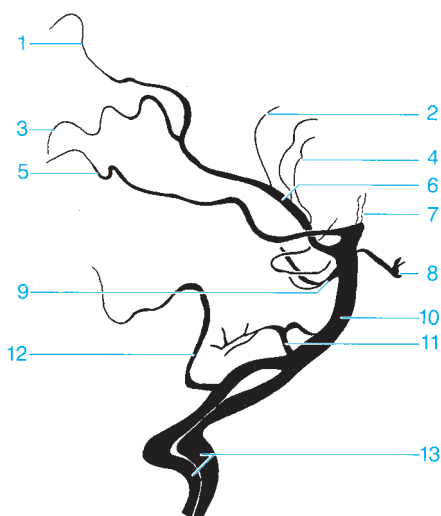




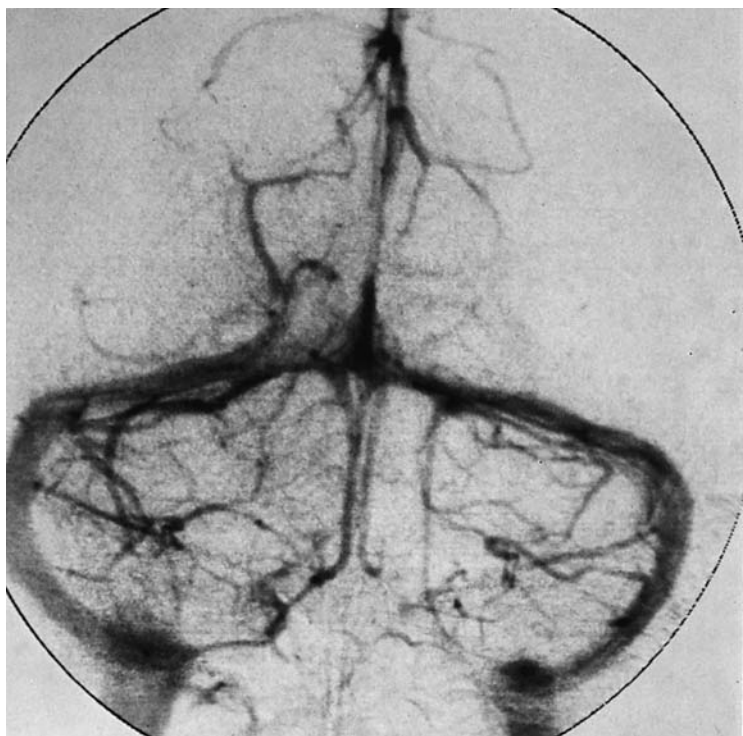- 1 Calcarine branch of the medial occipital artery
- 2 Parieto-occipital artery
- 3 Vermis branch
- 4 Thalamoperforate arteries
- 5 Posterior cerebral artery
- 6 Temporo-occipital artery

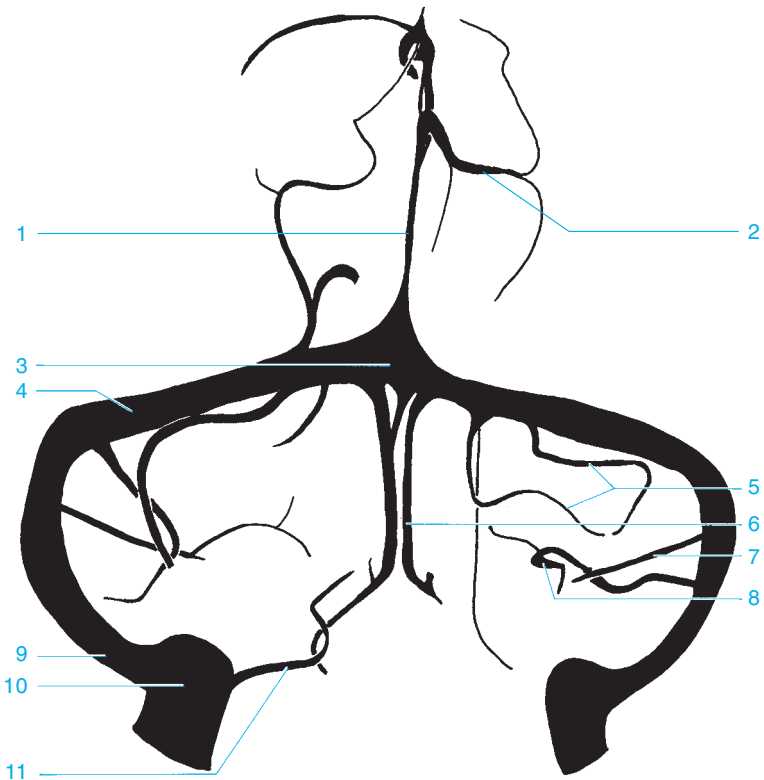
- 7 Superior cerebellar artery
- 8 Marginal artery
- 9 Anterior inferior cerebellar artery
- 10 Basilar artery
- 11 Posterior inferior cerebellar artery
- 12 Vertebral artery



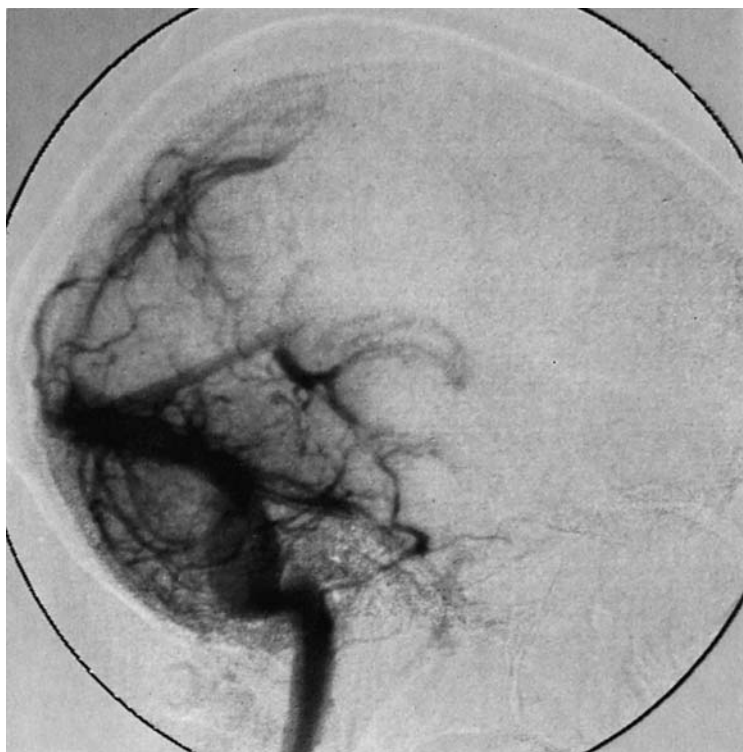


- | | |
|---|---|
| 1 Parieto-occipital artery | 7 Branches of the posterior cerebral artery to the thalamus |
| 2 Dorsal corpus callosal branch | 8 Posterior communicating artery |
| 3 Calcarine branch of the medial occipital artery | 9 Superior cerebellar artery |
| 4 Choroidal arteries (posterior, medial, and lateral) | 10 Basilar artery |
| 5 Temporo-occipital artery | 11 Anterior inferior cerebellar artery |
| 6 Posterior cerebral artery | 12 Posterior inferior cerebellar artery |
| | 13 Vertebral arteries |



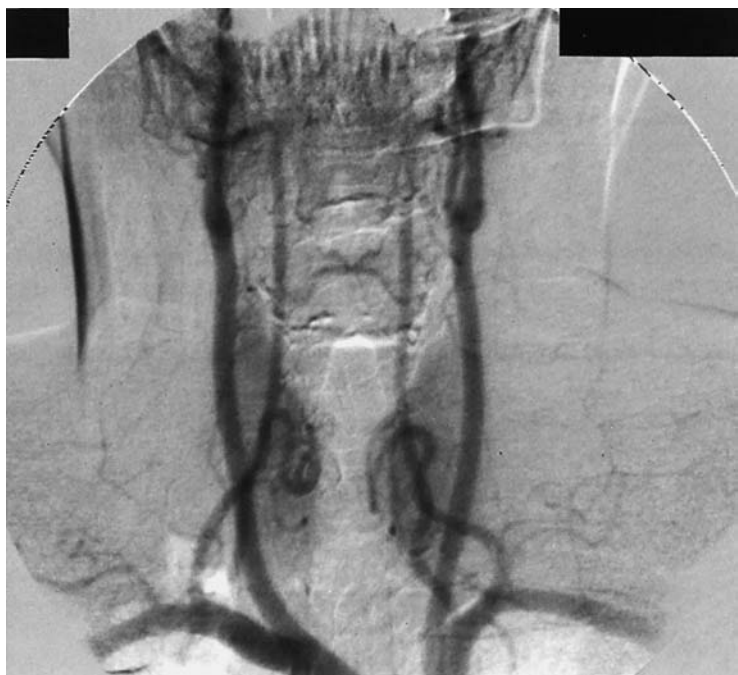

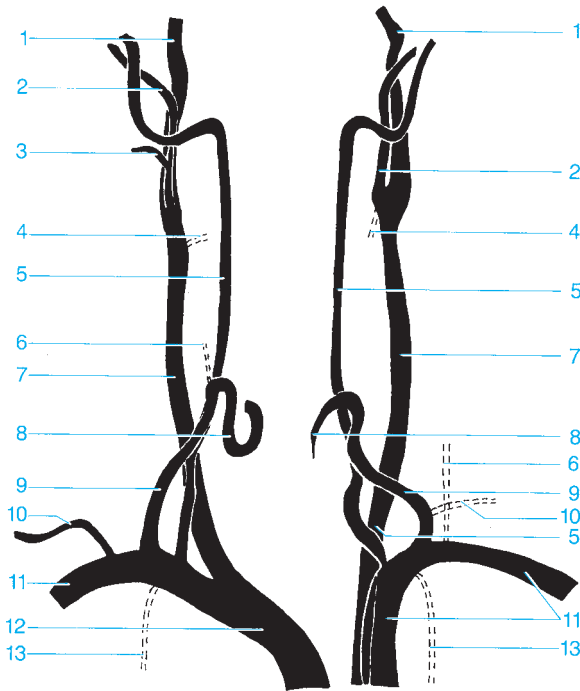
- | | |
|--|--|
| 1 Straight sinus | 8 Petrosal vein (entering the superior petrosal sinus) |
| 2 Superior cerebral veins | 9 Sigmoid sinus |
| 3 Confluence of sinuses | 10 Bulb of the jugular vein |
| 4 Transverse sinus | 11 Inferior petrosal sinus |
| 5 Veins of the cerebellar hemisphere | |
| 6 Inferior vein of the vermis | |
| 7 Inferior vein of the cerebellar hemisphere | |





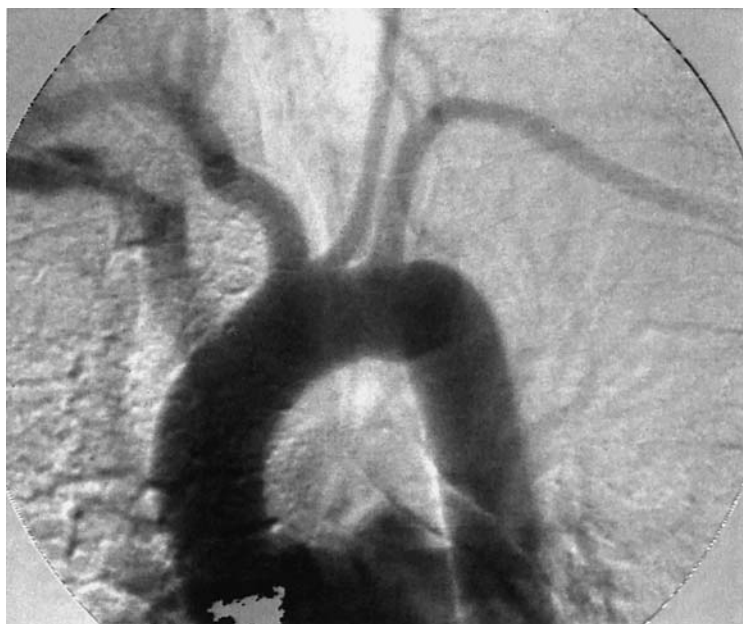- | | |
|---|--|
| 1 Superior veins of the cerebellar hemisphere | 9 Inferior veins of the cerebellar hemisphere |
| 2 Great cerebral vein of Galen | 10 Cavernous sinus |
| 3 Internal cerebral vein | 11 Inferior veins of the cerebellar hemisphere |
| 4 Straight sinus | 12 Superior petrosal sinus |
| 5 Basal vein of Rosenthal | 13 Inferior petrosal sinus |
| 6 Precentral cerebellar vein | 14 Sigmoid sinus |
| 7 Confluence of sinuses | |
| 8 Transverse sinus | |

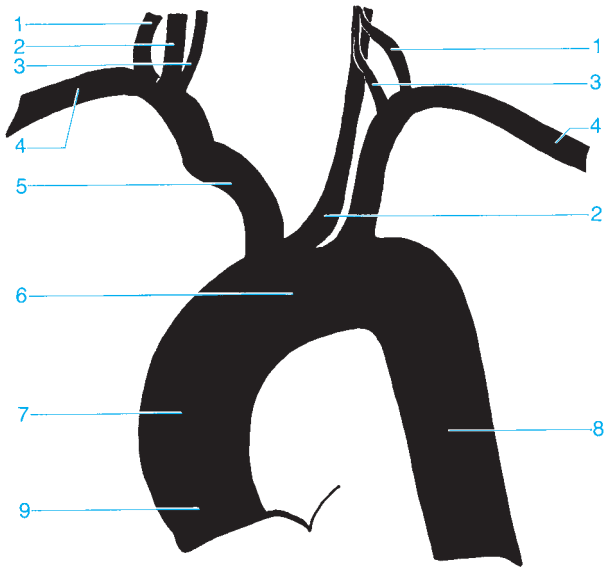




- 1 Internal carotid artery
- 2 External carotid artery
- 3 Facial artery
- 4 Superior thyroid artery
- 5 Vertebral artery
- 6 Ascending cervical artery
- 7 Common carotid artery

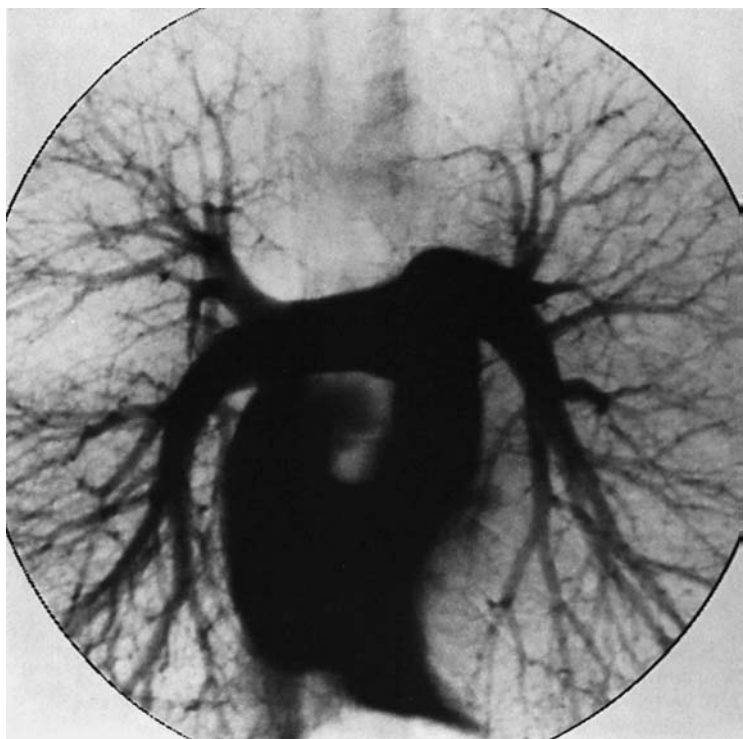
- 8 Inferior thyroid artery
- 9 Thyrocervical trunk
- 10 Suprascapular artery
- 11 Subclavian artery
- 12 Brachiocephalic trunk
- 13 Internal thoracic artery

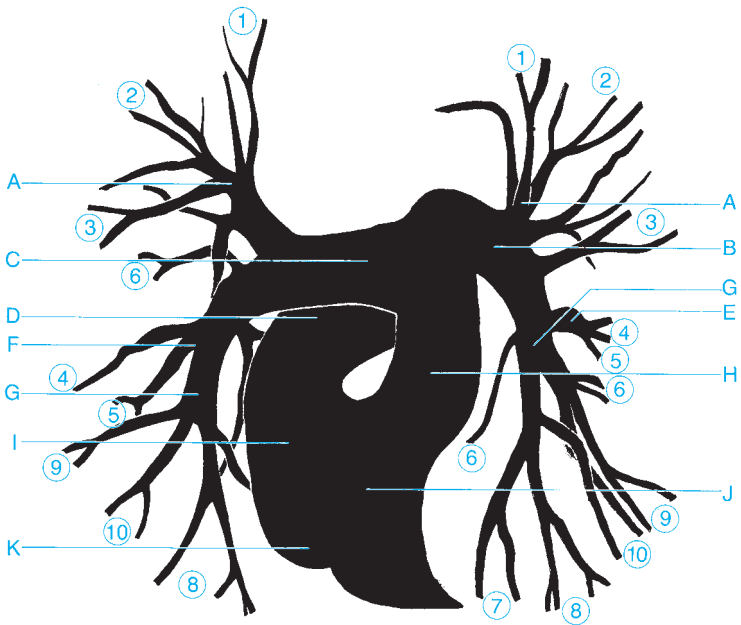




- 1 Thyrocervical trunk
- 2 Common carotid artery
- 3 Vertebral artery
- 4 Subclavian artery
- 5 Brachiocephalic trunk

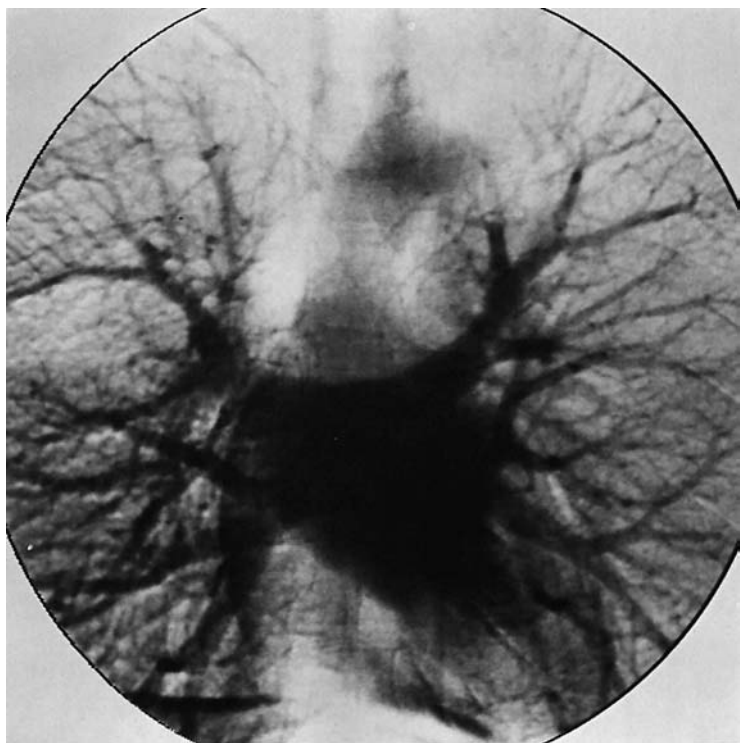
- 6 Aortic arch
- 7 Ascending aorta
- 8 Descending aorta
- 9 Aortic bulb

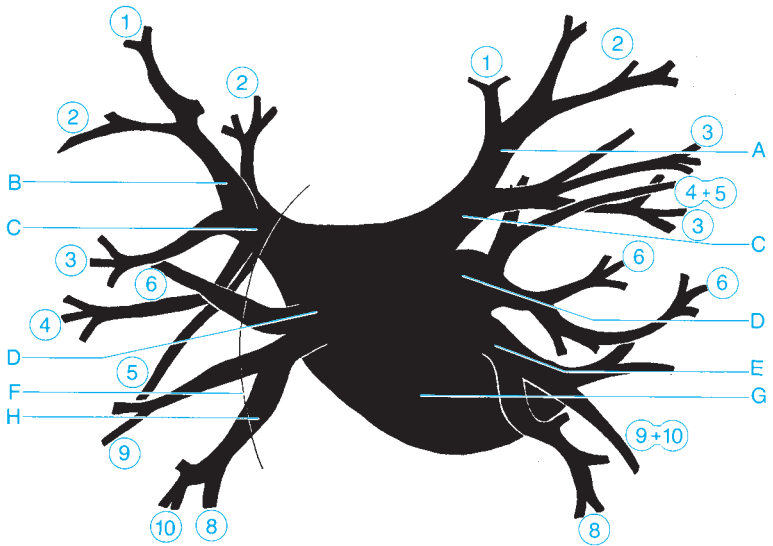




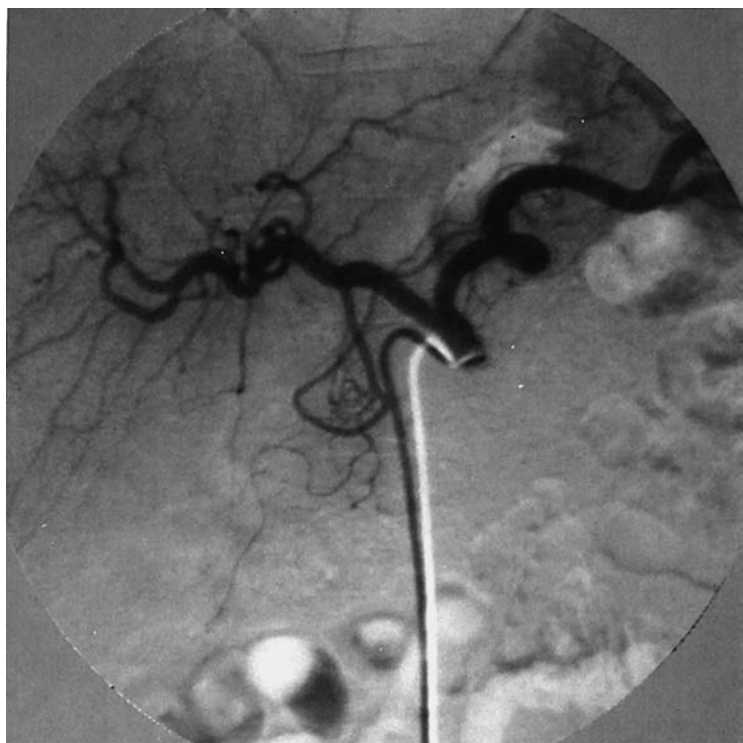
○ = Segmental arteries 1–10

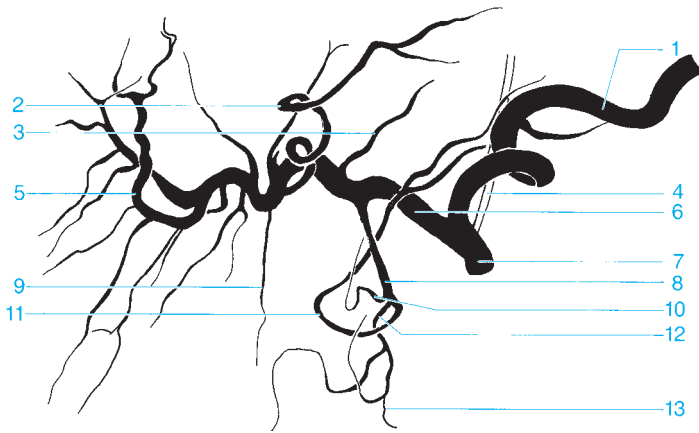
- | | |
|--|--|
| A Apical branch | G Inferior lobar branch of the pulmonary artery |
| B Left pulmonary artery | H Pulmonary trunk |
| C Right pulmonary artery | I Right atrium |
| D Superior vena cava | J Right ventricle |
| E Lingular branch | K Inferior vena cava |
| F Middle lobar branch of the pulmonary artery | |



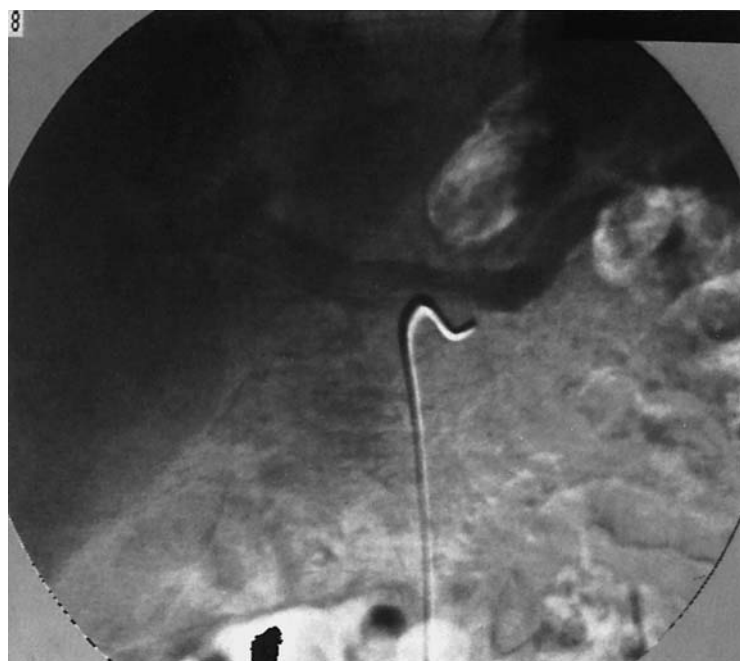

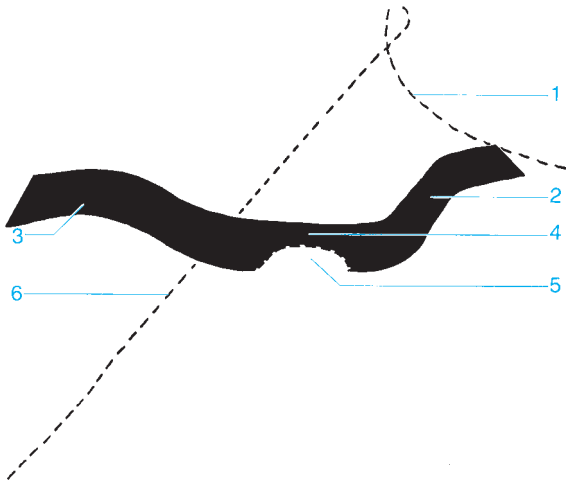
- | | |
|----------------------------------|------------------------------|
| A Apicoposterior branch | E Common basal vein |
| B Apical branch | F Right atrium |
| C Inferior pulmonary vein | G Left atrium |
| D Superior pulmonary vein | H Inferior basal vein |





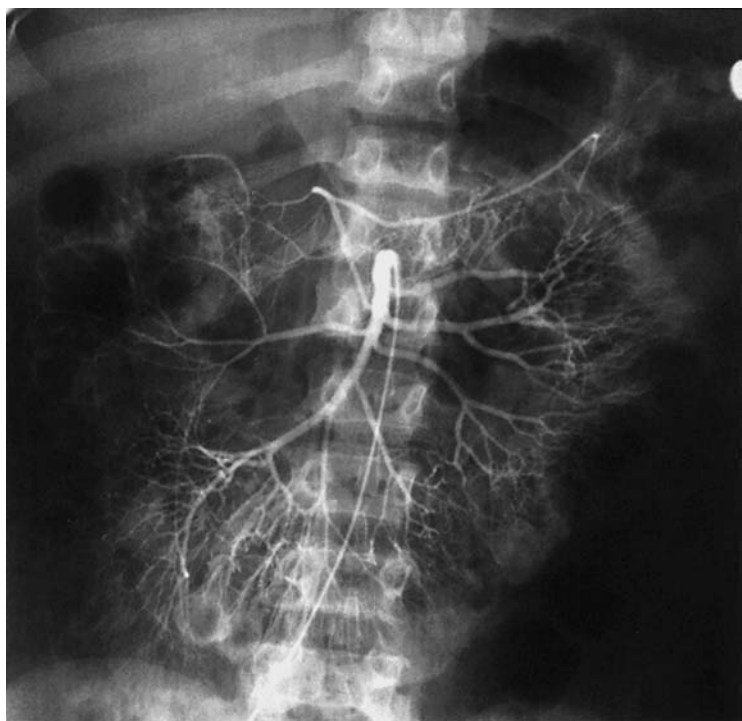
- | | |
|--|---|
| 1 Splenic artery | 8 Gastroduodenal artery |
| 2 Left branch of the proper hepatic artery | 9 Cystic artery |
| 3 Right gastric artery | 10 superior supraduodenal artery |
| 4 Left gastric artery | 11 Right gastroepiploic artery |
| 5 Right branch of the proper hepatic artery | 12 Superior pancreaticoduodenal artery |
| 6 Common hepatic artery | 13 Inferior pancreaticoduodenal artery (anastomosis with the superior mesenteric artery) |
| 7 Celiac trunk | |

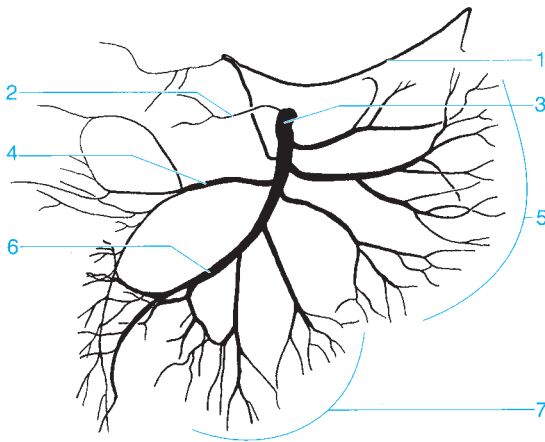




- 1 Spleen
- 2 Splenic vein
- 3 Portal vein

- 4 Confluence
- 5 Junction of the mesenteric vein
- 6 Liver





1 Middle colic artery

2 Inferior pancreaticoduodenal artery

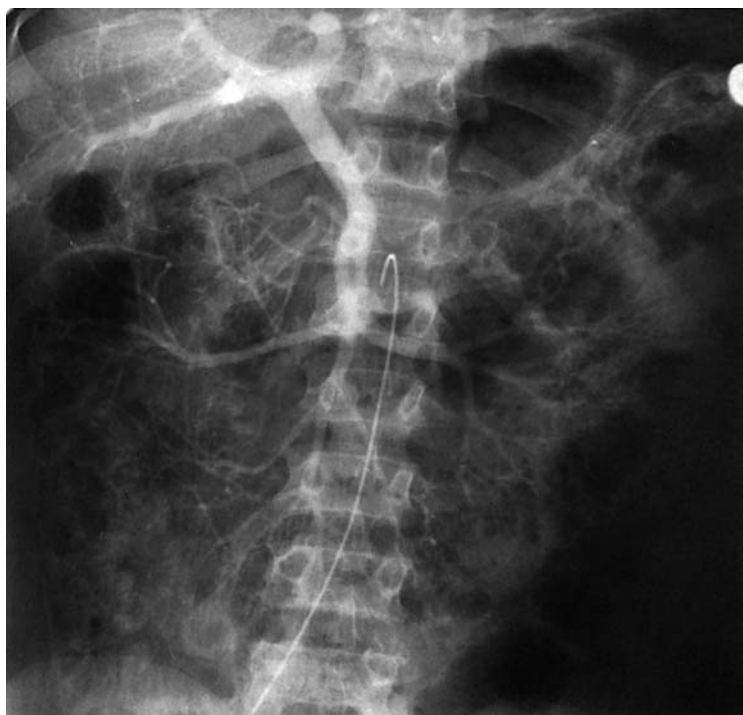3 Superior mesenteric artery

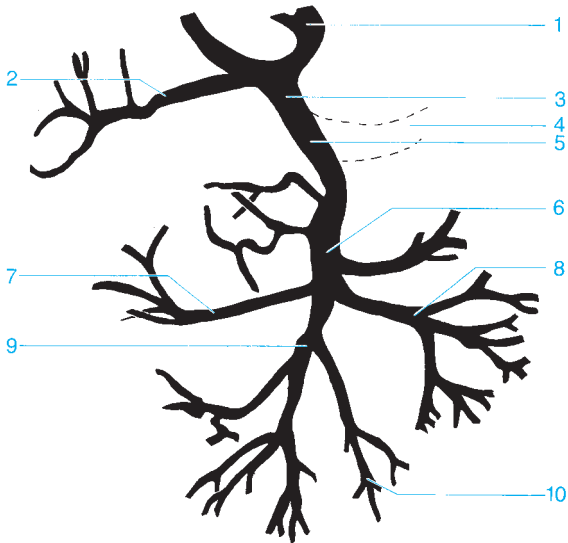
4 Right colic artery

5 Jejunal arteries

6 Ileocolic artery

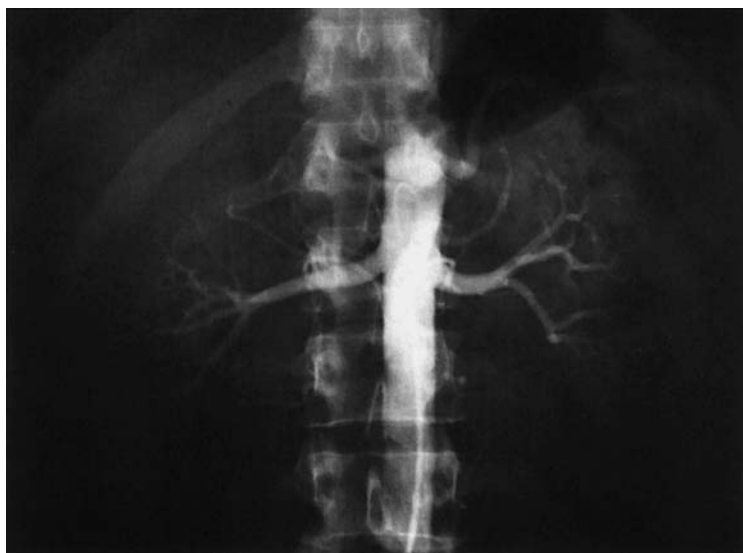7 Ileal arteries

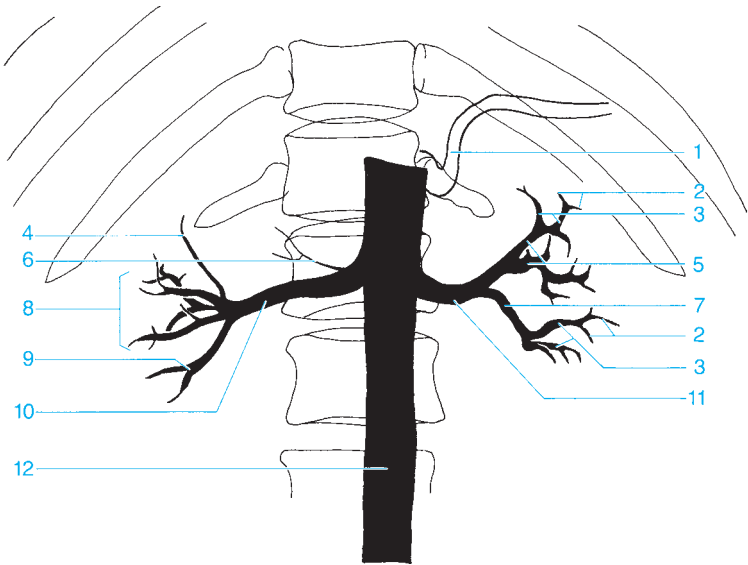




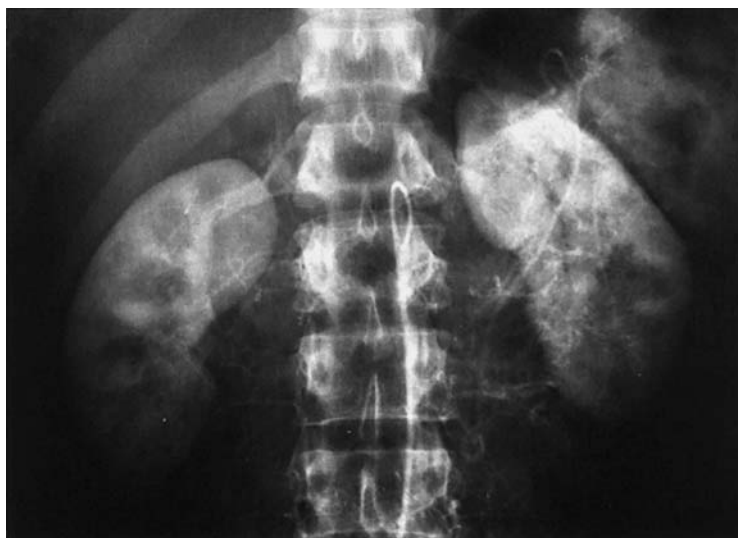- 1 Left branch of the portal vein
- 2 Right branch of the portal vein
- 3 Portal vein
- 4 Splenic vein
- 5 Confluence

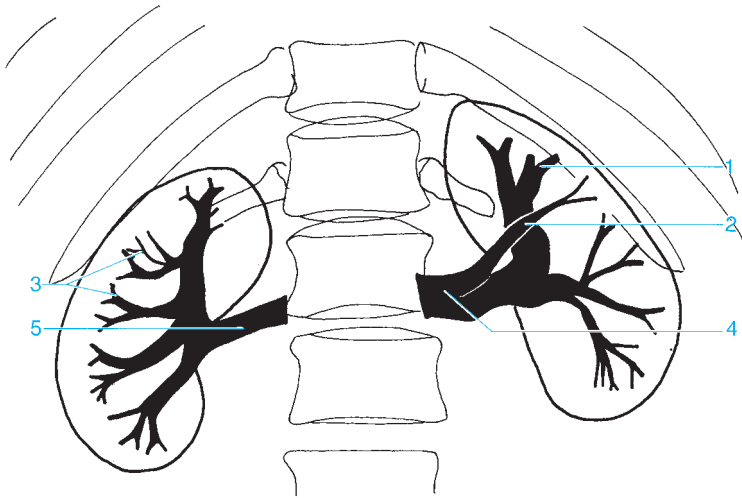
- 6 Superior mesenteric vein
- 7 Right colic vein
- 8 Jejunal veins
- 9 Ileocolic vein
- 10 Ileal veins



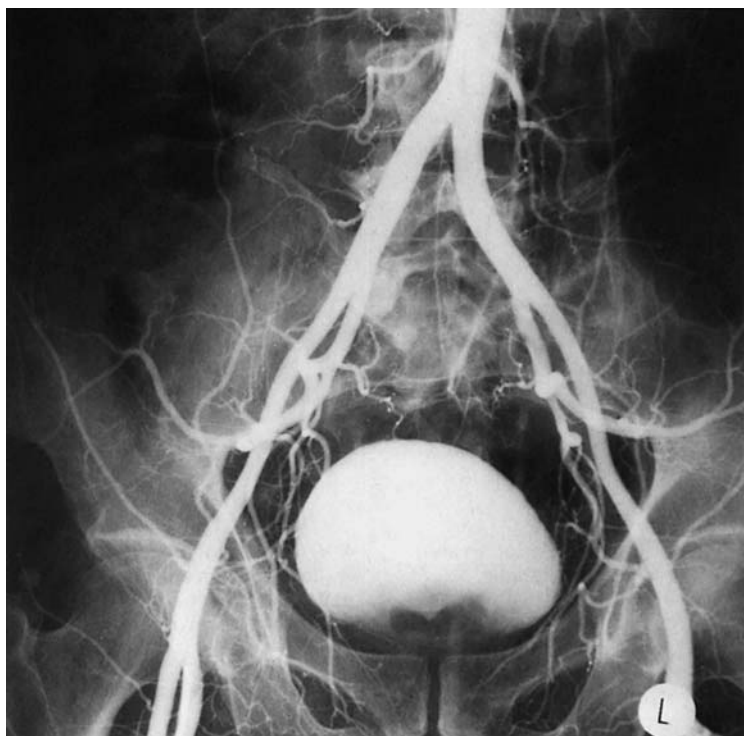

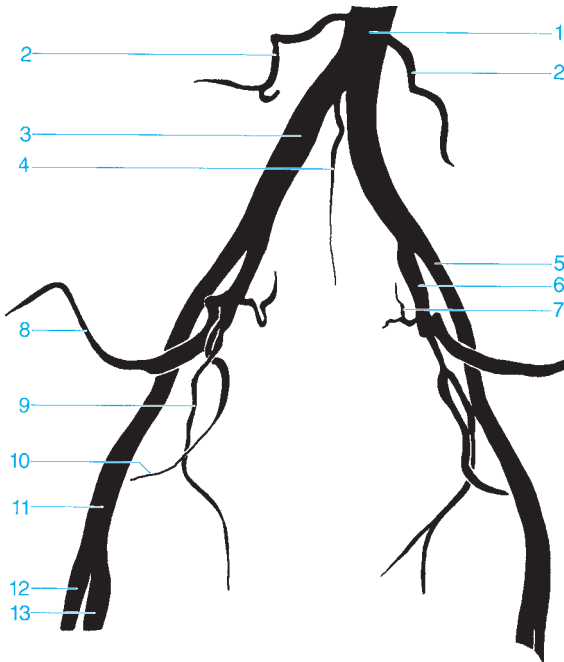
- | | |
|--|---|
| 1 Splenic artery | 7 Segmental arteries (posterior branch) |
| 2 Arcuate arteries | 8 Middle segmental artery |
| 3 Interlobular arteries | 9 Inferior segmental artery |
| 4 Superior segmental artery | 10 Right renal artery |
| 5 Segmental arteries (anterior branch) | 11 Left renal artery |
| 6 Inferior adrenal artery | 12 Abdominal aorta |





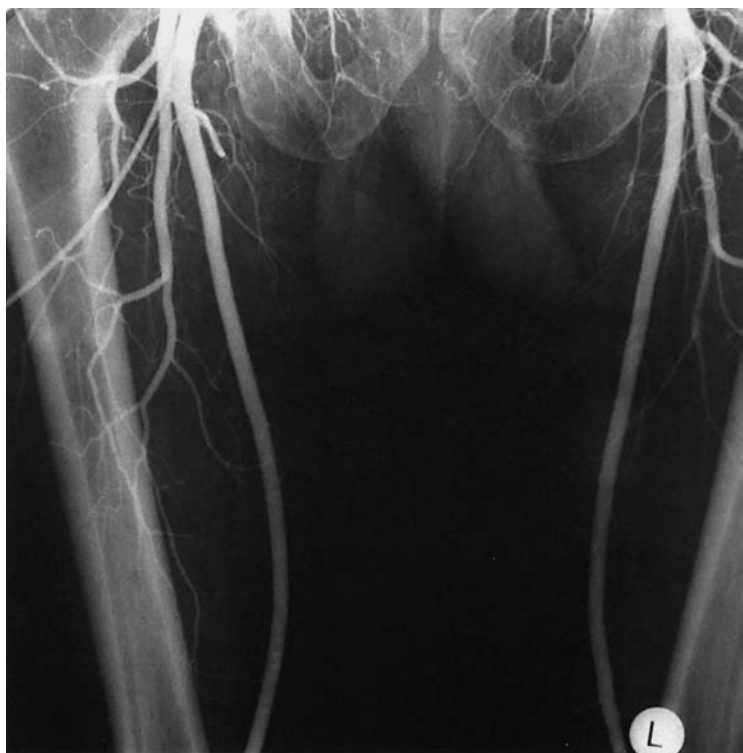- | | |
|-------------------------------------|--------------------|
| 1 Interlobular vein | 4 Left renal vein |
| 2 Superior branch of the renal vein | 5 Right renal vein |
| 3 Arcuate vein | |

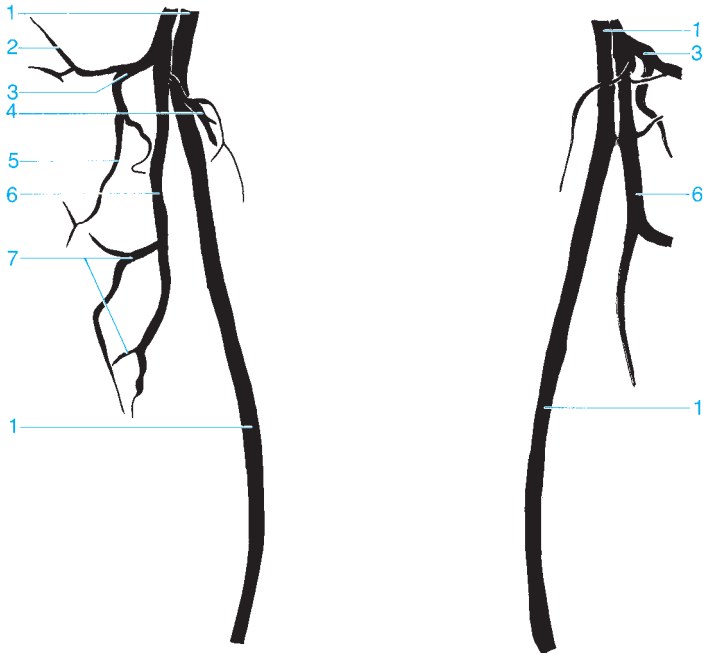




- 1 Abdominal aorta
- 2 Lumbar artery
- 3 Common iliac artery
- 4 Median sacral artery
- 5 External iliac artery
- 6 Internal iliac artery
- 7 Lateral sacral artery

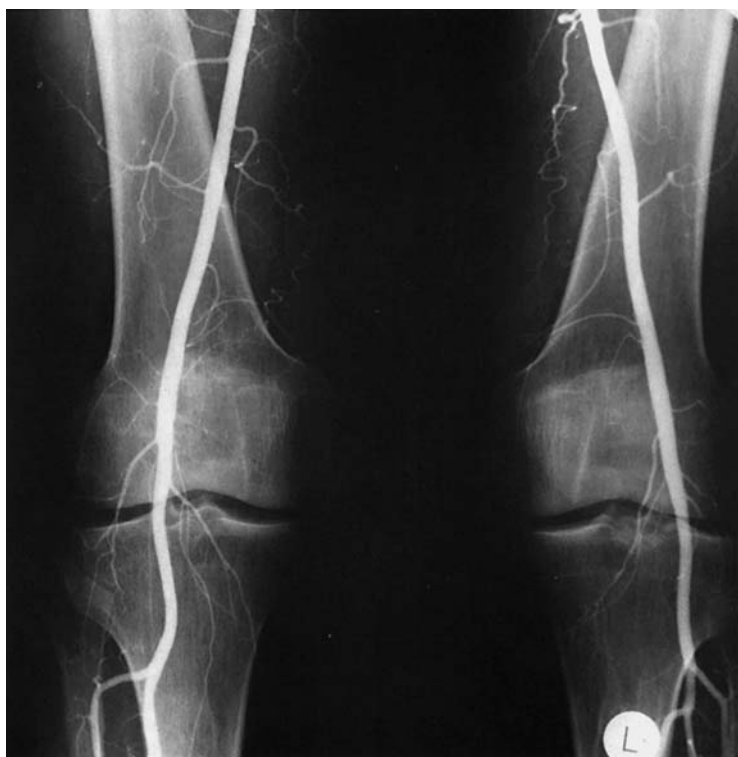- 8 Superior gluteal artery
- 9 Obturator artery
- 10 Inferior gluteal artery
- 11 Common femoral artery
- 12 Deep femoral artery
- 13 Superficial femoral artery

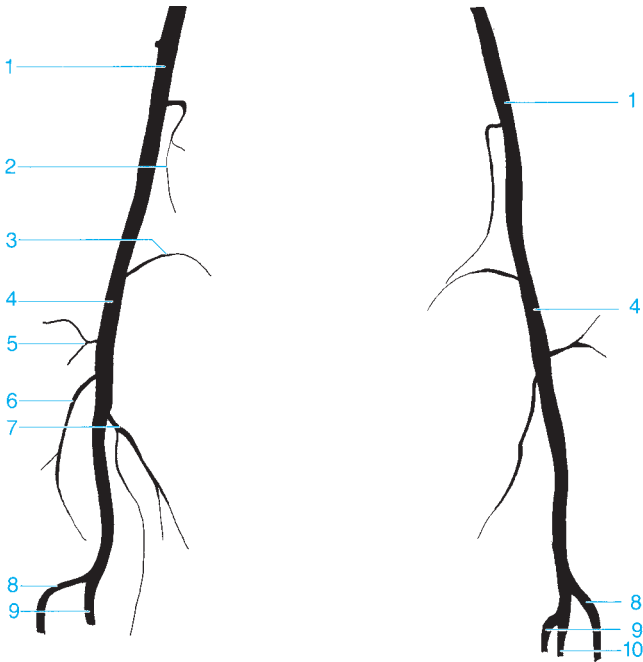




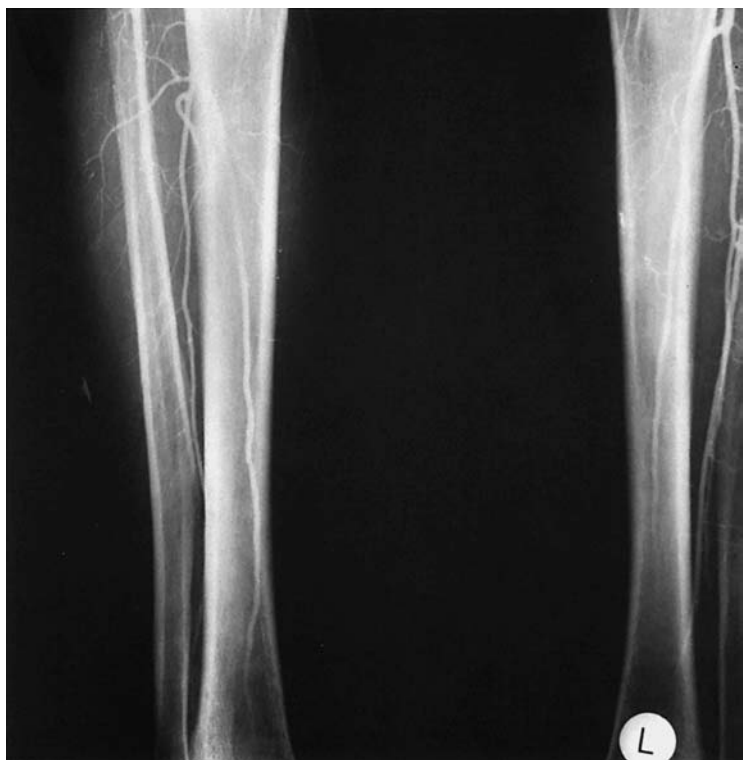- 1 Superficial femoral artery
- 2 Ascending branch of the lateral femoral circumflex artery
- 3 Lateral femoral circumflex artery
- 4 Medial femoral circumflex artery

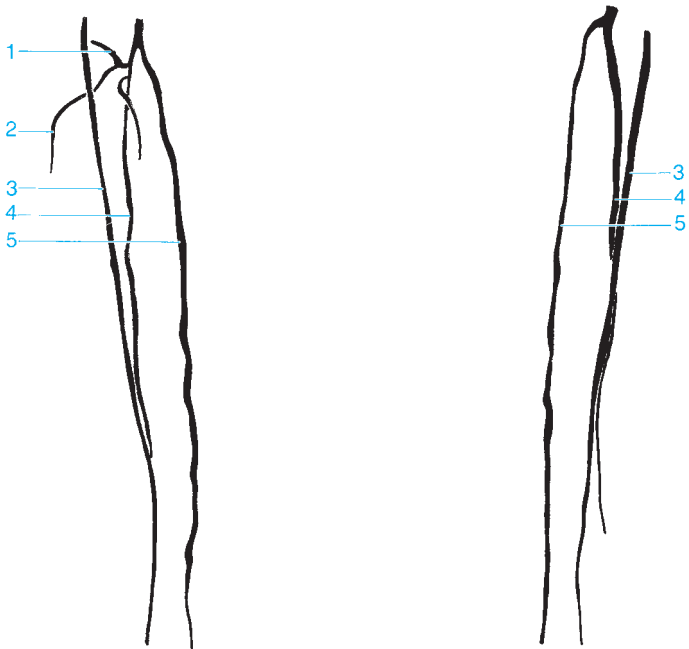
- 5 Descending branch of the lateral femoral circumflex artery
- 6 Deep femoral artery
- 7 Perforating artery





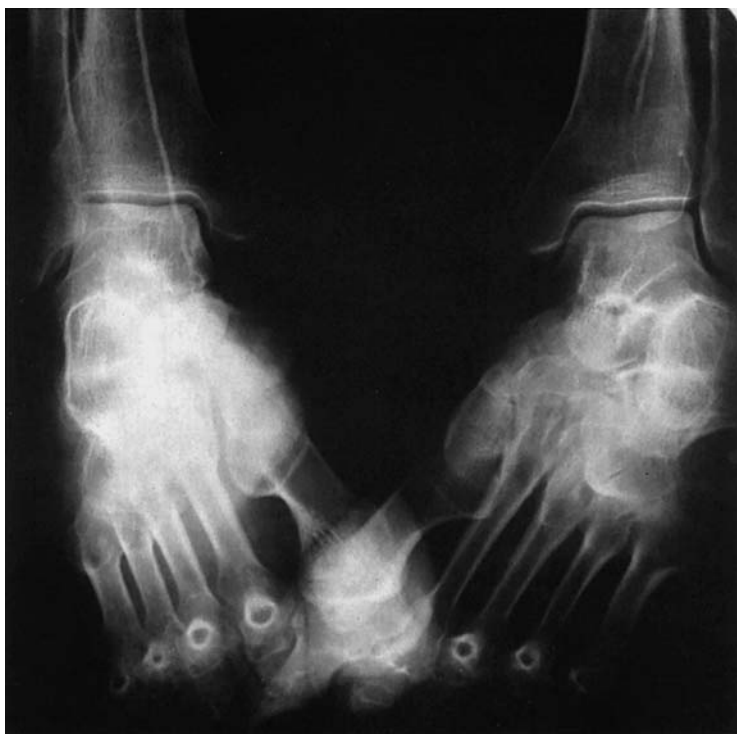- | | |
|--|---|
| 1 Superficial femoral artery | 6 Middle genicular artery |
| 2 Descending genicular artery | 7 Inferior medial genicular artery |
| 3 Superior medial genicular artery | 8 Anterior tibial artery |
| 4 Popliteal artery | 9 Posterior tibial artery |
| 5 Superior lateral genicular artery | 10 Peroneal artery |

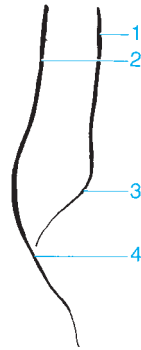
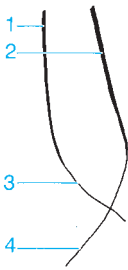



- 1 Circumflex fibular artery
- 2 Muscular branch
- 3 Anterior tibial artery

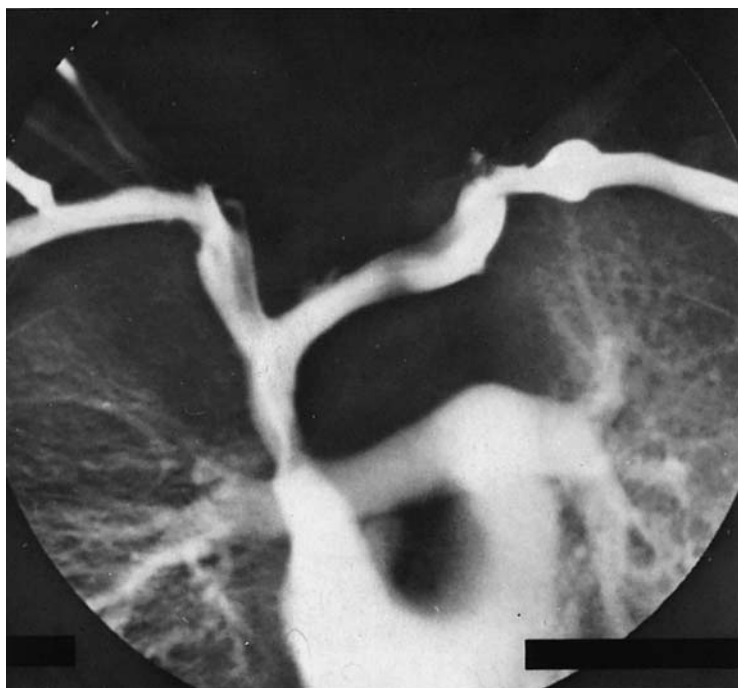- 4 Peroneal artery
- 5 Posterior tibial artery






- 1 Anterior tibial artery
- 2 Posterior tibial artery

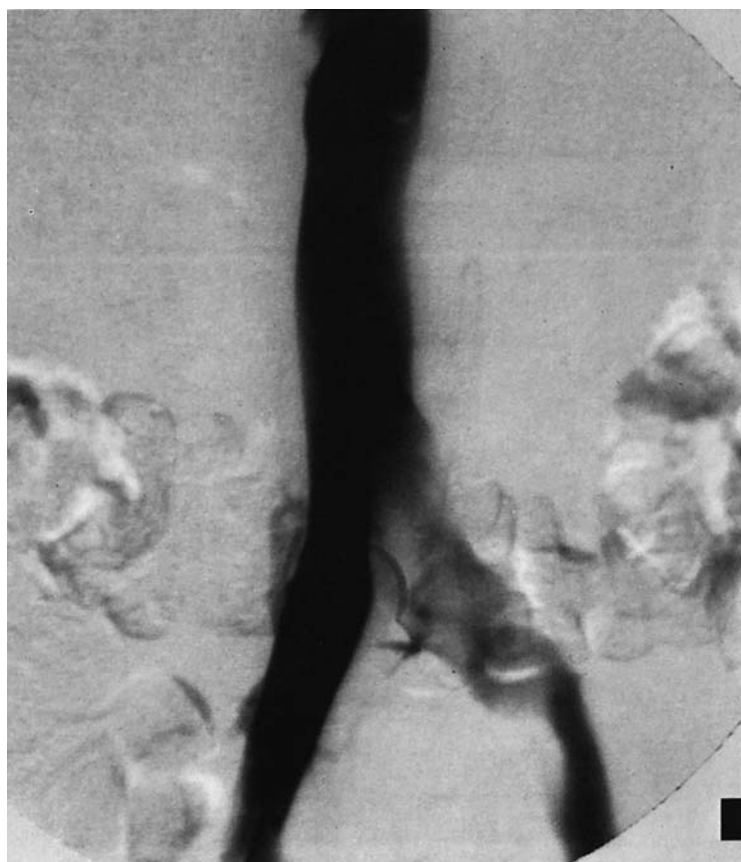- 3 Dorsalis pedis artery
- 4 Plantar artery

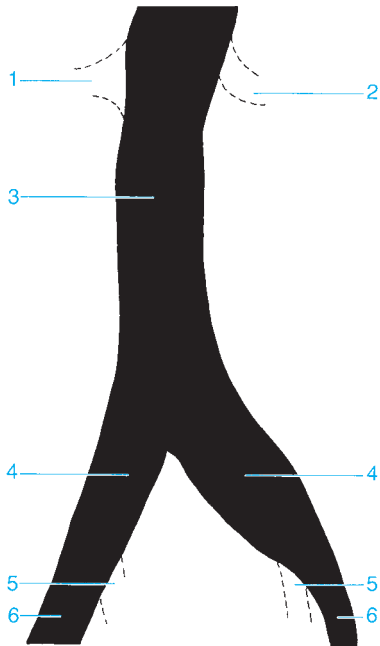




- 1 Internal jugular vein
- 2 External jugular vein
- 3 Cephalic vein
- 4 Subclavian vein
- 5 Left brachiocephalic vein
- 6 Inferior thyroid vein
- 7 Venous angle
- 8 Right brachiocephalic vein

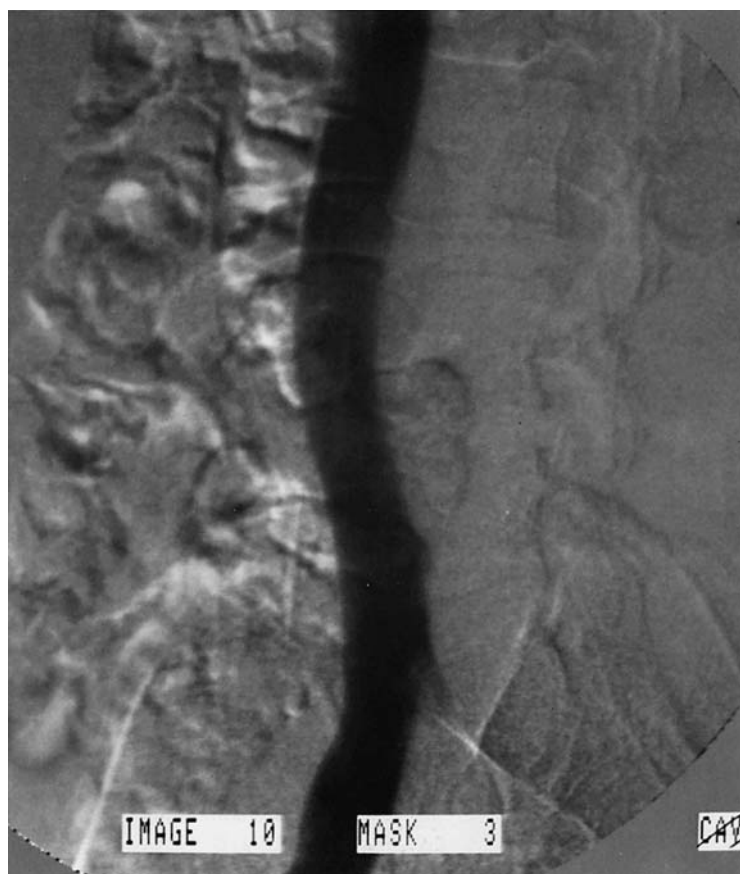
- 9 Azygos vein
- 10 Superior vena cava
- 11 Pulmonary trunk
- 12 Right pulmonary artery
- 13 Left pulmonary artery
- 14 Infundibulum
- 15 Right atrium
- 16 Right ventricle

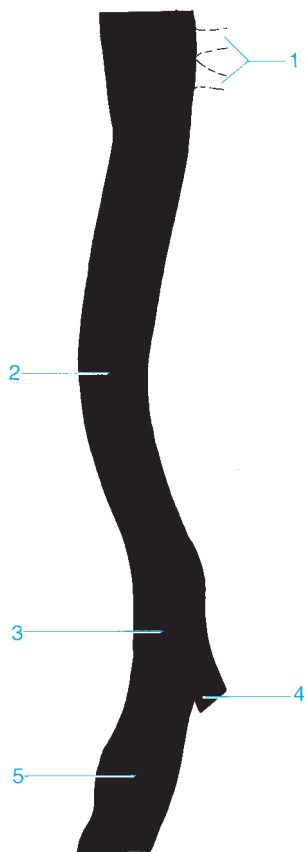




- 1 Right renal vein
- 2 Left renal vein
- 3 Inferior vena cava

- 4 Common iliac vein
- 5 Internal iliac vein
- 6 External iliac vein





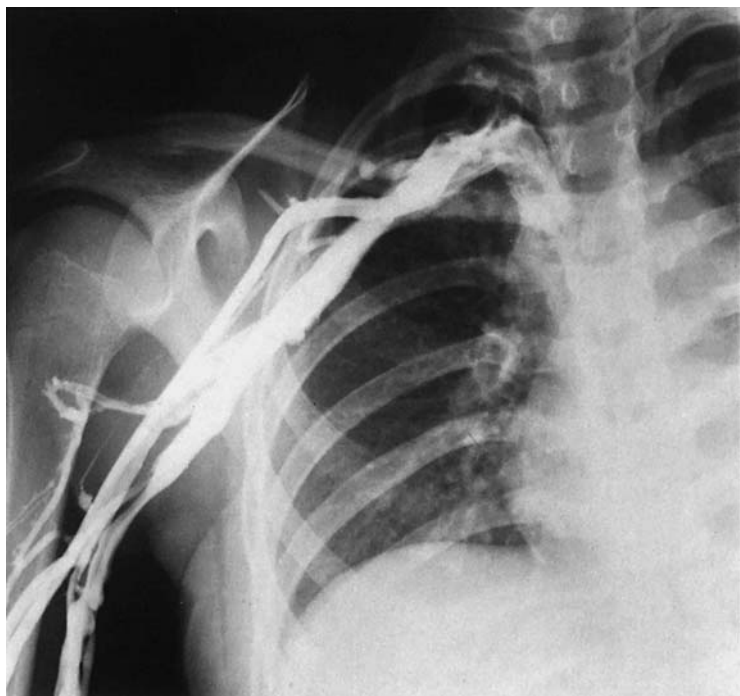
1 Renal veins

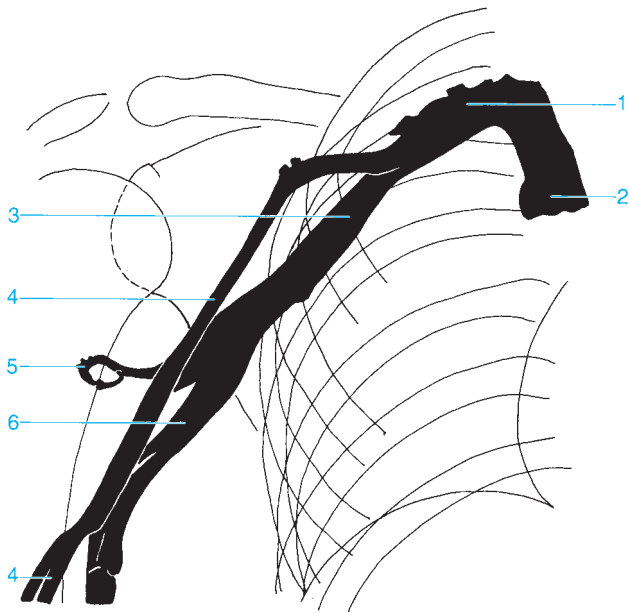
2 Inferior vena cava

3 Common iliac vein

4 Internal iliac vein

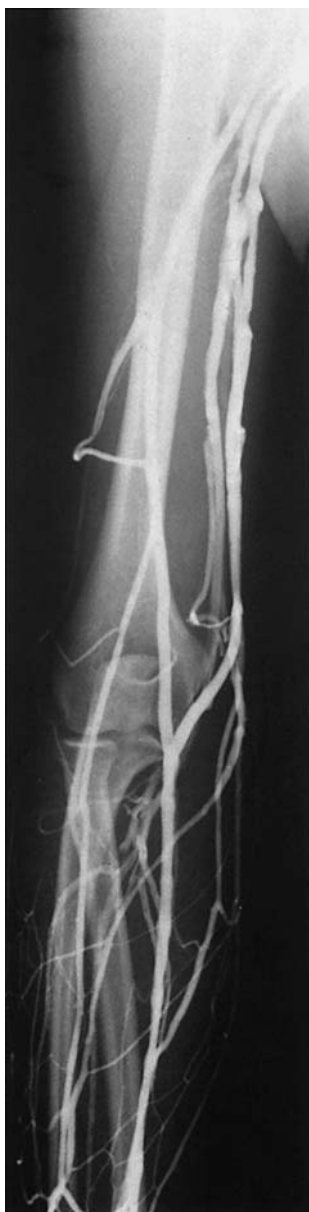5 External iliac vein

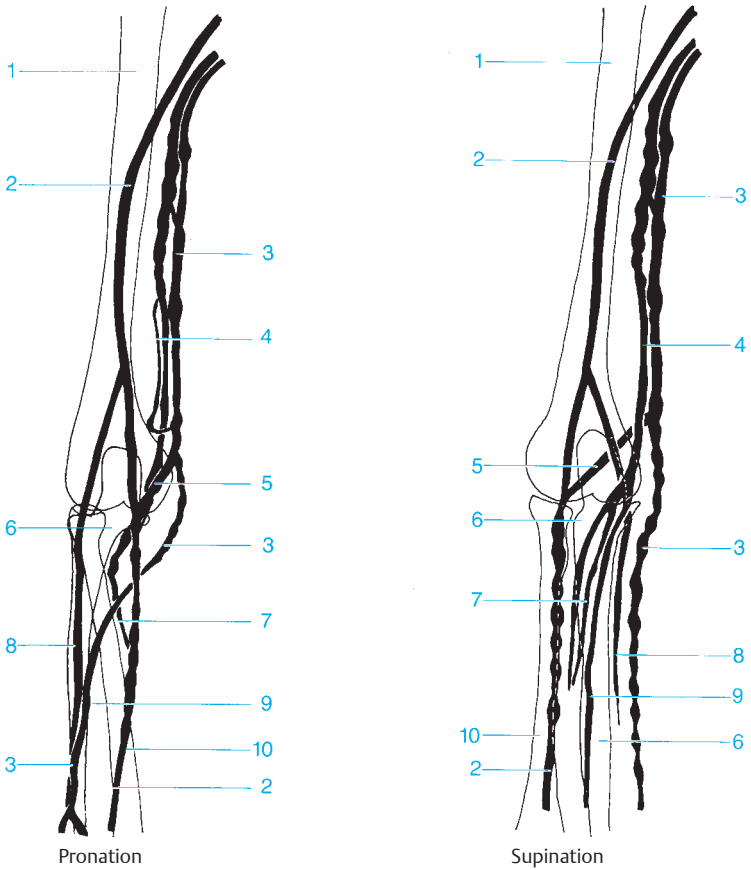




- 1 Subclavian vein
- 2 Superior vena cava
- 3 Axillary vein

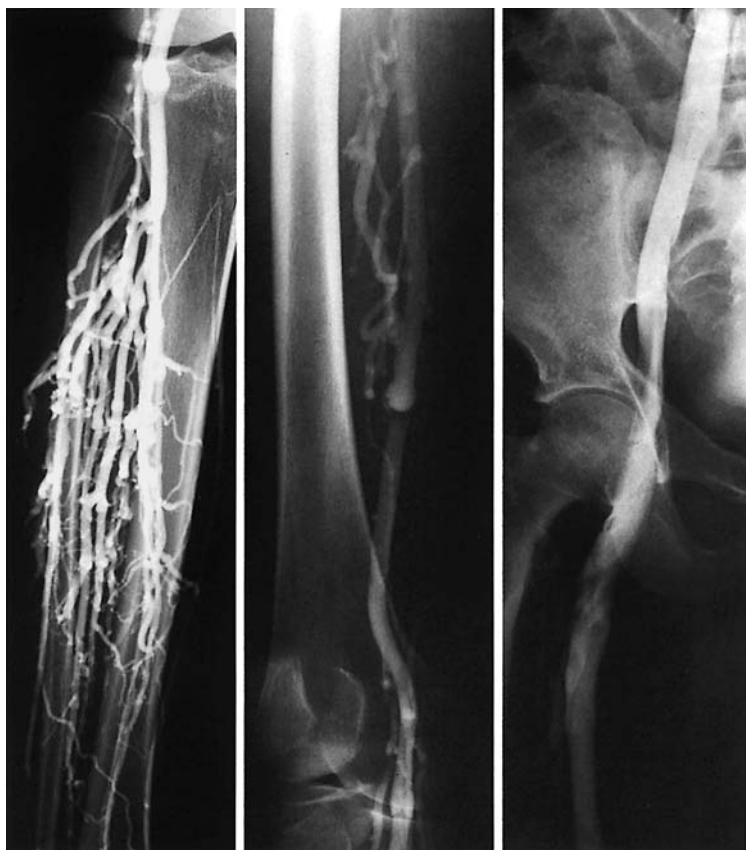- 4 Cephalic vein
- 5 Deep veins of the arm
- 6 Brachial veins

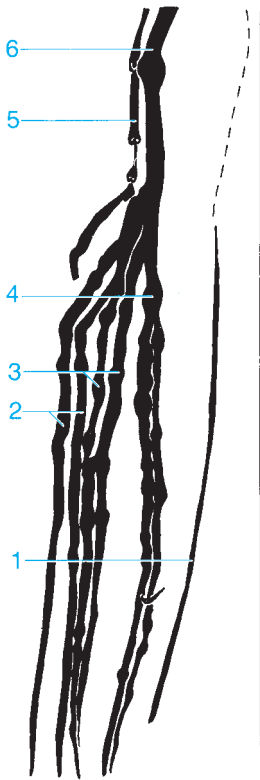




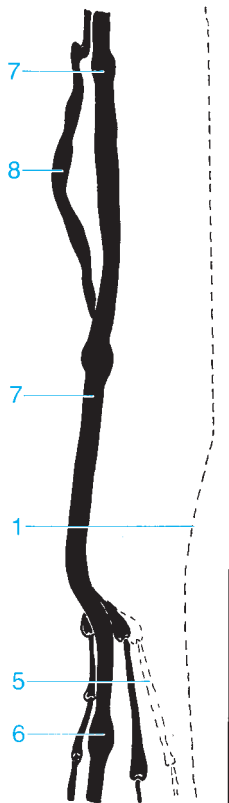
- 1 Humerus
- 2 Cephalic vein
- 3 Basilic vein
- 4 Brachial vein
- 5 Median cubital vein

- 6 Ulna
- 7 Radial veins
- 8 Ulnar veins
- 9 Median antebrachial vein
- 10 Radius

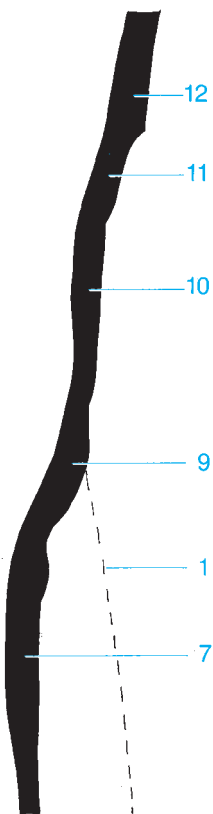




Internal rotation



External rotation

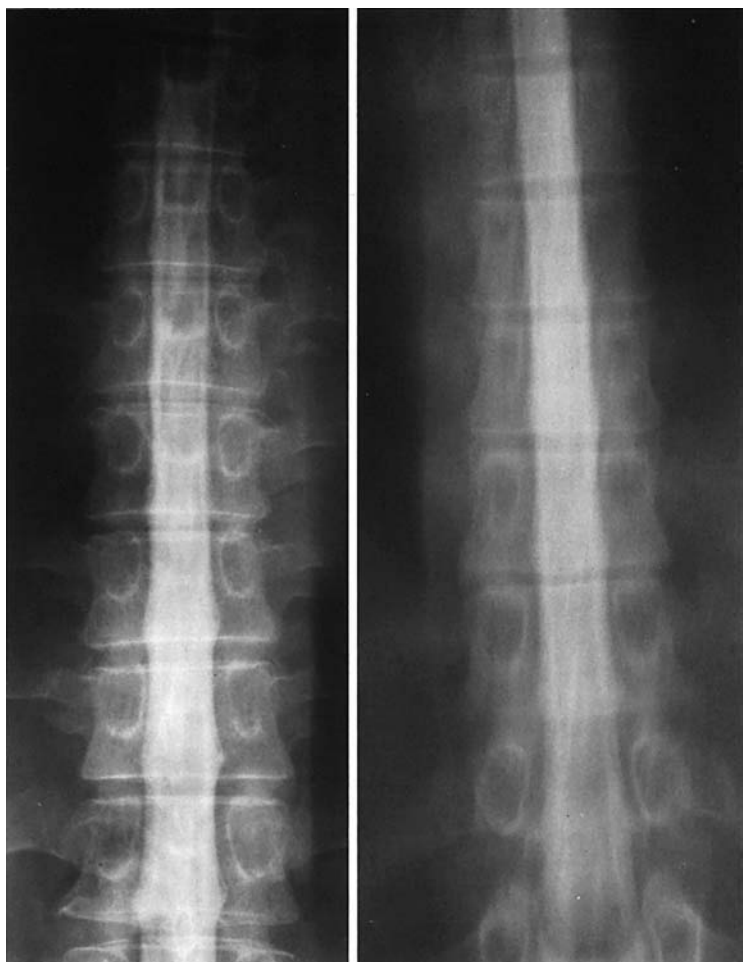


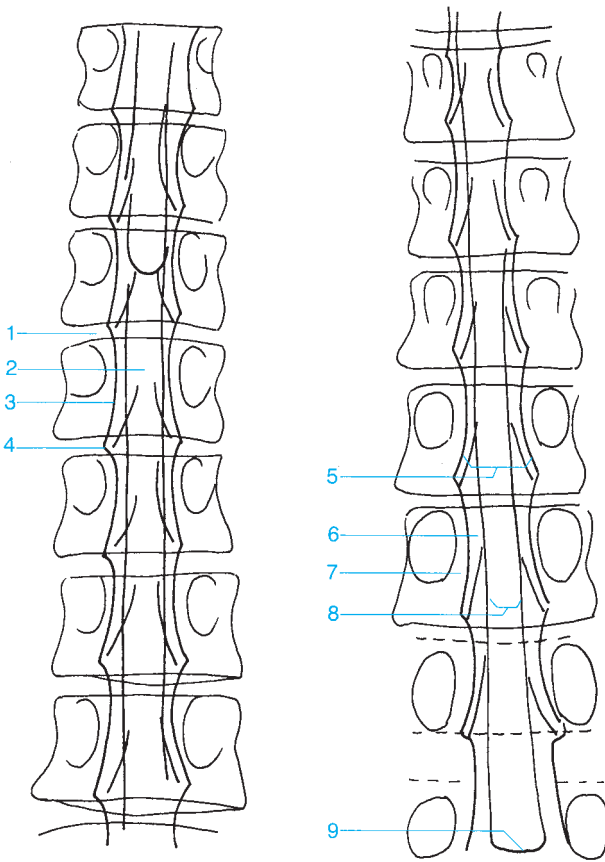
- 1 Great saphenous vein
- 2 Anterior tibial veins
- 3 Peroneal veins
- 4 Posterior tibial veins
- 5 Small saphenous vein
- 6 Popliteal vein

- 7 Superficial femoral vein
- 8 Deep femoral vein
- 9 Femoral vein
- 10 External iliac vein
- 11 Common iliac vein
- 12 Inferior vena cava

Special Studies

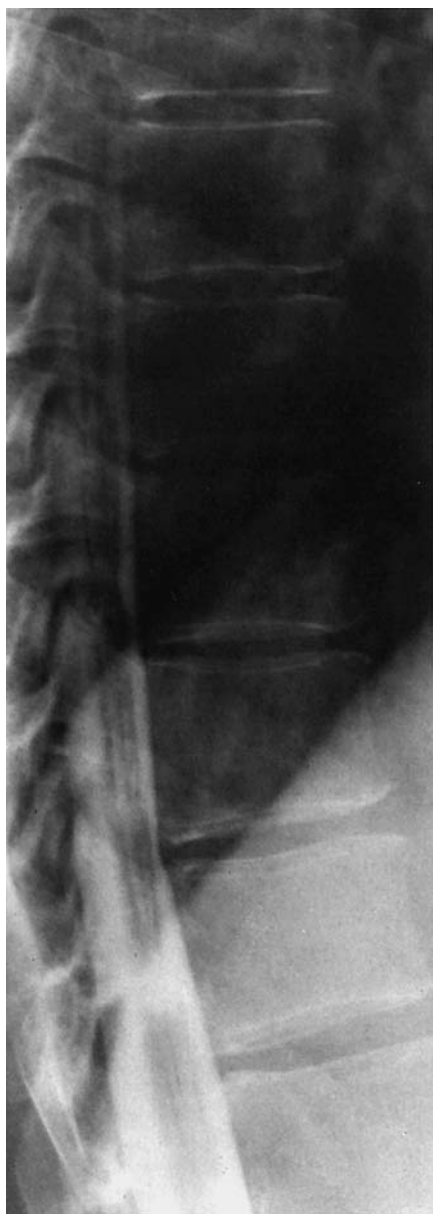Special Studies 340

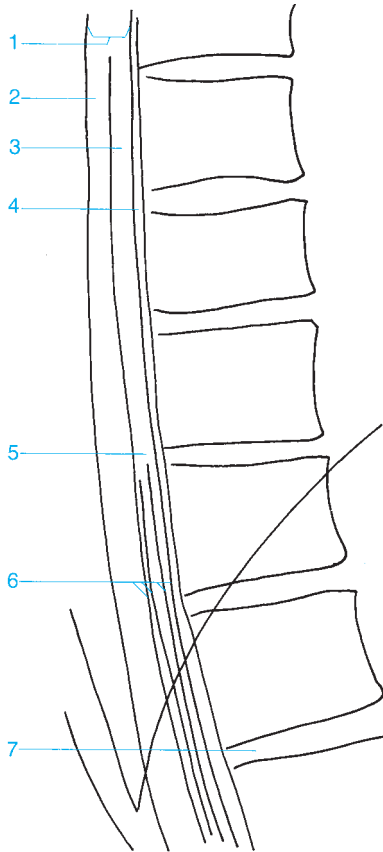




- 1 Intervertebral disk
- 2 Spinal cord
- 3 Lateral margin of the dural sac
- 4 Nerve root sheath
- 5 Intradural space

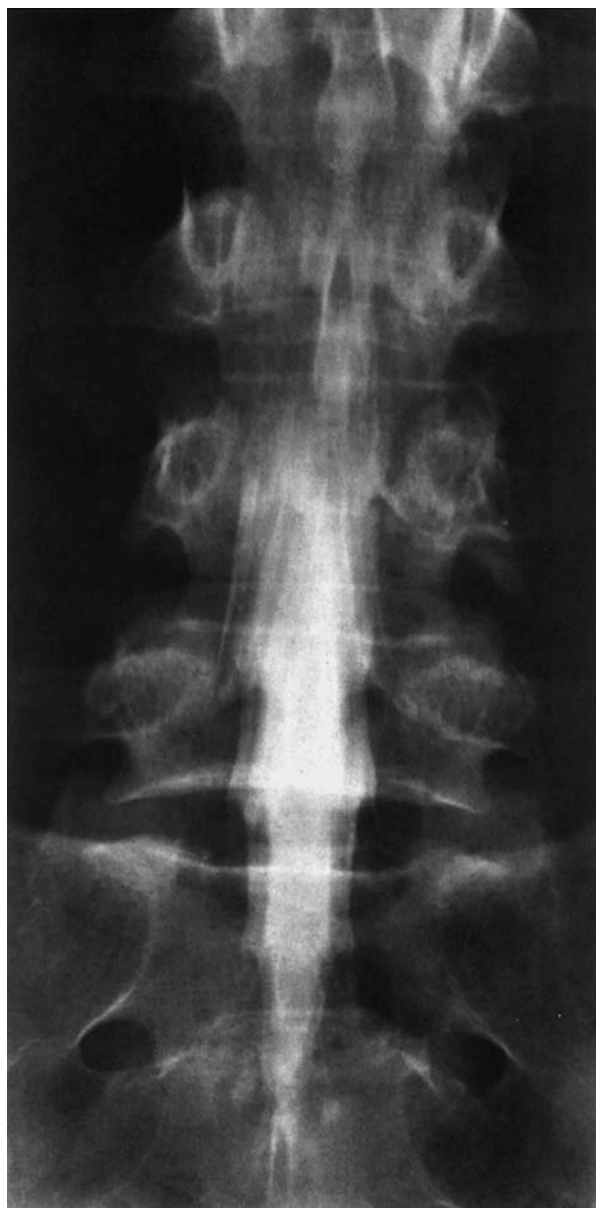- 6 Lateral subarachnoid space
- 7 Extradural space
- 8 Intramedullary region
- 9 Medullary cone

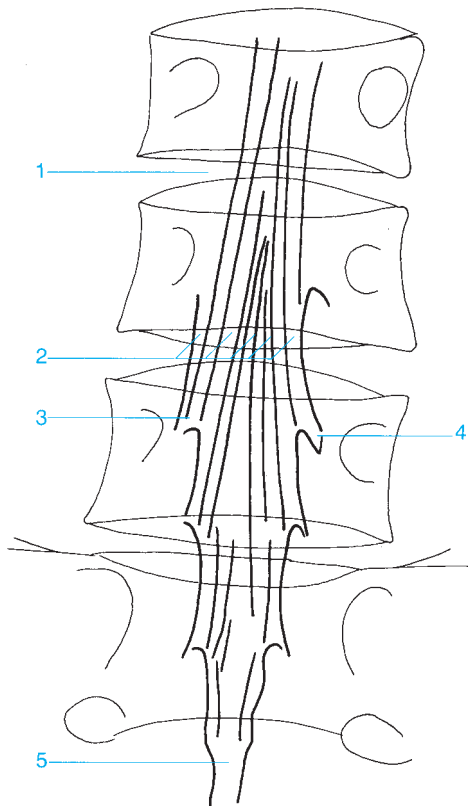




- 1 Dural sac
- 2 Posterior subarachnoid space
- 3 Spinal cord
- 4 Anterior subarachnoid space

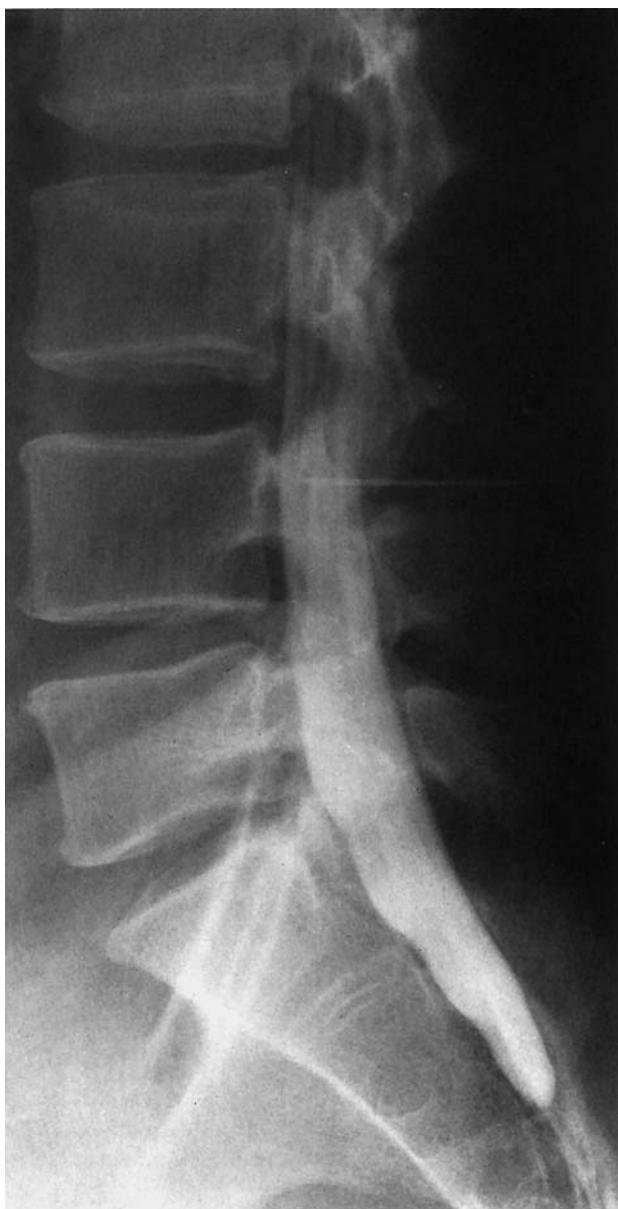- 5 Medullary cone
- 6 Cauda equina
- 7 Intervertebral disk

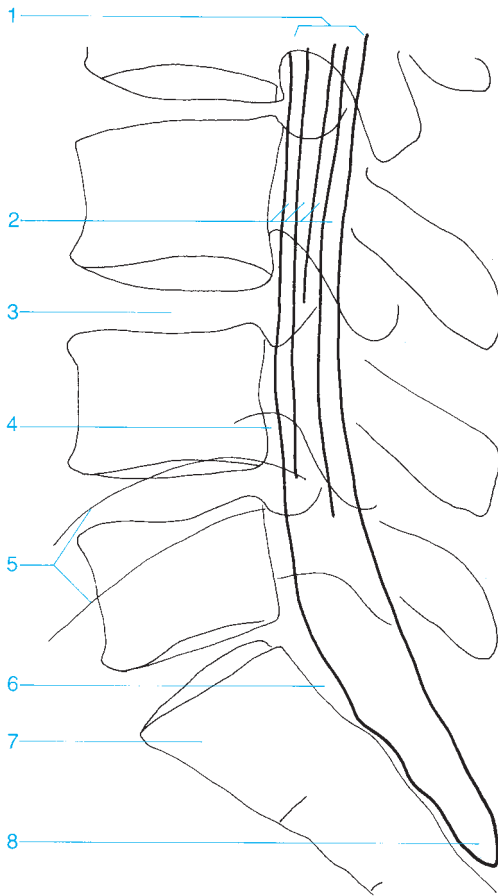




- 1 Intervertebral disk
- 2 Cauda equina
- 3 Spinal nerve root in the subarachnoid space

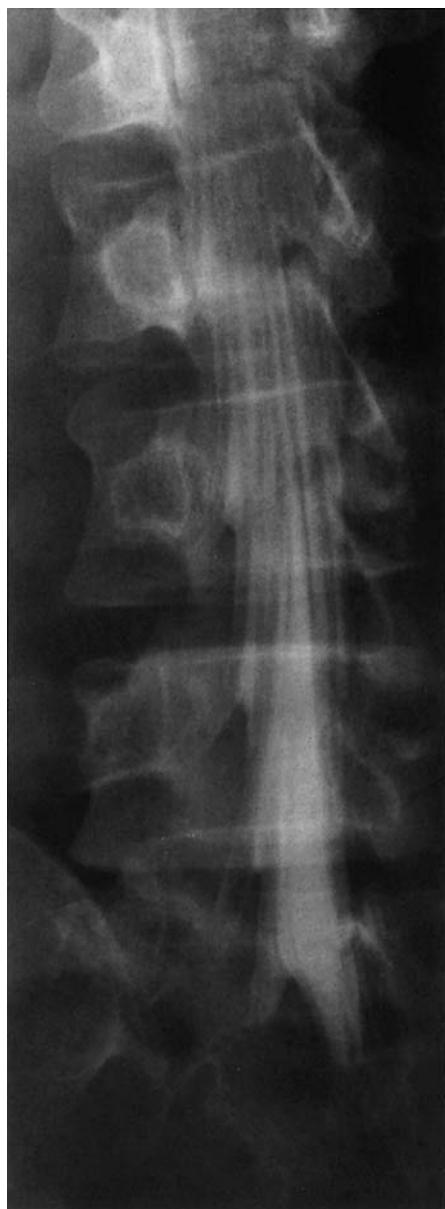- 4 Nerve root sheath
- 5 Distal end of the dural sac

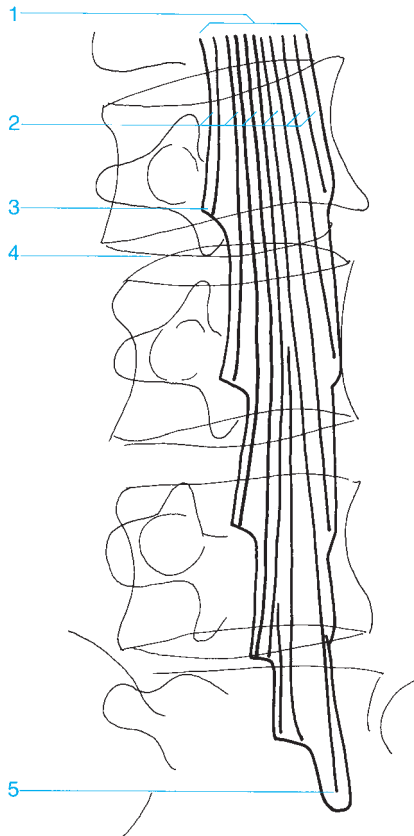




- 1 Dural sac
- 2 Cauda equina
- 3 Intervertebral disk
- 4 Intervertebral foramen

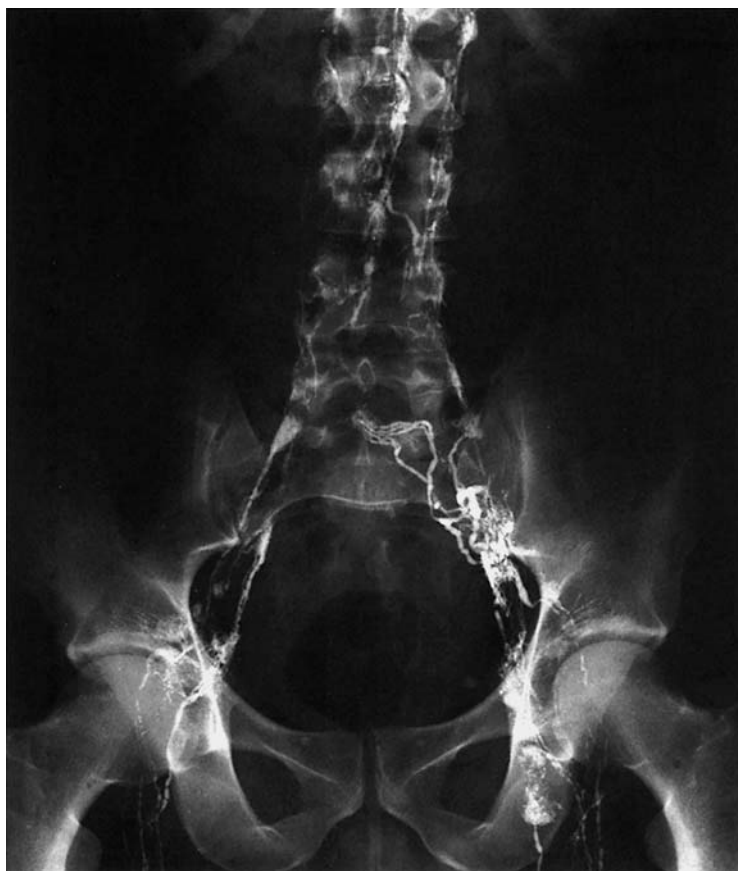- 5 Iliac crest
- 6 Epidural fat
- 7 Sacrum
- 8 Distal end of the dural sac

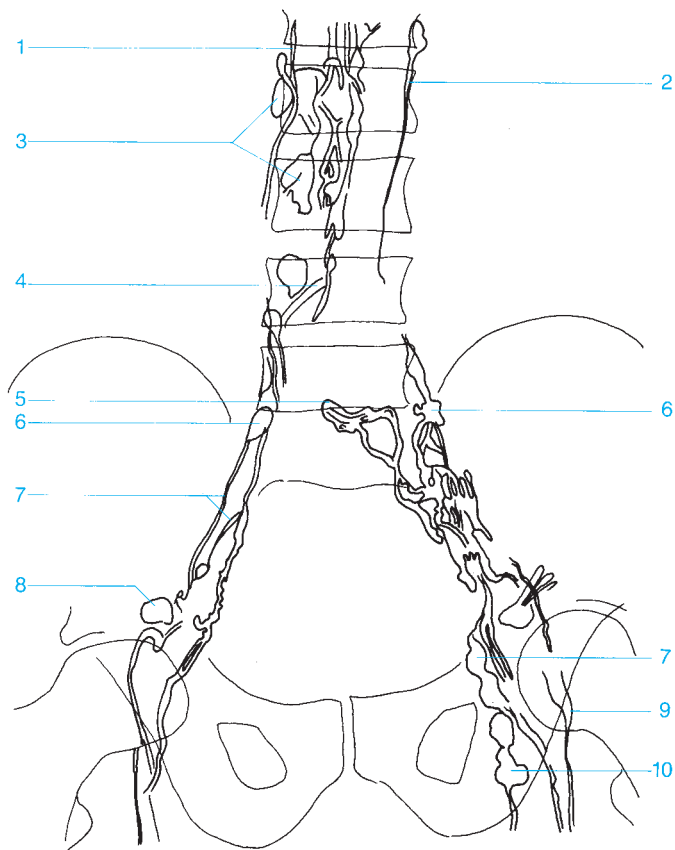




- 1 Dural sac
- 2 Cauda equina
- 3 Nerve root sheath, L3

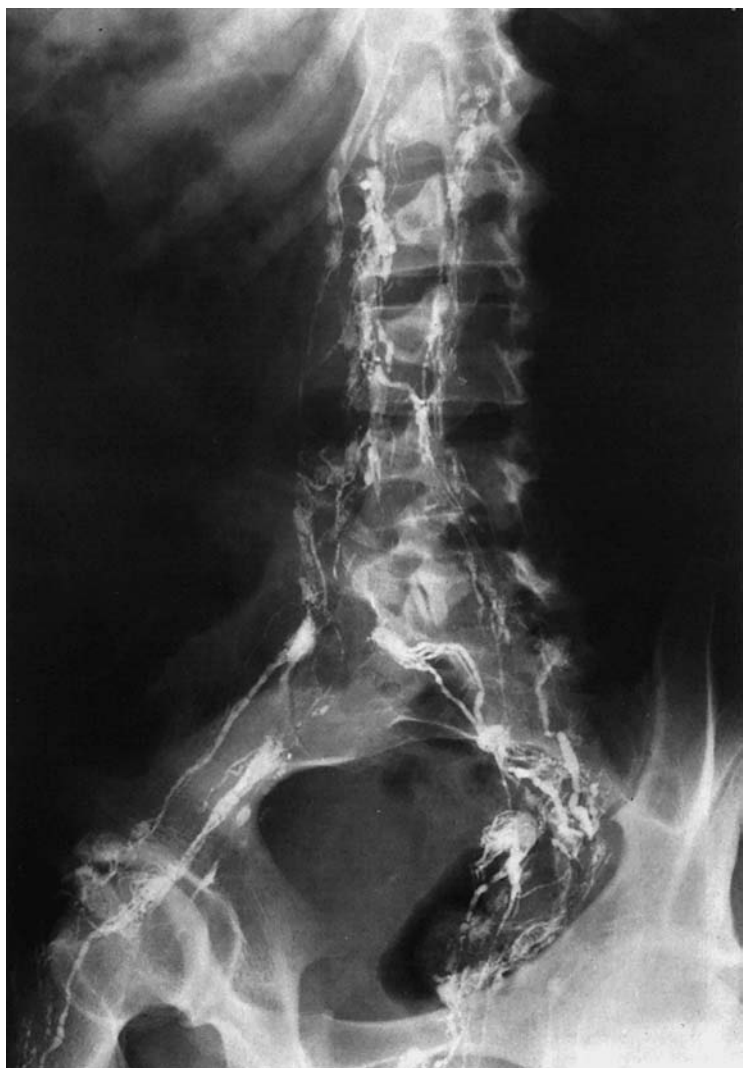- 4 Intervertebral disk L3-4
- 5 Distal end of the dural sac (usually at the level of S1 or S2)

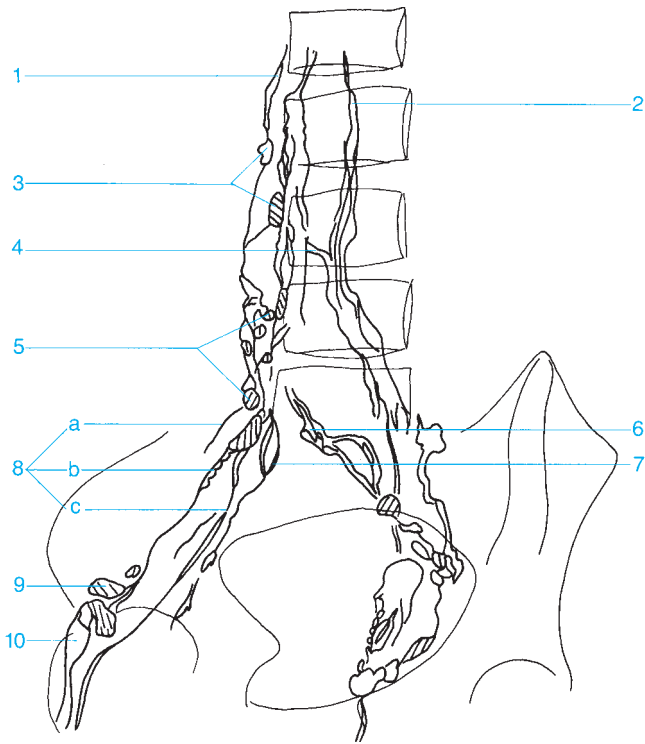




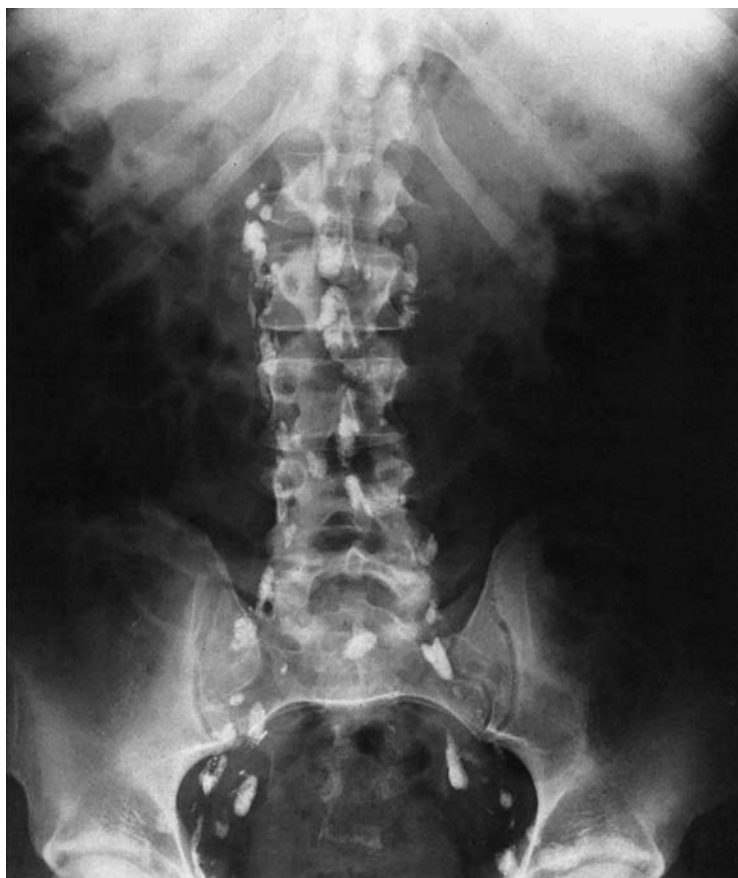- 1 Right lumbar trunk
- 2 Left lumbar trunk
- 3 Lumbar lymph nodes
- 4 Crossover
- 5 Promontory lymph nodes
- 6 Common iliac lymph nodes

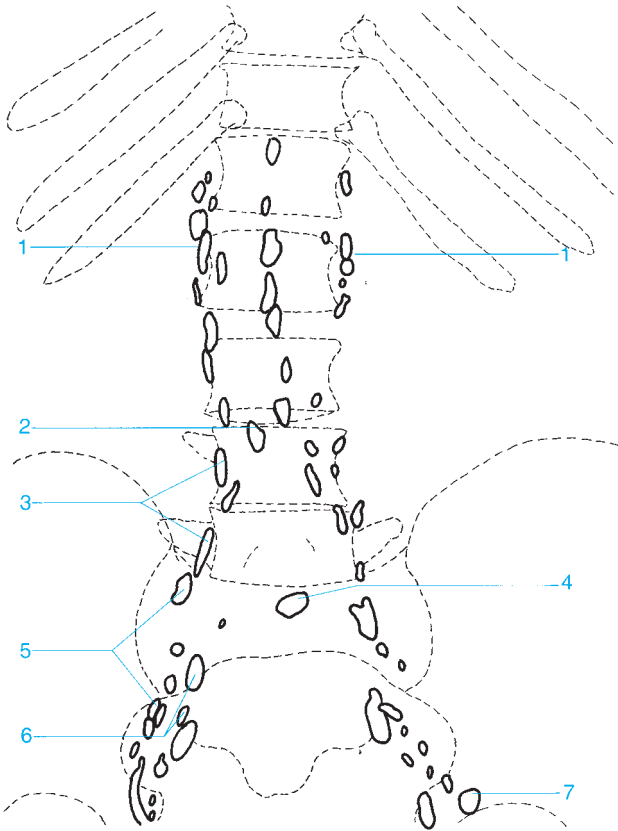
- 7 Lymph channels of the external iliac lymph nodes
- 8 Lateral lacunar lymph nodes
- 9 Superficial inguinal lymph nodes
- 10 Deep inguinal lymph nodes





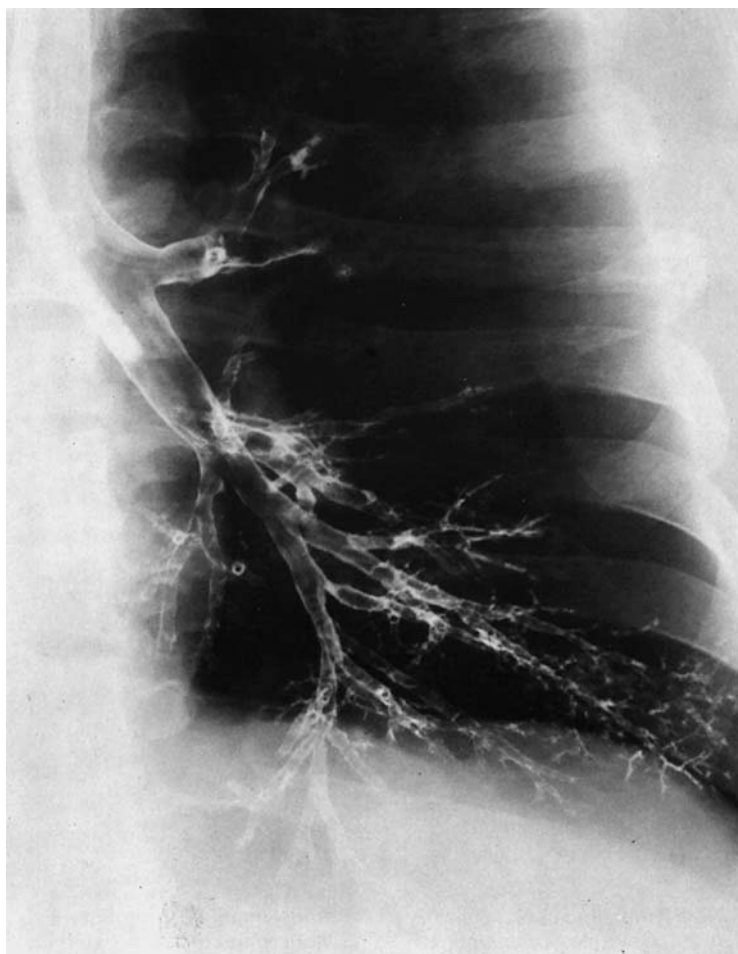- | | |
|---|--|
| <p>1 Right lumbar trunk</p> <p>2 Left lumbar trunk</p> <p>3 Lumbar lymph nodes</p> <p>4 Crossover</p> <p>5 Common iliac lymph nodes</p> <p>6 Promontory lymph nodes</p> <p>7 Lymph channels connecting the internal iliac lymph nodes with the external and common iliac lymph nodes</p> | <p>8 External and common iliac lymph nodes</p> <p style="padding-left: 20px;">a External chain</p> <p style="padding-left: 20px;">b Middle chain</p> <p style="padding-left: 20px;">c Internal chain</p> <p>9 Lacunar lymph node</p> <p>10 Superficial inguinal lymph nodes</p> |
|---|--|

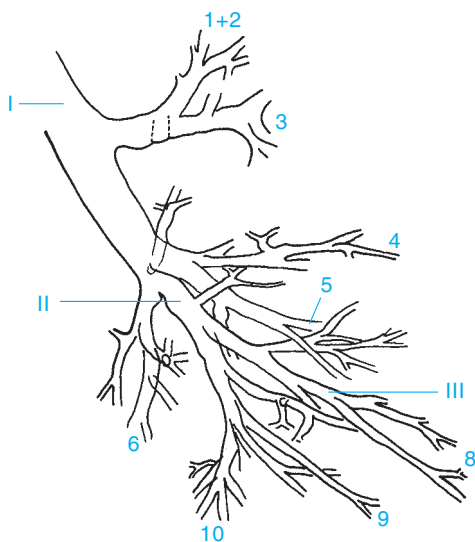




- 1 Para-aortic lymph nodes (lateral aortic, preaortic, and retroaortic)
- 2 Crossover
- 3 Common iliac lymph nodes

- 4 Promontory lymph nodes
- 5 External iliac lymph nodes
- 6 Internal iliac lymph nodes
- 7 Lacunar lymph node





1 + 2 Apical-posterior segment of the upper lobe

3 Anterior segment of the upper lobe

4 Lingula of the superior segment of the upper lobe

5 Lingula of the inferior segment of the upper lobe

6 Superior segment of the lower lobe

7 Not present on left side

8 Anterior-medial basal segment of the lower lobe

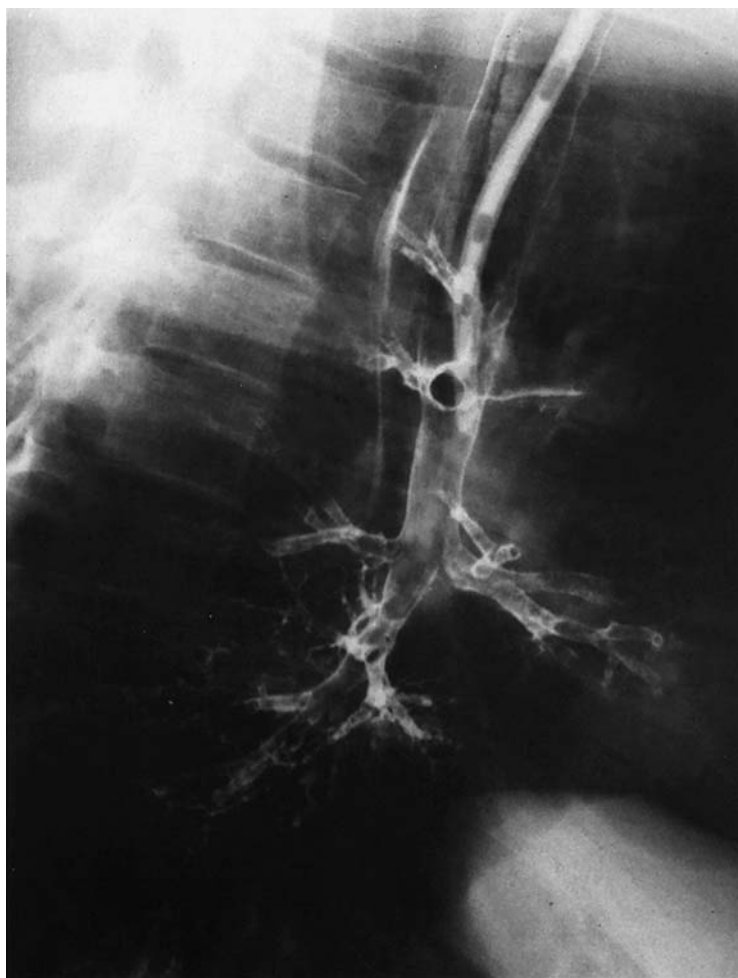9 Lateral basal segment of the lower lobe

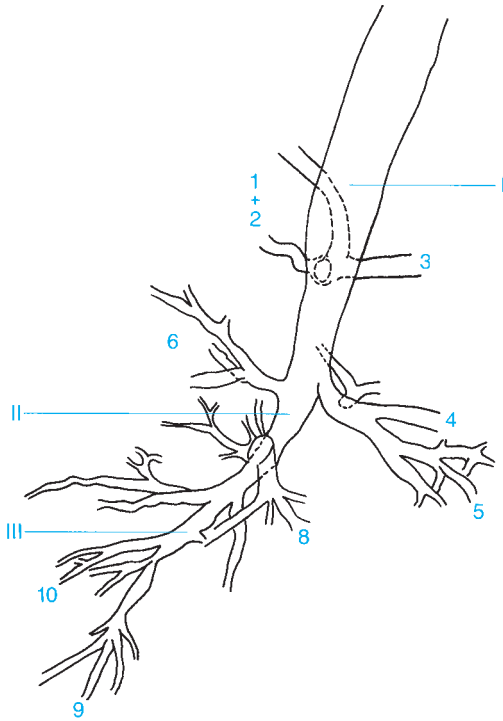
10 Posterior basal segment of the lower lobe

I Main bronchus

II Lobar bronchus

III Segmental bronchus





1 + 2 Apical-posterior segment of the upper lobe

3 Anterior segment of the upper lobe

4 Lingula of the superior segment of the upper lobe

5 Lingula of the inferior segment of the upper lobe

6 Superior segment of the lower lobe

7 Not present on left side

8 Anterior-medial basal segment of the lower lobe

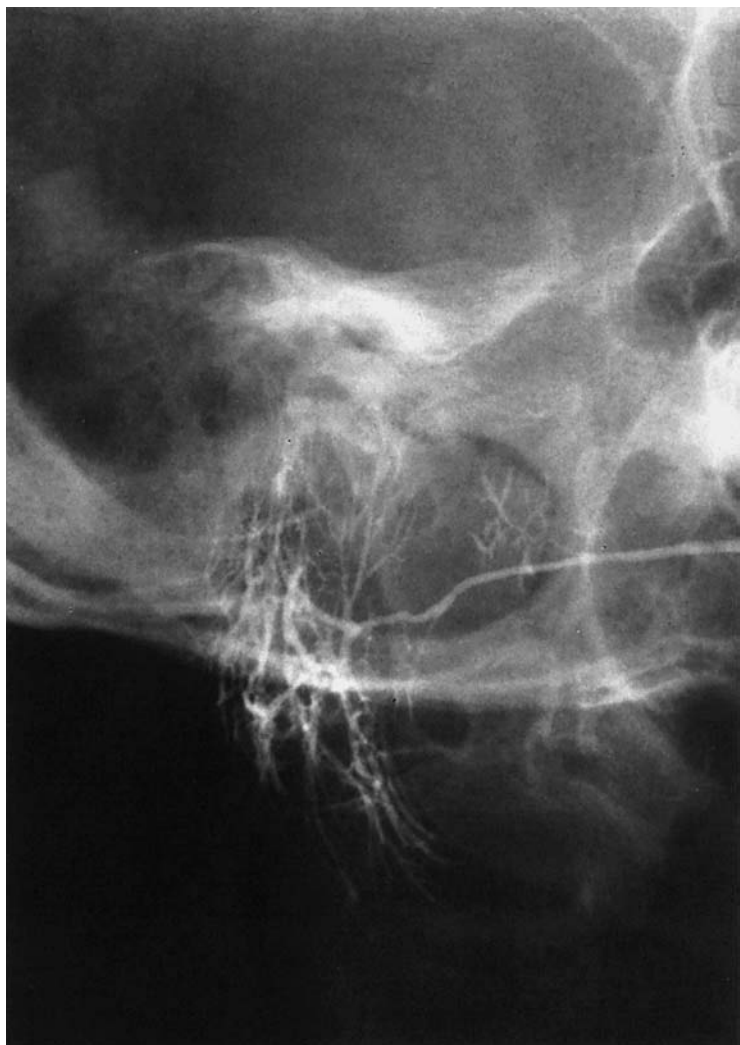
9 Lateral basal segment of the lower lobe

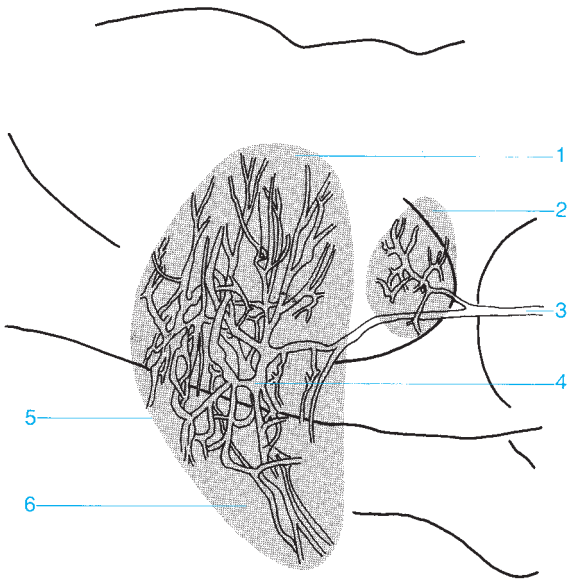
10 Posterior basal segment of the lower lobe

I Main bronchus

II Lobar bronchus

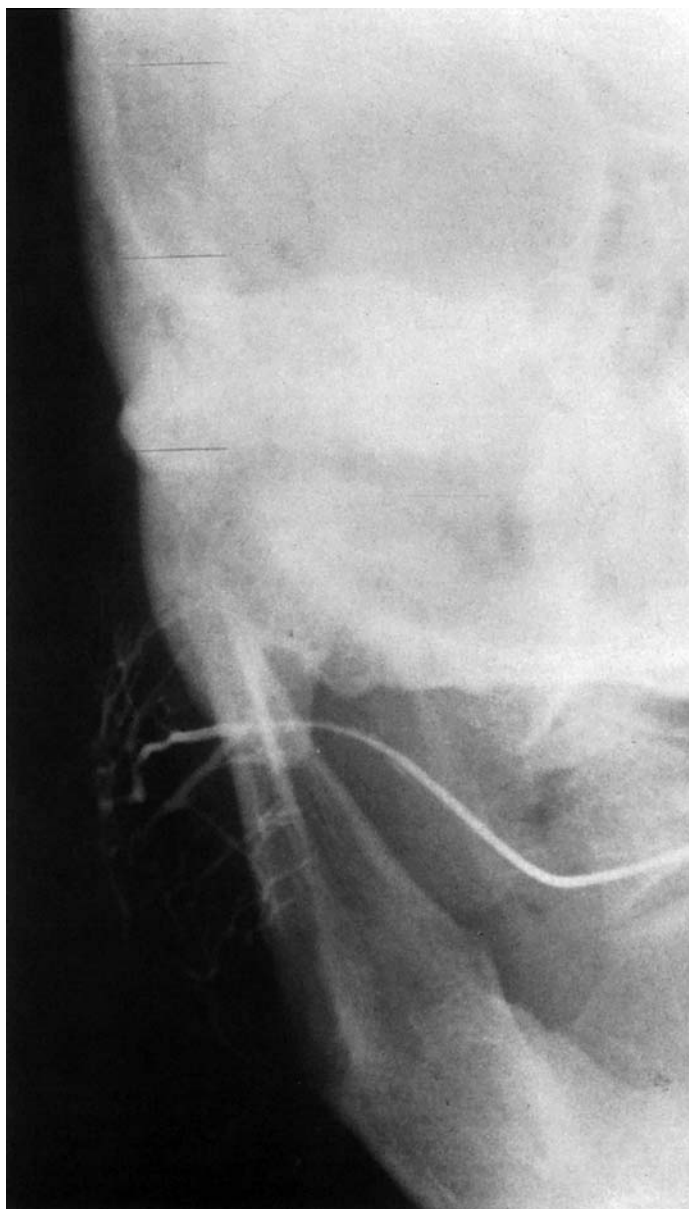III Segmental bronchus

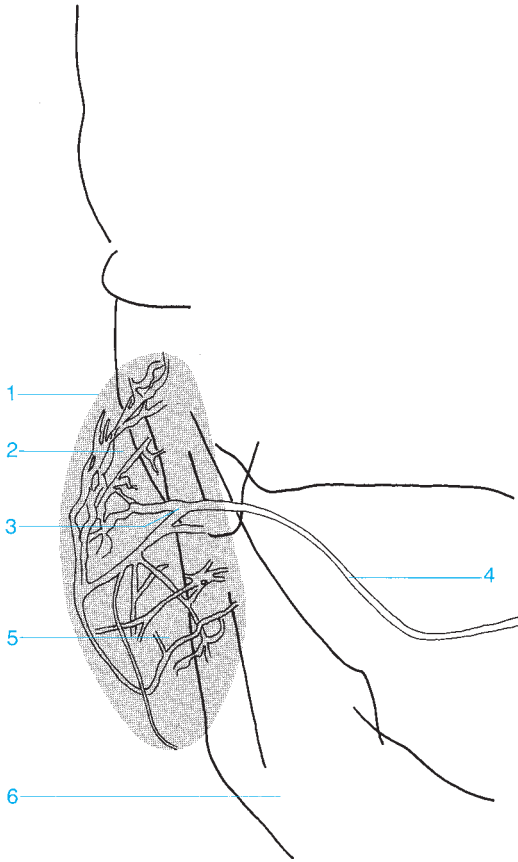




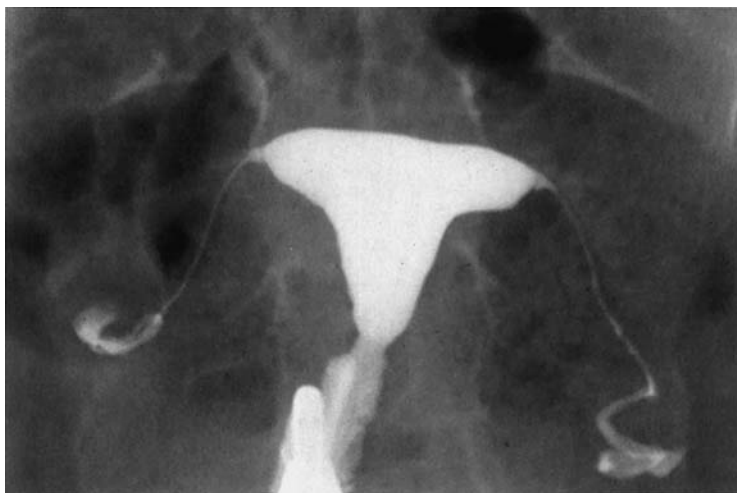- 1 Superficial lobe of the parotid gland
- 2 Accessory parotid gland
- 3 Parotid duct (Stensen's duct)

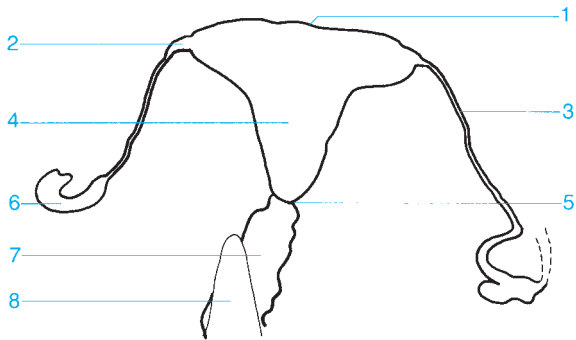- 4 Intralobular ductal system
- 5 Parotid gland
- 6 Deep lobe of the parotid gland (beneath the facial nerve)



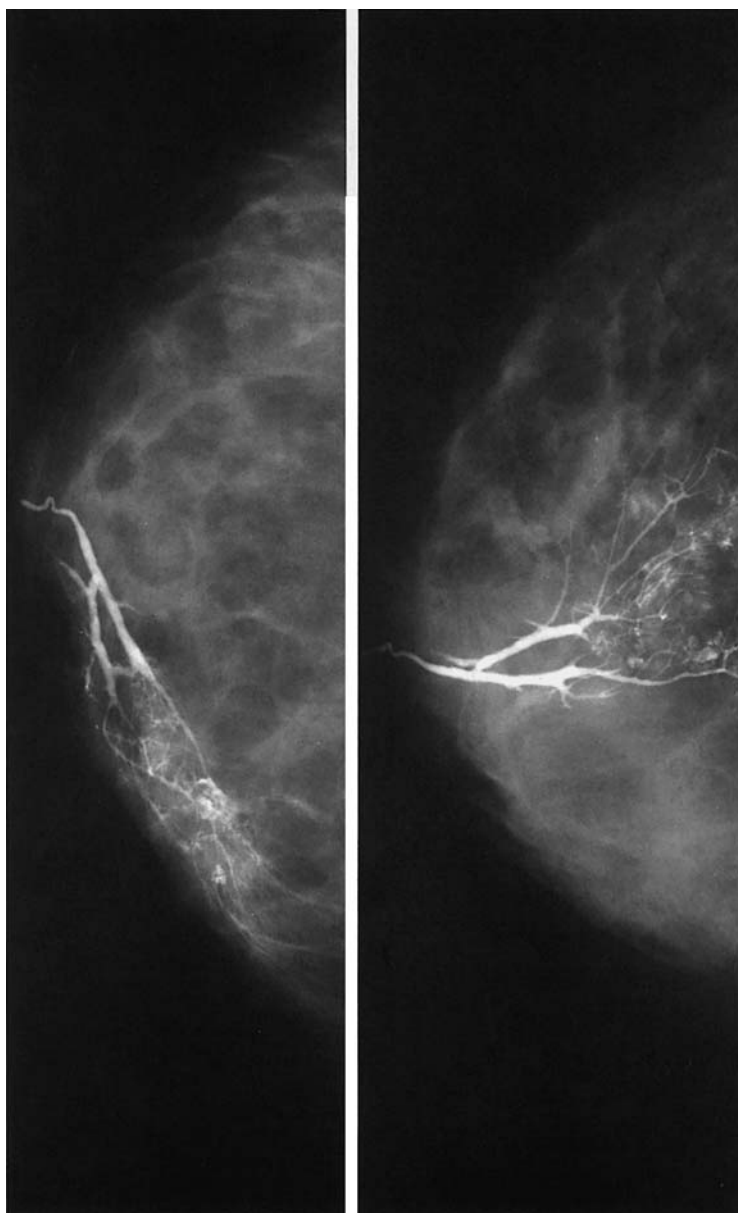


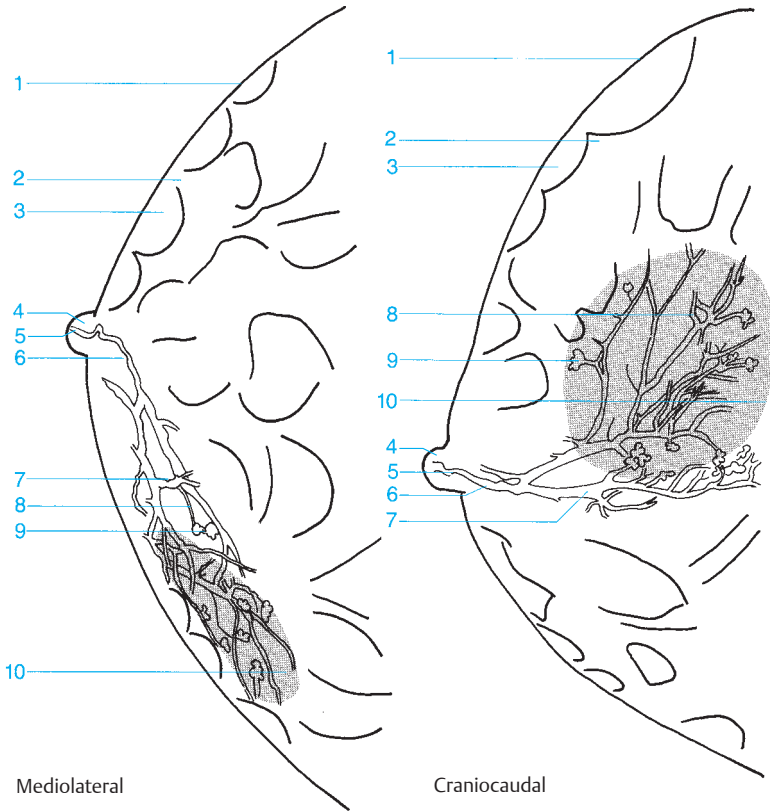
- | | |
|---|---|
| 1 Parotid gland | 4 Parotid duct (Stensen's duct) |
| 2 Superficial lobe of the parotid gland (on the facial nerve) | 5 Deep lobe of the parotid gland (beneath the facial nerve) |
| 3 Intralobular parotid ductal system | 6 Mandible |





- | | |
|--|----------------------------------|
| 1 Fundus of the uterus | 5 Cervical canal |
| 2 Uterine ostium of the fallopian tube | 6 Fimbriae of the fallopian tube |
| 3 Fallopian tube | 7 Vagina |
| 4 Uterine cavity | 8 Instrument |





1 Skin and subcutaneous tissue

2 Cooper's ligament

3 Subcutaneous fatty tissue

4 Nipple

5 Main lactiferous duct posterior to the nipple

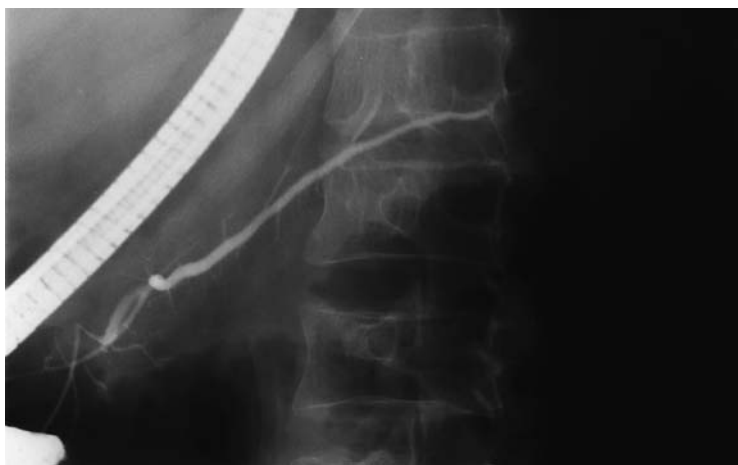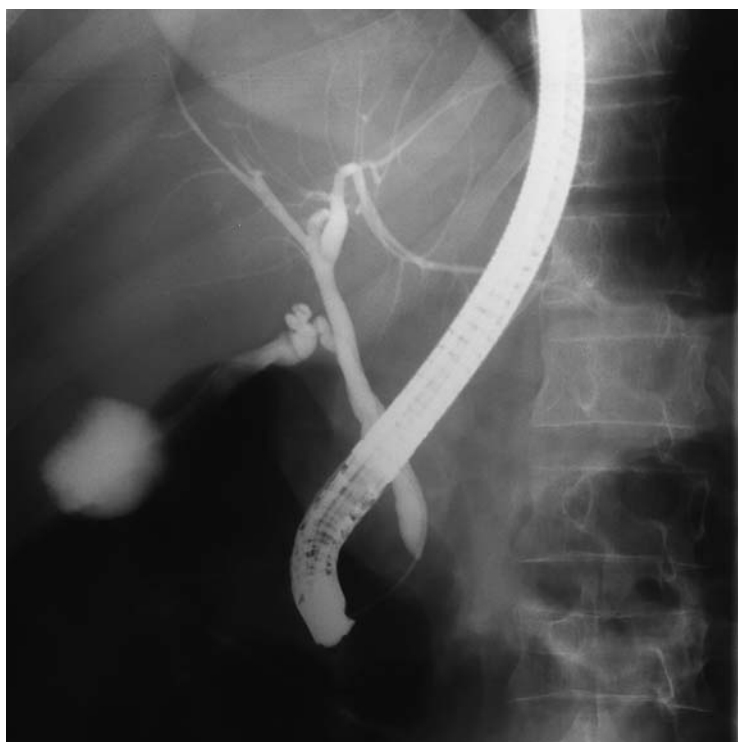6 Lactiferous sinus

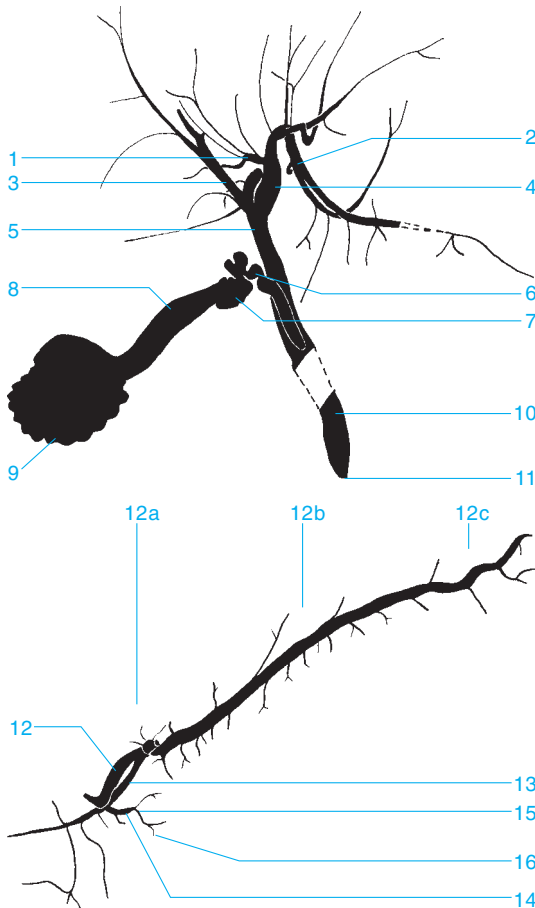
7 Lactiferous duct

8 Ductules

9 Lobules

10 Lobe





- 1 Medial branch of the left hepatic duct
- 2 Lateral branch
- 3 Right hepatic duct
- 4 Left hepatic duct
- 5 Common hepatic duct
- 6 Cystic duct
- 7 Neck of the gallbladder
- 8 Body of the gallbladder
- 9 Fundus of the gallbladder

- 10 Common bile duct
- 11 Papilla of Vater
- 12 Pancreatic duct
 - a Head region
 - b Body region
 - c Tail region
- 13 Accessory pancreatic duct
- 14 Primary lateral duct
- 15 Secondary lateral duct
- 16 Tertiary lateral duct

A

- abdomen, radiograph
standing 220–221
supine 222–223
- abdominal aorta 313
- abdominal fat, subcutaneous 223
- abdominal muscles 223
- accessory bones, foot 187
- accessory pancreatic duct 369
- accessory parotid gland 361
- acetabulum
angle of inclination 63
convexity 61, 63, 149
floor 69, 71, 149, 151, 155
promontory 61, 63, 149
rim 61
anterior 69, 71, 149, 151, 153, 155, 157
posterior 69, 71, 149, 151, 153, 157
superior 151, 153
roof 69, 71, 73, 149, 153, 155
child 63
teardrop 61
- Achilles tendon 181, 191
- acromioclavicular joint 92–95, 101, 107, 109, 111
anterior-posterior 91, 97, 103, 105
lateral 99, 115
stress view 89
- acromion 83, 93, 95, 101, 107, 109, 111, 275
anterior-posterior 91, 97, 103, 105, 113, 273
lateral 115
stress view 89
- adrenal artery, inferior 313
- air cells
marginal 33
mastoid 7, 29, 31, 33
periantral 33, 37
retrofacial 33
retrosinus 37
squamous 33
- ampulla of Vater 249, 251, 253
- anal canal 263
- anastomotic vein
inferior 287
superior 285, 287
- angiography
ankle 324–325
aorta, pelvic 316–317
aortic arch 298–299
celiac trunk
arterial phase 304–305
venous phase 306–307
cervical vessels 296–297
foot 324–325
knee 320–321
leg, lower 322–323
thigh 318–319
- angle
of Citelli 33
costophrenic 209, 221
gastroesophageal 247
of inclination (acetabulum) 63
of mandible 3, 17, 19, 21, 23
of scapula
inferior 83
superior 89, 91, 97, 99, 101, 103, 105, 107
venous 327
Wilberg's center-to-corner 63
- angular gyrus, artery of 281, 282
- ankle 147, 178–185, 189
angiogram 324–325
arthrogram 278–279
recesses
anterior/posterior 279
supracalcaneal 279
tendon 279
- ankle joint space 183, 185, 195, 279
- anorectal junction 261
- antebrachial vein, median 335
- anterior arch, of atlas 47, 49
- antrum
mastoid 31, 33, 35, 37
pyloric 249, 251, 253
- aorta
abdominal 313
ascending 213, 217, 219, 299
descending 209, 213, 217, 219, 233, 299
pelvic angiogram 316–317
- aortic arch 211, 213, 217, 219, 233, 245
angiogram 298–299
- aortic bulb 299
- aortic valve 211, 213
- aortopulmonary window 213
- appendix 255, 259
- arcuate arteries 313
- arcuate eminence 7, 31, 35
- arcuate line 73
- arcuate vein 315
- arm
deep veins of 333
upper
anterior-posterior view 112–113
lateral view 114–115
see also elbow; forearm; shoulder; wrist
- arteries
adrenal, inferior 313
of angular gyrus 281, 282
arcuate 313
basilar 289, 291
callosomarginal 281, 283
- carotid
anterior-posterior arteriogram
arterial phase 280–281
venous phase 284–285
common 297, 299
external 297
internal 280–285, 297
lateral arteriogram
arterial phase 282–283
venous phase 286–287
- cerebellar
inferior anterior 289, 291
inferior posterior 289, 291
superior 289, 291
vermis branch 289
- cerebral

- anterior 281
 - second segment 281, 283
 - third segment 281
- corpus callosal branch 291
- middle
 - first segment 281
 - second segment 281, 283
- posterior 289, 291
- thalamic branches 291
- cervical, ascending 297
- choroidal
 - anterior 281, 283
 - lateral/medial/posterior 291
- colic, middle/right 309
- communicating (of cerebrum)
 - anterior 281
 - posterior 283, 291
- cystic 305
- dorsalis pedis 325
- facial 297
- femoral
 - deep 319
 - lateral circumflex 319
 - ascending/descending branches 319
 - medial circumflex 319
 - superficial 319, 321
- fibular, circumflex 323
- frontal, internal, anterior/medial/posterior 282
- gastric, left/right 305
- gastroduodenal 305
- gastroepiploic, right 305
- genicular
 - descending 321
 - inferior medial 321
 - middle 321
 - superior lateral 321
 - superior medial 321
- gluteal, inferior/superior 317
- hepatic
 - common 305
 - proper, left/right branches 305
- ileal 309
- ileocolic 309
- interlobular 313
- jejunal 309
- marginal 289
- meningeal, middle, groove of 5
- mesenteric, superior 305, 309
- arteriography
 - arterial phase 308–309
 - venous phase 310–311
- occipital, medial, calcarine branch 289, 291
- ophthalmic 281, 283
- orbital, frontal 281, 283
- pancreaticoduodenal
 - inferior 305, 309
 - superior 305
- paracentral 282
- parietal
 - anterior/posterior 281, 282
 - internal, inferior/superior 282
- parieto-occipital 289, 291
- perforating 319
- pericallosal 281, 282
- peroneal 321, 323
- plantar 325
- polar
 - frontal 281, 282
 - temporal 281
- popliteal 321
- prefrontal 281, 283
- pulmonary
 - apical branch 301, 303
 - apicoposterior branch 303
 - arteriography
 - arterial phase 300–301
 - venous phase 302–303
 - left 211, 217, 219, 301, 327
 - lingular branch 301
 - lobar branch
 - inferior 211, 233, 235, 301
 - inferior right 217
 - middle 235, 301
 - superior 235
 - main 211, 213, 217
 - right 211, 219, 233, 235, 301, 327
 - intermediate part 211
 - trunk 301
- renal
 - arteriogram
 - arterial phase 312–313
 - venous phase 314–315
 - left/right 313
- segmental 301, 303
 - anterior/posterior 313
 - inferior/superior 313
 - middle 313
- splenic 305, 313
- subclavian 211, 297, 299
- sulcus, precentral 281
- supraduodenal, superior 305
- suprascapular 297
- temporal, posterior 281, 282
- temporo-occipital 289, 291
- thalamoperforate 289
- thoracic, internal 297
- thyroid, inferior/superior 297
- tibial
 - anterior 321, 323, 325
 - muscular branch 323
 - posterior 321, 323, 325
- vertebral 289, 291, 297, 299
 - anterior-posterior
 - arteriogram
 - arterial phase 288–289
 - venous phase 292–293
 - lateral arteriogram
 - arterial phase 290–291
 - venous phase 294–295
 - see also* aorta
 - arteriography
 - carotid artery, internal
 - anterior-posterior
 - arterial phase 280–281

- venous phase 284–285
 - lateral
 - arterial phase 282–283
 - venous phase 286–287
 - mesenteric artery, superior
 - arterial phase 308–309
 - venous phase 310–311
 - pulmonary artery
 - arterial phase 300–301
 - venous phase 302–303
 - renal artery
 - arterial phase 312–313
 - venous phase 314–315
 - vertebral artery
 - anterior-posterior
 - arterial phase 288–289
 - venous phase 292–293
 - lateral
 - arterial phase 290–291
 - venous phase 294–295
 - arthrography
 - ankle 278–279
 - knee 276–277
 - shoulder
 - anterior-posterior 272–273
 - oblique 274–275
 - wrist
 - lateral 270–271
 - posterior-anterior 268–269
 - articular facet, inferior/superior 47
 - articular pillar 47
 - articular processes
 - cervical
 - inferior/superior 49
 - overlapping 45
 - lumbar, inferior/superior 55, 57, 59
 - sacral
 - inferior 75, 237
 - superior 75
 - thoracic, inferior/superior 51, 53
 - articular tubercle 33
 - arytenoid cartilages 229
 - ascending aorta 213, 217, 219, 299
 - atlantoaxial joint 11, 45
 - atlas 49
 - anterior arch 47, 49
 - posterior arch 7, 47
 - atrium
 - left 211, 213, 303
 - right 211, 217, 219, 301, 303, 327
 - auditory canal
 - external 33, 37
 - external opening 5
 - internal 3, 7, 11, 29, 31, 33, 35
 - auditory vestibule 31, 35
 - axilla, venogram 332–333
 - axillary recess 273, 275
 - axillary vein 333
 - axis 243
 - body of 47
 - dens of 3, 29, 43, 45, 231
 - azygoesophageal stripe 209
 - azygos vein 211, 233, 327
- B**
- basal vein
 - common/inferior 303
 - of Rosenthal 285, 287, 295
 - basilar artery 289, 291
 - basilic vein 335
 - biceps muscle, tendon
 - sheath of long head 273, 275
 - biceps tendon, insertion of 275
 - bicipital groove 93, 95, 103, 107, 109, 111, 113
 - bile duct, common 267, 369
 - bipedal lymphangiogram
 - anterior-posterior
 - channel phase 350–351
 - nodal phase 354–355
 - oblique, channel phase 352–353
 - brachial veins 333, 335
 - brachiocephalic trunk 297, 299
 - brachiocephalic vein 211
 - left/right 327
 - breast
 - ductules 367
 - galactogram 366–367
 - lobe 367
 - lobules 367
 - contour 225, 227
 - shadow 209
 - skin 225, 227, 367
 - subcutaneous fat 225, 227, 367
 - subcutaneous tissue 367
 - veins 225, 227
 - bronchogram, left
 - anterior-posterior 356–357
 - lateral 358–359
 - bronchus 217
 - intermediate 209, 233, 235
 - lobar 357, 359
 - lower lobe 213, 235
 - left/right 233
 - segmental 235
 - main 357, 359
 - left 209, 219, 233
 - right 219, 233
 - middle lobe 233, 235
 - right main 209
 - segmental 357, 359
 - upper lobe
 - left/right 213, 233
 - origin of 235
- C**
- calcaneocuboid joint 189, 201
 - calcaneus bone
 - anterior-posterior 187, 197
 - arthrogram 279
 - lateral 177, 181, 189, 190–191
 - oblique 183, 185, 199
 - peroneal trochlea 193
 - posterior tuberosity 181, 189, 191, 193
 - lateral/medial processes 193
 - standing position 195
 - sustentaculum tali 191, 193
 - tangential view 192–193

- callosomarginal artery 281, 283
- canine teeth 21, 23
- capitate bone 137, 139, 141
anterior-posterior 129, 133
lateral 135
oblique 131, 143
- capitellum, humerus 115, 117, 121, 123, 125
- capsular recesses, inferior/superior 277
- cardia 247
- carotid arteries
common 297, 299
external 297
internal 280–287, 297
anterior-posterior arteriogram
arterial phase 280–281
venous phase 284–285
lateral arteriogram
arterial phase 282–283
venous phase 286–287
- carpal bones 125, 127
proximal row 125, 127
- carpal tunnel 136–137
- carpometacarpal joint 133, 143
- cartilages
arytenoid 229
knee 277
nasal 25
thyroid 229, 231
triangular fibrocartilage, wrist 269
triradiate line 63
- cauda equina 343, 345, 347, 349
- cavernous sinus 295
anterior/posterior drainage 287
- cecum 255, 257, 259
- celiac trunk 305
angiogram
arterial phase 304–305
venous phase 306–307
- cephalic vein 327, 333, 335
- cerebellar artery
inferior, anterior/posterior 289, 291
superior 289, 291
vermis branch 289
- cerebellar veins
hemispheric 293
inferior 293, 295
superior 295
precentral 295
- cerebral artery
anterior 281
second segment 281, 283
third segment 281
- corpus callosal branch 291
- middle
first segment 281
second segment 281, 283
posterior 289, 291
thalamic branches 291
- cerebral veins
great, of Galen 285, 287, 295
internal 285, 287, 295
superior 293
- cerebrum, communicating artery
anterior 281
posterior 283, 291
- cervical artery, ascending 297
- cervical canal 365
- cervical spine 44–49, 89, 243
intervertebral disk space 45, 47
intervertebral facet joint 47
intervertebral foramen 49
- cervical vertebrae see vertebrae
- cervical vessels, angiogram, anterior-posterior 296–297
- chest
anterior oblique
left 218–219
right 216–217
lateral 212–213
posterior-anterior 208–211
wall 214
- child
acetabulum roof 63
femur, epiphysis 63
ilium 63
ischium 63
pelvis, anterior-posterior 62–63
pubic bone 63
tibial apophysis, proximal 177
- cholangiopancreatography, endoscopic retrograde (ERCP) 368–369
- cholecystocholangiography 266–267
- Chopart's joint 187, 203
- choroidal arteries
anterior 281, 283
lateral/medial/posterior 291
- Citelli, angle of 33
- clavicle 51, 101, 107, 109, 111, 275
acromioclavicular joint 93, 95
anterior-posterior 85, 90–91, 97, 103, 105, 113, 273
conoid tubercle 91, 95
distal end 83, 99
posterior-anterior 209
proximal 89, 91
sternal end, lateral 87, 115
stress view 89
- clinoid processes, anterior/posterior 5, 39
- clivus 39
- coccyx 65, 261
anterior-posterior 61, 75, 78–79
cornu of 75, 79
Guthmann's view 67
lateral 77, 80–81
- cochlea 29, 31, 35
- colic arteries, middle/right 309
- colic vein, right 311
- colon 253
ascending 257, 259
contrast studies 258–259
descending 259
haustra 257, 259
hepatic flexure 259
sigmoid 259
splenic flexure 259
gas in 221

- transverse 259
gas in 221
- communicating artery of cerebrum
anterior 281
posterior 283, 291
- condylar process, mandible 3
- confluence of sinuses 287, 293, 295
- conoid tubercle 91, 95
- contrast studies
arthrography 268–279
colon 258–259
defecography 262–263
duodenum 250–251
esophagus 244–247
gastrointestinal system 240–263
hypopharynx
anterior-posterior 240–241
lateral 242–243
intravenous 264–267
cholecystocholangiogram 266–267
urogram 264–265
rectum 260–261
small bowel 252–255
stomach 246–253
venography 326–337
see also arteriography; arthrography
- Cooper's ligaments 225, 227
- coracoid 89
- coracoid process 83, 101, 107, 109, 111, 115
acromioclavicular joint
view 93, 95
anterior-posterior 91, 97, 103, 105
arthrography 273, 275
- coronal suture 5
- coronoid fossa 115, 119, 127
- coronoid process
mandible 5, 17, 19, 21, 29
end view 27
ulna 115, 117, 119, 123, 125, 127
- corpus callosum branch, cerebral artery 291
- costal arch 83
- costal notch 85
- costodiaphragmatic recess 209, 221
- costophrenic angle 209, 221
- costotransverse joint 83, 91
- costovertebral articulation 83
- cranial fossa
anterior, floor of 39
middle
anterior wall 29
greater wing 29
- cribriform plate 5
- crista galli 11
- cubital tunnel 121
- cubital vein, median 335
- cuboid bone
anterior-posterior 187, 197, 201
lateral 181, 189, 191
oblique 183, 185, 199, 203
secondary 187
- cuneiform bones
lateral 183, 187, 189, 197, 199, 201, 203
medial 181, 183, 187, 189, 197, 199, 201, 203
middle 183, 187, 189, 197, 199, 201, 203
- cuneonavicular joint 189, 199
- cystic artery 305
- cystic duct 267, 369
- D**
- defecography 262–263
- deltoid tuberosity 113
- dens 7, 11
of the axis 3, 29, 43, 45, 231
- dentin 23
- descending aorta 209, 213, 217, 219, 233, 299
- diaphragm 51, 53, 209, 217, 221
insertions 209
- diploe 5
- disk, intervertebral *see* intervertebral disk
- disk space, intervertebral *see* intervertebral disk space
- dorsalis pedis artery 325
- dorsum sellae 31, 39
- duct
bile, common 267, 369
cystic 267, 369
- hepatic
common 267, 369
left 369
lateral/medial
branches 369
right 369
- lactiferous 225, 227, 367
main 367
- lateral, primary/secondary/tertiary 369
- pancreatic
accessory 369
body/head/tail regions 369
- parotid 361, 363
intralobular system 363
- Stensen's 361, 363
- ductules, breast 367
- duodenojejunal flexure 253
- duodenum 249
ascending 253
contrast studies 250–251
descending 251, 253
horizontal part 253
- dural sac 343, 347, 349
- distal end 345, 349
- lateral margin 341
- E**
- ear
auditory canal
external 33, 37
opening 5
internal 3, 7, 11, 29, 31, 33, 35
cochlea 29, 31, 35
inner 31
outer 33
semicircular canals 7, 29
anterior 31, 35
lateral 31, 35
tympanic cavity 31, 35, 37
roof of 35
- elbow
anterior-posterior 116–117
axial 120–121
lateral 118–119
- enamel 23

- endoscopic retrograde
 cholangiopancreatogra-
 phy (ERCP) 368–369
 epidural fat 345
 epiglottis 231, 241, 245
 esophageal hiatus 247
 esophagus 231, 241, 243
 abdominal 247, 249
 aortic segment 245
 body of 245
 bronchial segment 245
 contrast studies
 244–247
 distal 247
 epiphrenic segment 245
 interbronchial segment
 245
 paratracheal segment
 245
 retrocardiac segment
 245
 sphincter, upper 245
 ethmoid sinus 3, 5, 13,
 15, 41
 anterior 9, 11
 posterior 9
 ethmoidal groove 25
 extensor recess, wrist 271
 external auditory canal
 33, 37
 opening 5
 extradural space 341
- F**
- facet joints
 cervical spine 47, 49
 lumbar spine 55
 thoracic spine 53
 facial artery 297
 facial bones, pantomo-
 gram 22–23
 facial nerve 361, 363
 fallopian tube 365
 fimbriae 365
 uterine ostium 365
 fat
 epidural 347
 knee, posterior to 165
 preperitoneal 223
 subcutaneous
 abdominal 223
 breast 225, 227, 367
 fat pad, intrapatellar 165
 fat stripe
 intergluteal 149
 medial to gluteus mini-
 mus 61, 149
 medial to iliopsoas 61,
 149
 femoral arteries
 deep 319
 lateral circumflex 319
 ascending/descending
 branch 319
 medial circumflex 319
 superficial 319, 321
 femoral vein 337
 deep/superficial 337
 femur 67
 anterior-posterior 61,
 63, 147, 149, 163
 condyle
 lateral 167, 173
 anterior-posterior
 147, 159, 163, 175
 lateral view 161,
 165, 177
 rotational view 169,
 171
 medial 167, 173
 anterior-posterior
 147, 159, 163, 175
 lateral view 161, 177
 rotational view 169,
 171
 cortex 159, 161
 distal third 147, 161
 epicondyles, lateral/me-
 dial 159, 163, 167
 epiphysis, child 63
 growth plate 163
 Guthmann's view 67
 head 65, 69, 71, 151,
 157, 261
 anterior-posterior 75,
 147, 149
 articular surface
 anterior 153
 posterior 155
 fovea 149
 Guthmann's view 67
 tangential views
 (Schneider) 151–155
 intercondylar fossa 161,
 167, 169, 171, 173
 lateral view 161, 165,
 167
 medial third 161
 medullary canal 159
 middle third 147
 neck 61, 149, 151, 153,
 155, 157
 obturator view 71
 Shenton's line 63
 proximal third 147, 161
 shaft 159, 169, 171
 fibula 195, 279
 anterior-posterior 147,
 163, 175, 179
 cortex 177
 head of 167
 anterior-posterior
 159, 163, 175
 apex 161
 lateral view 161, 165,
 177
 rotational view 169,
 171
 lateral view 161, 177,
 181
 medullary canal 177
 neck of 165, 167, 175
 oblique 183, 185, 189
 shaft 169, 171
 see also malleolus,
 lateral
 fibular artery, circumflex
 323
 fimbriae, fallopian tube
 365
 fingers 128–129
 in two planes 144–145
 fissure
 orbital, superior 13, 15
 sphenopetrosal 35
 flexor recess, wrist 271
 foot 186–205
 accessory bones 187
 angiogram 324–325
 anterior-posterior
 186–187
 lateral view 188–189
 sesamoid bones 187,
 189, 201, 203, 205
 foramen
 infraorbital 9
 intervertebral
 cervical spine 49
 lumbar spine 55, 57,
 59, 347
 thoracic spine 53
 jugular 7
 mandibular 19
 mental 19, 21, 23
 obturator 61, 69, 71,
 147, 149, 157
 Guthmann's view 67
 Laurenstein view 151
 Schneider view 153
 Shenton's line 63
 sacral 55, 73, 75, 79, 237
 tooth, apical 19, 23
 foramen lacerum 29

foramen magnum 5, 7, 31, 45
 foramen ovale 9, 29
 foramen rotundum 9, 13
 forearm 124–127
 distal/middle/proximal thirds 125, 127
 venogram, pronation/supination 334–335
 forefoot 200–203
 fossa
 coronoid 115, 119, 127
 cranial
 anterior, floor of 39
 middle 29
 anterior wall 29
 greater wing 29
 glenoid 91, 95, 101, 103, 107, 111, 115
 articular surface 89
 intercondylar 161, 167, 169, 171
 olecranon 113, 115, 117, 119, 123, 125, 127
 pituitary 5, 39, 41
 popliteal 161
 pterygoid 29
 pterygopalatine 23, 29
 subarcuate 35
 supraspinatus 101
 of Sylvius, veins of 285, 287
 temporomandibular joint 33
 temporal 27
 Frik tunnel view 166–167
 frontal artery, internal, anterior/medial/posterior 282
 frontal sinus 3, 5, 9, 11, 13, 15, 31, 41
 frontal veins 285
 ascending 287
 frontonasal suture 25
 frontozygomatic suture 3

G

galactogram 366–367
 Galen, great cerebral vein 285, 287, 295
 gallbladder
 body of 267, 369
 fundus 267, 369
 neck of 267, 369
 gastric artery, left/right 305

gastric bubble 209, 213, 217, 219, 221
 gastric folds, posterior wall 249
 gastroduodenal artery 305
 gastroepiploic artery, right 305
 gastroesophageal angle 247
 gastrointestinal system, contrast studies 240–263
 genicular artery
 descending 321
 inferior medial 321
 middle 321
 superior lateral 321
 superior medial 321
 gland, parotid 361, 363
 accessory 361
 deep lobe 361, 363
 sialogram 360–363
 superficial lobe 361, 363
 glandular tissue, breast 225, 227
 glenohumeral joint 107
 glenoid fossa 91, 95, 101, 103, 107, 111, 115
 articular surface 89
 glenoid labrum 103, 273, 275
 glossoepiglottic fold, lateral 241, 245
 gluteal artery, inferior/superior 317
 gluteus minimus, fat stripe medial to 61, 149
 gonad shield 43
 great toe 204–205
 distal interphalangeal joint 187
 distal phalanx 187

H

hamate bone 129, 131, 133, 137, 139, 141, 143
 hook 133, 135, 137
 hand
 anterior-posterior view 128–129
 oblique view 130–131
 sesamoid bones 129, 131, 143
 see also fingers
 hard palate 5, 13, 23

haustra, of colon 257, 259
 heart, posterior-anterior radiograph 210–211
 hemidiaphragm
 left 213, 219
 right 213, 219
 hepatic artery
 common 305
 proper, left/right branch 305
 hepatic duct
 common 267, 369
 left 369
 lateral/medial branches 369
 right 369
 Hilgenreiner's line 63
 hindfoot, standing patient 194–195
 hip
 anterior-posterior 43, 75, 148–149
 axial view 156–157
 joint space 67, 147
 lateral view 77
 Lauenstein view 150–151
 humeroradial joint 117, 119, 123, 125
 humeroulnar joint 117, 119, 123, 125
 humerus 89, 111, 123
 anterior-posterior 113, 117, 125
 axial view 107, 121
 bicipital groove 93, 95, 103, 107, 109, 111, 113
 capitellum 115, 117, 121, 123, 125
 coronoid fossa 115, 119, 127
 cortex 105, 115
 deltoid tuberosity 113
 distal third 115
 epicondyle
 lateral 113, 117, 119, 121, 123, 125
 medial 113, 117, 119, 121, 123, 125
 apex of 117
 head of 83, 89, 101, 107, 109, 111
 acromioclavicular joint view 93, 95
 anterior-posterior 91, 97, 103, 105, 113
 lateral view 115

- lateral view 119, 127
 medial third 115
 metaphysis 105
 neck
 anatomical 103, 113
 surgical 103, 105, 111, 113
 olecranon fossa 113, 115, 117, 119, 123, 125, 127
 proximal third 115
 shaft 99, 101, 115
 trochlea 113, 115, 117, 121, 123, 125, 127
 lateral/medial margins 117
 tubercle
 greater 89, 93, 95, 103, 107, 109, 111, 113
 crest of 109
 lesser 89, 93, 95, 103, 107, 109, 111, 113, 115
 venogram 335
 see also coracoid process
- hyoid bone 23, 231, 243
 hypopharynx
 anterior-posterior 240–241
 lateral 242–243
 hysterosalpingogram 364–365
- I**
- ileal arteries 309
 ileal veins 311
 ileocecal region, spot images 256–257
 ileocecal valve 257, 259
 ileocolic artery 309
 ileocolic vein 311
 ileum 253, 255, 257
 terminal 257
 iliac bone 155
 iliac crest 61, 65, 69, 221, 223
 Guthmann's view 67
 lateral view 57, 77, 81
 myelogram 345
 iliac lymph channels 353
 iliac lymph nodes
 common 351, 353, 355
 external 353, 355
 lymph channels of 351
 internal 353, 355
 iliac spine
 anterior
 inferior 67, 69, 149, 151, 153, 157
 superior 61, 65, 67, 69, 149, 151, 153, 155
 posterior
 inferior 61, 65, 75, 237
 superior 61, 65, 75, 237
 iliac vein
 common 329, 331, 337
 external 329, 331, 337
 internal 329, 331
 iliac wing 61, 65, 69, 73, 75, 237
 ilioischial line 149
 iliopectinal line 71
 iliopsoas, fat stripe medial to 61, 149
 iliopubic line 65
 ilium 43, 73, 153, 221, 223, 237
 of child 63
 incisor teeth 21, 23
 infraorbital foramen 9
 infundibulum 217, 327
 inguinal lymph nodes
 deep 351
 superficial 351, 353
 innominate line 3, 11, 13
 interarytenoid notch 229
 intercavernous sinus 285
 intercondylar fossa 161, 167, 169, 171
 intergluteal fat stripe 149
 interlobular arteries 313
 interlobular vein 315
 internal auditory canal 3, 7, 11, 29, 31, 33, 35
 interosseous membrane 125, 127, 167, 175
 interphalangeal joint
 distal 129, 131, 145, 187, 201, 203, 205
 great toe 205
 proximal 129, 131, 145, 187, 201, 203, 205
 intertarsal joint 201, 203
 intertrochanteric crest 61, 149, 153, 155
 intertubercular sheath 273, 275
 intervertebral disk 341, 343, 345, 347
 L3–4 349
 intervertebral disk space
 cervical spine 45, 47
 lumbar spine 55, 57, 59
 thoracic spine 53
 intervertebral facet joints
 cervical spine 47, 49
 lumbar spine 55
 thoracic spine 53
 intervertebral foramen
 cervical spine 49
 lumbar spine 55, 57, 59, 347
 thoracic spine 53
 intradural space 341
 intralobular ductal system (parotid) 361
 intramedullary region 341
 intrapatellar fat pad 165
 intravenous contrast studies 264–267
 cholecystocholangiogram 266–267
 urogram 264–265
 ischium 147, 151, 153, 155
 body of 67
 child 63
 lateral view 81
 posterior column 69, 71, 149, 151
 spine of 65, 69, 149, 151, 153, 155
 anterior-posterior view 61, 75
 Guthmann's view 67
 lateral view 77, 81
 tuberosity 65, 67, 71, 151, 153, 157
 anterior-posterior 61, 147, 149
- J**
- jaw bones
 pantomogram 22–23
 see also mandible;
 maxilla
 jejunal arteries 309
 jejunal veins 311
 jejunum 253, 255
 joint space
 ankle 183, 185, 195, 279
 hip 67, 147
 knee 147, 169, 171
 joints
 acromioclavicular 92–95, 101, 107, 109, 111
 anterior-posterior 91, 97, 103, 105
 lateral 99, 115
 stress view 89

- atlantoaxial 11, 45
 calcaneocuboid 189, 201
 carpometacarpal 133, 143
 Chopart's 187, 203
 costotransverse 83, 91
 cuneonavicular 189, 199
 facet
 cervical spine 49
 lumbar spine 55
 thoracic spine 53
 glenohumeral 107
 humeroradial 117, 119, 123, 125
 humeroulnar 117, 119, 123, 125
 interphalangeal
 distal 129, 131, 145, 187, 201, 203, 205
 great toe 205
 proximal 129, 131, 145, 187, 201, 203, 205
 intertarsal 201, 203
 intervertebral facet
 cervical spine 47, 49
 lumbar spine 55
 thoracic spine 53
 Lisfranc's 187, 203
 metacarpophalangeal 129, 131, 143, 145
 metatarsophalangeal 187, 189, 201, 203, 205
 patellofemoral 161, 173
 radiocarpal 125, 127, 133, 143
 radioulnar 133
 distal 125, 129
 proximal 117, 123, 125
 sacroiliac 69, 71, 151, 153, 155
 anterior aspect 237
 anterior-posterior 43, 55, 61, 75, 149
 middle portion 237
 thirty-degree anterior oblique view 72-73
 tomogram 236-237
 sternoclavicular 85, 93
 subtalar 177, 183, 185, 191, 199
 talocalcaneal 183, 185
 talocalcaneonavicular 189, 199, 201, 203
 talocrural 183, 185, 195
 talonavicular 181
 tarsal, transverse 187, 203
 tarsometatarsal 187, 189, 199, 203, 205
 temperomandibular 7, 19, 21
 fossa 33
 tibiofibular 161, 169, 279
 uncovertebral 45
 see also ankle; elbow; hip; knee; shoulder; wrist
 jugular foramen 7
 jugular veins
 bulb of 293
 external 327
 internal 287, 327
 junction
 anorectal 261
 ileum and jejunum 255
 rectosigmoid 261
- K**
- kidney
 calyces, inferior/middle/superior 265
 left 223, 265
 pelvis 265
 pole, inferior/superior 265
 right 223, 265
 knee 162-165, 177
 angiogram 320-321
 arthrogram 276-277
 capsular recess, inferior/superior 277
 cartilage 277
 forty-five-degree rotation views 168-171
 Frik tunnel view 166-167
 joint space 147, 169, 171
 meniscus 277
 popliteal bursa 277
 posterior fat 165
 Köhler's teardrop figure 149
- L**
- Labbé, vein of 287
 lactiferous duct 225, 227, 367
 lactiferous sinus 367
 lacunar lymph nodes 353, 355
 lateral 351
 lambdoid suture 3, 5, 7
 lamina, spinal 47, 59
 larynx 243
 ventricle 229, 231, 243
 vestibule 229, 231
 lateral ducts, primary/secondary/tertiary 369
 lateral malleolus *see* malleolus, lateral
 leg
 angiograms 318-325
 full-length anterior-posterior view 146-147
 lower 174-177
 angiogram 322-323
 distal third 147, 177
 medial third 147
 middle third 177
 proximal third 147, 177
 venogram, rotational views 336-337
 see also ankle; hip; knee; thigh
 ligaments
 Cooper's 225, 227
 patellar 165
 line
 arcuate 73
 Hilgenreiner's 63
 ilioischial 149
 iliopectinal 71
 iliopubic 65
 innominate 3, 11, 13
 paravertebral 51
 Perkin's 63
 Shenton's 63
 terminal 149
 triradiate cartilage 63
 Lisfranc's joints 187, 203
 liver 223, 307
 inferior margin 221
 lobe, breast 367
 lobules of breast 367
 contour 225, 227
 lower extremities
 skeletal imaging 146-205
 see also ankle; foot; knee; leg; thigh

- lumbar lymph nodes 351, 353
 lumbar lymphangiography, anterior-posterior channel phase 350–351
 nodal phase 354–355
 lumbar myelography
 anterior-posterior 344–345
 lateral 346–347
 oblique 348–349
 lumbar spine 43, 54–59
 intervertebral disk space 55, 57, 59
 intervertebral foramen 57, 59, 347
 myelography 344–349
 lumbar vertebrae *see* vertebrae
 lunate bone 127, 137, 139, 141
 anterior-posterior 125, 129, 133
 lateral view 135
 oblique view 131, 143
 lung
 apex 209
 curve of 209
 left 209, 217, 219
 lower lobe
 basal segment
 anterior 215
 anterior-medial 357, 359
 lateral 215, 357, 359
 posterior 215, 357, 359
 medial segment 215
 superior segment 215, 357, 359
 lower region 214
 middle lobe
 lateral segment 215
 lingular segment, inferior/superior 215
 medial segment 215
 middle region 214
 pericardial region 214
 perihilar region 214
 right 209, 217, 219
 right hilum, lateral tomogram 234–235
 segments of 214–215
 supradiaphragmatic region 214
 upper lobe
 anterior segment 215, 357, 359
 apical-posterior segment 215, 357, 359
 apical segment 215
 axillary subsegment 215
 left 217
 lingula segment
 inferior 357, 359
 superior 357
 posterior segment 215
 upper region 214
 lungs, posterior border between 209
 lymph channels, of external iliac lymph nodes 351
 lymph nodes
 iliac
 common 351, 353, 355
 external 353, 355
 lymph channels of 351
 internal 353, 355
 inguinal
 deep 351
 superficial 351, 353
 lacunar 353, 355
 lateral 351
 lumbar 351, 353
 para-aortic, lateral aortic/preaortic/retro-aortic 355
 promontory 351, 353, 355
 lymph tracts
 iliac channels 353
 lumbar trunk, left/right 351, 353
 lymphangiography, bipedal 350–355
 anterior-posterior channel phase 350–351
 nodal phase 354–355
 oblique, channel phase 352–353
M
 malleolus 199
 lateral 193, 195, 279
 anterior-posterior 147, 175, 179, 187, 197
 lateral view 177, 181, 191
 oblique view 183, 185
 medial 195, 279
 anterior-posterior 147, 175, 179, 187, 197
 lateral view 177, 181
 oblique view 183, 185
 mammography
 craniocaudal 224–225
 mediolateral 226–227
 mandible 9, 49
 angle of 3, 17, 19, 21, 23
 anterior-posterior 229, 363
 Clementschtsch view 20–21
 condylar process 3
 condyle 7, 9, 19, 21, 31, 33, 35, 37
 coronoid process 5, 17, 19, 21, 29
 end view 27
 lateral view 5, 47, 231, 243
 posterior-anterior 3
 ramus 17, 18–19, 21
 cortex 19
 spot view 229, 231
 mandibular canal 3, 19, 21, 23
 mandibular foramen 19
 manubrium, of sternum 85, 87, 93
 marginal air cells 33
 marginal artery 289
 mastoid
 antrum 31, 33, 35, 37
 apex 37
 process 3
 mastoid air cells 7, 29, 31, 33
 maxilla 3, 16–17, 21, 25
 alveolar process 9
 alveolar recess 9, 23
 lateral wall 17
 maxillary sinus 9, 11, 15, 17, 21, 23, 27, 29, 31
 lateral view 5
 medial wall 41
 posterior-anterior 3, 13
 posterior wall 29
 zygomatic recess 27
 medial malleolus *see* malleolus, medial
 mediastinum
 anterior, inferior/superior 214
 middle 214
 posterior 214

- medullary cone 341, 343
 meningeal artery, middle,
 groove of 5
 meniscus
 knee 277
 wrist 269, 271
 mental foramen 19, 21, 23
 mental protuberance 3,
 19, 21
 mesenteric artery, supe-
 rior 305, 309
 arteriography
 arterial phase
 308–309
 venous phase
 310–311
 mesenteric vein 307
 superior 311
 metacarpal bones 129,
 131, 135, 139, 141, 145
 base 129, 131
 fifth 133, 143
 base/head/shaft 143
 fourth 143
 heads of 129, 131
 oblique view 142–143
 third 143
 metacarpophalangeal
 joint 129, 131, 143, 145
 metatarsal bones 183,
 187, 189, 201, 203
 anterior-posterior view
 196–197
 fifth 195
 base of
 anterior-posterior
 187, 197, 201
 lateral view 181,
 189, 191
 oblique view 199,
 203
 first 205
 head 187
 oblique view 198–199
 metatarsophalangeal joint
 187, 189, 201, 203, 205
 middle meningeal artery,
 groove of 5
 mitral valve 211, 213
 molar teeth 21, 23
 muscles
 abdominal 223
 biceps, tendon sheath of
 long head 273, 275
 obturator internus 61,
 223
 psoas 55, 223
 margin 221, 265
 puborectalis 263
 myelography 341–349
 lumbar
 anterior-posterior
 344–345
 lateral 346–347
 oblique 348–349
 thoracic
 anterior-posterior
 340–341
 lateral 342–343
- N**
- nasal bones 5, 9, 25
 inferior 3
 nasal cartilage 25
 nasal cavities 11, 21, 31
 nasal septum 3, 9, 11, 13,
 17, 29, 31, 41
 nasal sinuses
 occipitofrontal view
 10–11
 Waters view 8–9
 nasal spine, anterior 17,
 25
 nasal turbinates 41
 nasomaxillary suture 25
 nasopharynx 5
 posterior 231
 navicular bone
 anterior-posterior 187,
 197, 201
 lateral view 177, 181,
 189, 191
 oblique view 183, 185,
 199, 203
 nerve, facial 361, 363
 nerve root, spinal 345
 nerve root sheath 341,
 345
 L3 349
 nipple 225, 227, 367
 nose 24–25
 vestibule 25
- O**
- obturator foramen 61, 69,
 71, 147, 149, 157
 Guthmann's view 67
 Laurenstein view 151
 Schneider view 153
 Shenton's line 63
 obturator internus muscle
 61, 223
 occipital artery, medial,
 calcarine branch 289,
 291
 occipital bone 7, 45
 occipital crest 7
 internal 35
 occipital protuberance
 external 7
 internal 7, 35
 occipital sinus 287
 occipital veins 287
 occiput 3
 odontoid process 47, 49
 olecranon 121, 123
 anterior-posterior 113,
 117, 125
 lateral view 115, 119,
 127
 olecranon fossa 113, 115,
 117, 119, 123, 125, 127
 ophthalmic artery 281,
 283
 optic canal 15
 oral cavity 231
 orbit 9, 13, 29
 floor of 13, 17
 lateral wall 11, 13, 15
 see also zygomatic
 bone
 medial wall 41
 posterior-anterior view
 12–13
 Rhesus view 14–15
 roof of 3, 11, 13, 15,
 31, 39
 orbital artery, frontal 281,
 283
 orbital fissure, superior
 13, 15
 orbital plate 13, 41
 oropharynx 243
 os frontale 4
 os intermetatarsium 187
 os occipitale 4
 os parietale 4
 os peroneum 187
 os sphenoidale 4
 os supratolare 187
 os temporale 4
 os tibiale externum 187
 os trigonum 191
 os vesalianum 187
 os zygomaticum 4
 osseous hemithorax
 82–83
 osseous labyrinth 37
 osseous sinus, wall 37

P

- Paccionian granulations 3
 pancreatic duct
 accessory 369
 body/head/tail regions 369
 pancreaticoduodenal artery
 inferior 305, 309
 superior 305
 pantomogram, facial/jaw bones 22–23
 papilla of Vater 251, 369
 para-aortic lymph nodes, lateral aortic/preaortic/retroaortic 355
 paraaortic stripe 209
 paracentral artery 282
 paraspinal stripe 209
 paratracheal stripe, right 209
 paravertebral line 51
 parietal artery
 anterior/posterior 281, 282
 internal, inferior/superior 282
 parietal bone, inner/outer tables 5
 parietal vein 285, 287
 parieto-occipital artery 289, 291
 parotid duct 361, 363
 intralobular system 363
 parotid gland 361, 363
 accessory 361
 deep lobe 361, 363
 sialogram, lateral 360–363
 superficial lobe 361, 363
 patella 147, 159, 161, 163, 165, 167
 articular surface 173
 lateral margin 171
 medial margin 169
 multipartite 172
 views of 172–173
 Wilberg's shape classification 172
 patellar ligament 165
 patellofemoral joint 161, 173
 pedicle
 cervical spine 45, 49
 contralateral 49
 lumbar spine 43, 55, 59
 sacral spine 237
 thoracic spine 51
 pelvic region 60–81
 pelvis
 anterior-posterior 60–61
 aortic angiogram 316–317
 child, anterior-posterior 62–63
 Guthmann's view 66–67
 iliac wing view 68–69
 inlet view 64–65
 obturator view 70–71
 Perkin's line 63
 perforating artery 319
 periantral air cells 33, 37
 pericallosal artery 281, 282
 Perkin's line 63
 peroneal artery 321, 323
 peroneal trochlea 193
 peroneal veins 337
 peroneus longus tendon, groove for 193
 petrosal sinus
 inferior 285, 287, 293, 295
 superior 287, 293, 295
 petrosal vein 293
 petrous bone 7
 anterior margin 33
 apex 33, 37
 Mayer view 36–37
 posterior margin 37
 Schüller view 32–33
 Stenvers view 34–35
 petrous portion, temporal bone 5, 15
 petrous pyramid, apex 35
 petrous ridge 3, 9, 11, 13, 39
 Altschul view 30–31
 phalanx
 finger
 distal 129, 145
 distal (tuft) 129, 145
 middle 129, 145
 head 129
 proximal 129, 131, 133, 135, 143, 145
 base 129, 131, 145
 head 131, 145
 toe
 base 187
 distal 187, 189, 201, 203, 205
 distal (tuft) 187, 205
 middle 187, 189, 201, 203, 205
 proximal 187, 189, 201, 203, 205
 head 187
 pharynx 241
 piriform recess 229, 241, 243, 245
 inferior posterior margin 231
 pisiform bone 137, 139, 143
 anterior-posterior 125, 129, 133
 lateral view 127, 135
 special view 140–141
 pituitary fossa 5, 39, 41
 plantar aponeurosis 191
 plantar artery 325
 plexus, pterygoid 287
 polar artery
 frontal 281, 282
 temporal 281
 popliteal artery 321
 popliteal bursa 277
 popliteal fossa 161
 popliteal vein 337
 portal vein 307, 311
 left/right branches 311
 posterior arch of the atlas 7, 47
 prefrontal arteries 281, 283
 premolar teeth 21, 23
 preperitoneal fat 223
 promontory
 acetabulum 61, 63, 149
 sacrum 57, 67, 77, 237
 promontory lymph nodes 351, 353, 355
 psoas muscle 55, 223
 margin 221, 265
 pterygoid fossa 29
 pterygoid plexus 287
 pterygoid process 23
 pterygopalatine fossa 23, 29
 pubic bone 147, 151, 155, 157
 anterior column 69, 71, 149, 151, 153
 child 63
 pubic ramus
 inferior 61, 65, 67, 71, 151
 superior 61, 65, 67, 75, 79, 149, 151

- pubic symphysis 61, 65, 67, 79
- puborectalis muscle 263
- pulmonary artery
 apical branch 301, 303
 apicoposterior branch 303
- arteriography
 arterial phase 300–301
 venous phase 302–303
- left 211, 217, 219, 301, 327
- lingular branch 301
- lobar branch
 inferior 211, 233, 235, 301
 right 217
 middle 235, 301
 superior 235
- main 211, 213, 217
- right 211, 219, 233, 235, 301, 327
 intermediate part 211
 trunk 301
- pulmonary hilum tomogram 232–233
- pulmonary trunk 327
- pulmonary valve 211, 213
- pulmonary veins 213, 217, 233
 inferior 303
 left/right 217
 left 219
 right 219
 superior 303
- pulp cavity 19, 23
- pylorus 249, 251
 antrum 249, 251, 253
- R**
- radial veins 335
- radiocarpal joint 125, 127, 133, 143
- radiographs
 abdomen
 standing 220–221
 supine 222–223
 chest
 anterior oblique view
 left 218–219
 right 216–217
 lateral view 212–213
 posterior-anterior 208–211
 lung, segments of 214–215
- radioulnar joint 133
 distal 125, 129
 proximal 117, 123, 125
- radius 121, 139, 141
 anterior-posterior 113, 117, 125, 133
 distal 129, 131
 head of 113, 115, 117, 119, 121, 123, 125, 127
 lateral arthrogram 271
 lateral view 115, 119, 127
 neck of 117, 123, 125, 127
 oblique view 122–123, 143
 styloid 125, 129, 131, 133, 135, 139, 143
 tuberosity 119, 123, 125
 venogram 335
- rectal fold, transverse 261
- rectal gas 81
- rectosigmoid junction 261
- rectum 259
 ampulla 261, 263
 contrast studies 260–261
- renal arteries 331
 arteriogram
 arterial phase 312–313
 venous phase 314–315
 left/right 313
- renal veins 331
 left/right 315, 329
 superior branch 315
- retrocardiac space 213
- retrofacial air cells 33
- retropharyngeal space 231
- retrorectal space 261
- retrosinus air cells 37
- retrosternal space 87, 213
- ribs 43, 49, 59, 97, 101
 first 45, 51
 tubercle 51
 head 51, 53, 83
 neck 51, 83
 twelfth 265
- rima glottidis 229
- root canal 19, 23
- root of the tooth 23
- Rosenthal, basal vein of 285, 287, 295
- routine radiography 208–223
- S**
- sacral ala 65, 75, 237
- sacral canal 77, 81
- sacral crest
 lateral 75, 79, 81
 median 75, 77, 79, 81
- sacral foramina 55, 73, 75, 79, 237
- sacral hiatus 75, 79
- sacroiliac joint 69, 71, 151, 153, 155
 anterior aspect 237
 anterior-posterior 43, 55, 61, 75, 149
 middle portion 237
 thirty-degree anterior oblique view 72–73
 tomogram 236–237
- sacrum 65, 67, 69, 221, 223, 261
 ala 65, 75, 237
 anterior aspect 237
 anterior-posterior 43, 55, 61, 74–75, 149
 cornu 75, 77, 79, 81
 lateral part of 73
 lateral view 57, 76–77, 81
 myelogram 345
 promontory 57, 67, 77, 237
- sagittal sinus
 inferior 287
 superior 285, 287
- sagittal suture 3
- saphenous veins, great/small 337
- scaphoid bone 137, 138–139, 141
 anterior-posterior 125, 129, 133
 lateral view 127, 135
 oblique view 131, 143
- scapula 96–97, 103, 107, 111, 213
 articular surface 97
 costal surface 101
 glenoid fossa 91, 95, 101, 103, 107, 111, 115
 articular surface 89
 glenoid labrum 103, 273, 275
 glenoid process 89
 inferior angle 83, 99, 101
 lateral process (neck) 97, 113

- lateral view 98–99
 margins
 inferior 97
 lateral/medial 89, 97, 103
 neck of 107
 posterior surface 101
 spine of 89, 91, 97, 101, 103, 105
 superior angle 89, 91, 97, 99, 101, 103, 105, 107
 thoracic spine view 53
 see also coracoid process
- sciatic notch
 greater 67, 75, 77, 81
 lesser 77
- segmental arteries 301, 303
 anterior/posterior 313
 inferior/superior 313
 middle 313
- sella turcica 38–41
 floor of 41
- sellae, dorsum/tuberculum 39
- semicircular canals 7, 29
 anterior/lateral 31, 35
- septum pellucidum, vein of 287
- sesamoid bones
 foot 187, 189, 201, 203, 205
 hand 129, 131, 143
- Shenton's line 63
- shoulder
 anterior-posterior 102–103
 abduction 104–105
 arthrography
 anterior-posterior 272–273
 oblique 274–275
 axial view 106–107
 axillary recess 273, 275
 glenoid labrum 103, 273, 275
 soft tissues 213
 stress view 88–89
 tangential view 108–109
 trans-scapular "Y" view 100–101
 transthoracic view 110–111
- sialography 360–363
- sigmoid sinus 37, 285, 287, 293, 295
 sulcus 33
- sinus tarsi 181, 191, 199
- sinuses
 cavernous 295
 anterior/posterior drainage 287
 confluence of 287, 293, 295
 ethmoid 3, 5, 13, 15, 41
 anterior 9, 11
 posterior 9
 frontal 3, 5, 9, 11, 13, 15, 31, 41
 intercavernous 285
 lactiferous 367
 maxillary 9, 11, 15, 17, 21, 23, 27, 29, 31
 lateral view 5
 medial wall 41
 posterior-anterior 3, 13
 posterior wall 29
 zygomatic recess 27
- nasal
 occipitofrontal view 10–11
 Waters view 8–9
- occipital 287
- osseous, wall 37
- petrosal
 inferior 285, 287, 293, 295
 superior 287, 293, 295
- sagittal
 inferior 287
 superior 285, 287
- sigmoid 37, 285, 287, 293, 295
 sulcus 33
- sphenoid 5, 9, 15, 29, 39
- sphenoparietal 285
 straight 287, 293, 295
- tarsal 181, 191, 199
- transverse 285, 287, 293, 295
 sulcus of 7
- skin, breast 225, 227, 367
- skull 2–41
 base 17, 28–29, 47, 231
 jaw and facial bones
 pantogram 23–23
 lateral view 4–5
 posterior-anterior view 2–3
- posterior (Towne) view 6–7
see also mandible;
 maxilla; nasal sinuses;
 orbit; petrous bone;
 sella turcica
- small bowel
 contrast studies 252–255
 gas in 221
- soft palate 5
- sphenoid bone 3, 11, 13, 15, 39, 41
 greater wing 5, 9, 13, 39
 lesser wing 13, 15
 pituitary fossa 5, 39, 41
 pterygoid fossa 29
- sphenoid sinus 5, 9, 15, 29, 39
- sphenoparietal sinus 285
- sphenopetrosal fissure 35
- sphenosquamous suture 35
- spinal cord 341, 343
- spinal lamina 47, 59
- spinal nerve root 345
- spine 42–59
 cervical 44–49, 89, 243
 full-length view 42–43
 interarticular part 59
 lamina 59
 lumbar 43, 54–59
 myelogram
 lumbar 344–349
 thoracic 340–343
 thoracic 43, 50–53
- spinous processes, vertebrae 45, 75, 237
- cervical spine 45, 47, 49
 bifid 45
 lumbar spine 43, 55, 57, 59
 thoracic spine 51, 53
- spleen 223, 307
 lower margin 221
- splenic artery 305, 313
- splenic vein 307, 311
- spot images 224–231
 ileocecal region 256–257
- mammogram
 craniocaudal 224–225
 mediolateral 226–227
- trachea
 anterior-posterior view 228–229
 lateral view 230–231

- squamous air cells 33
Stensen's duct 361, 363
sternal angle 85, 87, 213
sternal notch 85
sternoclavicular joint 85, 93
sternum 219
 anterior-posterior view 84–85
 body of 85, 87, 213
 lateral view 86–87
 manubrium 85, 87, 93
stomach
 angular notch 249
 body of 249, 253
 contrast studies 246–253
 curvature, greater/lesser 249
 fundus 249
 pyloric antrum 249, 251, 253
straight sinus 287, 293, 295
stripe
 azygosophageal 209
 paraaortic 209
 paraspinal 209
 paratracheal, right 209
 see also fat stripe
subarachnoid space
 anterior/posterior 343
 lateral 341
 spinal nerve root in 345
subarcuate fossa 35
subclavian arch 211
subclavian artery 211, 297, 299
subclavian vein 327, 333
subcutaneous fat
 abdominal 223
 breast 225, 227, 367
subcutaneous tissue, breast 367
subglottic space 229, 231
subphrenic space 221
subscapula bursa 273, 275
subtalar joint 177, 183, 185, 191, 199
sulcal artery, precentral 281
sulcus of the transverse sinus 7
supracalcaneal recess 279
supraduodenal artery, superior 305
suprascapular artery 297
suprascapular notch 105
supraspinatus fossa 101
sustentaculum tali 191, 193
sutures
 coronal 5
 frontonasal 25
 frontozygomatic 3
 lambdaoid 3, 5, 7
 nasomaxillary 25
 sagittal 3
 sphenosquamous 35
 temporozygomatic 27
Sylvius, fossa of, veins of 285, 287
- T**
- talocalcaneal joint 183, 185
talocalcaneonavicular joint 189, 199, 201, 203
talocrural joint 183, 185, 195
talonavicular joint 181
talus bone 193, 195
 anterior-posterior 175
 arthrogram 279
 head of 181, 187, 197
 lateral process 181, 191
 lateral view 177, 181, 189, 191
 neck of 181
 oblique view 183, 185, 199
 posterior process 181, 189, 191
 trochlea 147, 177, 181
tarsal joints, transverse 187, 203
tarsometatarsal joints 187, 189, 199, 203, 205
teeth 21, 23
 apical foramen 19, 23
 canines 21, 23
 dentin 23
 enamel 23
 incisors 21, 23
 molars 21, 23
 premolars 21, 23
 pulp cavity 19, 23
 root canal 19, 23
 root of 23
temporomandibular joint 7, 19, 21
 fossa 33
temporal artery, posterior 281, 282
temporal bone 21
 petrous portion 5, 15
 styloid process 23, 33
 subarcuate fossa 35
 zygomatic process 27, 33
temporal fossa 27
temporo-occipital artery 289, 291
temporozygomatic suture 27
tendon
 Achilles 181, 191
 ankle, recess 279
 biceps, insertion 275
 peroneus longus, groove 193
tendon sheath of long head, biceps muscle 273, 275
terminal line 149
thalamoperforate arteries 289
thalamostriate vein, superior 285, 287
thalamus, cerebral artery branches to 291
thigh 158–161
 angiogram 318–319
thoracic artery, internal 297
thoracic spine 43, 50–53
 intervertebral disk space 53
 intervertebral foramen 53
 myelography 340–343
thoracic vertebrae *see* vertebrae
thyrocervical trunk 297, 299
thyroid artery, inferior/superior 297
thyroid cartilage 229, 231
thyroid vein, inferior 327
tibia 167, 183, 185, 195
 anterior-posterior 147, 163, 175, 179
 apophysis, proximal 177
 child 177
 arthrogram 279
 condyle
 lateral 147, 159, 163, 169, 171, 175, 177
 medial 147, 159, 163, 169, 171, 175, 177
 cortex 163, 175
 epiphyseal plate 163

- fibular notch 179
 growth plate 159, 167, 175, 179, 181
 intercondylar eminence 147, 161, 165, 169, 171, 177
 lateral tubercle 159, 163, 167, 175
 medial tubercle 159, 163, 167, 175
 lateral view 161, 165, 177, 181, 189
 medullary canal 175
 plateau 165
 lateral/medial 167
 shaft 169, 171
 tuberosity 165, 167, 175
 see also malleolus, medial
- tibial arteries
 anterior 321, 323, 325
 muscular branch 323
 posterior 321, 323, 325
- tibial veins, anterior/posterior 337
- tibiofibular joint 161, 169, 279
- toe, great 204–205
 distal interphalangeal joint 187
 distal phalanx 187
- tomography 232–237
 lung
 pulmonary hilum 232–233
 right hilum 234–235
 sacroiliac joint 236–237
- tongue 9, 243
 shadow of 23
- tooth *see* teeth
- trachea 21, 47, 51
 bifurcation 233
 carina 209, 219
 distal 229, 231
 myelogram 243
 proximal 229, 231
 radiograph 209, 213, 217, 219
 radiolucent band of 45
 spot images 228–231
 venogram 233, 235
- transverse processes, vertebrae 45, 75, 79, 83, 237
 cervical spine 45, 47, 49
 lumbar spine 55, 57
 contralateral 59
 ipsilateral 59
 L5 73
 thoracic spine 51, 53
 T1 45
 transverse sinus 285, 287, 293, 295
 sulcus of 7
 transverse tarsal joints 187, 203
- trapezium bone 129, 131, 133, 135, 137, 139, 141, 143
- trapezoid bone 129, 131, 133, 135, 137, 139, 141, 143
- triangular fibrocartilage, wrist 269
- tricuspid valve 211, 213
- triquetrum 125, 127
- triquetrum bone 129, 131, 133, 135, 137, 139, 141, 143
- triradiate cartilage line 63
- trochanter
 greater 69, 151, 153, 155, 157
 anterior-posterior 61, 147, 149
 lesser 71, 151, 153, 155, 157
 anterior-posterior 61, 149
- trochlea
 humerus 113, 115, 117, 121, 123, 125, 127
 lateral/medial margins 117
 peroneal 193
 talus bone 147, 177, 181
- Trolard, vein of 285, 287
- tuberculum sellae 39
- turbinate, inferior 13
- tympanic cavity 31, 35, 37
 roof of 35
- U**
- ulna 121, 123, 139
 anterior-posterior 113, 117, 125, 133
 arthrogram 271
 coronoid process 115, 117, 119, 123, 125, 127
 distal 129, 131
 lateral view 115, 119, 127
- styloid 127, 131, 135, 139, 141
 anterior-posterior 125, 129, 133
 arthrogram 271
 venogram 335
 see also olecranon
- ulnar recess, wrist 269, 271
- ulnar veins 335
- uncinat process, cervical vertebrae 45
- uncovertebral joint 45
- upper extremities
 skeletal imaging 82–145
 see also arm; hand; shoulder; wrist
- ureter 265
- urinary bladder 61, 221, 223, 265
- urography 264–265
- uterine ostium, of fallopian tube 365
- uterus
 cavity 365
 fundus 365
- uvula 243, 245
- V**
- vagina 365
- vallecule 241, 243
 floor of 229, 231
- valve
 aortic 211, 213
 ileocecal 257, 259
 mitral 211, 213
 pulmonary 211, 213
 tricuspid 211, 213
- Vater
 ampulla of 249, 251, 253
 papilla of 251, 369
- veins
 anastomotic
 inferior 287
 superior 285, 287
 antebrachial, median 335
 arcuate 315
 of arm, deep 333
 axillary 333
 azygos 211, 233, 327
 basal
 common/inferior 303
 of Rosenthal 285, 287, 295
 basilic 335

- brachial 333, 335
brachiocephalic 211
 left/right 327
breast 225, 227
cephalic 327, 333, 335
cerebellar
 hemispheric 293
 inferior 293, 295
 superior 295
 precentral 295
cerebral
 great, of Galen 285, 287, 295
 internal 285, 287, 295
 superior 293
colic, right 311
cubital, median 335
femoral 337
 deep 337
 superficial 337
of fossa of Sylvius 285, 287
frontal 285
 ascending 287
ileal 311
ileocolic 311
iliac
 common 329, 331, 337
 external 329, 331, 337
 internal 329, 331
interlobular 315
jejunal 311
jugular
 bulb of 293
 external 327
 internal 287, 327
of Labbé 287
mesenteric 307
 superior 311
occipital 287
parietal 285, 287
peroneal 337
petrosal 293
popliteal 337
portal 307, 311
 left/right branches 311
pulmonary 213, 217, 233
 inferior 303
 left/right 217
 left 219
 right 219
 superior 303
radial 335
renal 331
 left/right 315, 329
 superior branch 315
saphenous, great/small 337
of septum pellucidum 287
splenic 307, 311
subclavian 327, 333
thalamostriate, superior 285, 287
thyroid, inferior 327
tibial, anterior/posterior 337
of Trolard 285, 287
ulnar 335
of the vermis, inferior 293
vena cava
 inferior 211, 213, 217, 219
 arteriography 301
 venography 328–331, 337
 superior 211, 233, 301, 333
 venography 326–327
venography 326–337
axilla 332–333
forearm 334–335
leg, lower 336–337
vena cava
 inferior
 anterior-posterior 328–329
 lateral 330–331
 superior, anterior-posterior 326–327
 venous angle 327
venous confluence 211, 233
ventricle
 larynx 229, 243
 left 211, 213, 217, 219
 right 211, 213, 219, 301, 327
vermis, inferior vein of 293
vermis branch, cerebellar artery 289
vertebrae
 articular facet, inferior/superior 47
 articular pillar 47
 articular processes
 cervical
 inferior/superior 49
 overlapping 45
lumbar, inferior/superior 55, 57, 59
sacral
 inferior 75, 237
 superior 75
thoracic, inferior/superior 51, 53
body of
 cervical, C2 49
 lumbar 55, 59
 thoracic 51, 53
cervical
 anterior arch 49
 C1 45
 lateral mass 45
 C2, body 49
 C7 43, 231
 odontoid process 47, 49
 pedicle 45, 49
 spinous process 47, 49
 transverse process 45, 47, 49
 uncinate process 45
end plate
 inferior 47, 53
 lumbar 55, 57
 superior 47, 53
 lumbar 55, 57
interarticular part 59
lamina 237
lumbar
 L1 43
 L3, pedicle 43
 L5 75, 237
 body of 73
 inferior articular process 75
 lateral view 77
 pedicle 73
 transverse process 73
 L6, spinous process 43
 pedicle 43, 55, 59
margin
 anterior inferior 47, 53
 anterior superior 47, 53
 posterior inferior 53
 posterior superior 53
odontoid process, cervical spine 47, 49
pedicle
 cervical 45, 49
 contralateral 49
 lumbar 43, 55, 59, 73

- sacral 237
 - thoracic 51
 - spinous processes 45, 75, 237
 - cervical 47, 49
 - bifid 45
 - lumbar 43, 55, 57, 59
 - thoracic 51, 53
 - thoracic
 - T2 43
 - T4 214
 - T5 214
 - T12 43
 - transverse process 45, 75, 79, 83, 237
 - cervical 45, 47, 49
 - lumbar 55, 57, 59
 - contralateral 59
 - ipsilateral 59
 - thoracic, T1 45, 51, 53
 - uncinate process, cervical 45
 - vertebral arch 45
 - vertebral arteries 289, 291, 297, 299
 - arteriography
 - anterior-posterior
 - arterial phase 288–289
 - venous phase 292–293
 - lateral
 - arterial phase 290–291
 - venous phase 294–295
 - vertebral end plates, inferior/superior 51
 - vestibular fold 229
 - vestibule
 - auditory 31, 35
 - of larynx 229, 231
 - vocal chord
 - false 229
 - true 229
 - vocal fold 229
- W**
- Wilberg's center-to-corner angle 63
 - wrist
 - anterior-posterior 125, 128–129, 132–133
 - arthrography 268–271
 - lateral view 127, 134–135
 - meniscus 269, 271
 - oblique view 130–131
 - recesses
 - extensor 269, 271
 - flexor 269, 271
 - sacciform 269
 - ulnar 269, 271
 - triangular fibrocartilage 269
- X**
- xiphoid process 85, 87
- Z**
- zygomatic arch 3, 13, 15, 26–27, 31
 - zygomatic bone 5, 9, 11, 29, 37
 - frontal process 13
 - zygomatic process 5
 - temporal bone 27, 33
 - zygomatic recess, maxillary sinus 27